This is a digital copy of a book that was preserved for generations on library shelves before it was carefully scanned by Google as part of a project to make the world's books discoverable online.

It has survived long enough for the copyright to expire and the book to enter the public domain. A public domain book is one that was never subject to copyright or whose legal copyright term has expired. Whether a book is in the public domain may vary country to country. Public domain books are our gateways to the past, representing a wealth of history, culture and knowledge that's often difficult to discover.

Marks, notations and other marginalia present in the original volume will appear in this file - a reminder of this book's long journey from the publisher to a library and finally to you.

**Usage guidelines**

Google is proud to partner with libraries to digitize public domain materials and make them widely accessible. Public domain books belong to the public and we are merely their custodians. Nevertheless, this work is expensive, so in order to keep providing this resource, we have taken steps to prevent abuse by commercial parties, including placing technical restrictions on automated querying.

We also ask that you:

+ *Make non-commercial use of the files* We designed Google Book Search for use by individuals, and we request that you use these files for personal, non-commercial purposes.
+ *Refrain from automated querying* Do not send automated queries of any sort to Google's system: If you are conducting research on machine translation, optical character recognition or other areas where access to a large amount of text is helpful, please contact us. We encourage the use of public domain materials for these purposes and may be able to help.
+ *Maintain attribution* The Google "watermark" you see on each file is essential for informing people about this project and helping them find additional materials through Google Book Search. Please do not remove it.
+ *Keep it legal* Whatever your use, remember that you are responsible for ensuring that what you are doing is legal. Do not assume that just because we believe a book is in the public domain for users in the United States, that the work is also in the public domain for users in other countries. Whether a book is still in copyright varies from country to country, and we can't offer guidance on whether any specific use of any specific book is allowed. Please do not assume that a book's appearance in Google Book Search means it can be used in any manner anywhere in the world. Copyright infringement liability can be quite severe.

**About Google Book Search**

Google's mission is to organize the world's information and to make it universally accessible and useful. Google Book Search helps readers discover the world's books while helping authors and publishers reach new audiences. You can search through the full text of this book on the web at `http://books.google.com/`

A 3 9015 00386 215 1
University of Michigan – BUHR

General Library

—OF—

UNIVERSITY OF MICHIGAN.

PRESENTED BY

Society

Oct 20 1897

~~6.3.1.4~~
6616
C53
P3

# TRANSACTIONS

OF THE

# CHICAGO PATHOLOGICAL SOCIETY

FROM

DECEMBER, 1895,

TO APRIL, 1897.

---

VOLUME II.

---

CHICAGO:
AMERICAN MEDICAL ASSOCIATION PRESS.
1897.

# PREFACE.

THE first volume of Transactions issued by the Chicago Pathological Society was published a little more than a year ago. Its reception, as shown by the criticisms of reviewers and in private letters to the Secretary, may be said to have been favorable beyond deserts. While it has been found impossible to make certain very urgent improvements in the arrangement of this, the second volume, yet it is hoped that the contents will indicate that the work of the society is progressing favorably. The next volume of Transactions will appear after a longer interval, in uniform type, and other improvements in its make-up.

PUBLICATION COMMITTEE.

General Library

OF

UNIVERSITY OF MICHIGAN.

PRESENTED BY

Society

Oct 20 1897

# NAMES OF MEMBERS.

Angear, J. J. M., 483 Lake St.
Angell, Katharine L., 3745 Indiana Ave.
Anker, I. Chas., 609 W. Congress St.
Auld, J. M., 714 W. Monroe St.
Babcock, Robt. H., 103 State St.
Bacon, Chas. S., 426 Centre St.
Bartlett, R. H., 14 Loomis St.
Baum, W. L., 103 State St.
Bausman, A. B., 580 W. Madison St.
Beach, Samuel C., McCook, Neb.
Benson, John A., 594 Washington Boul.
Bevan, Arthur D., 100 State St.
Billings, Frank, 100 State St.
Borland, L. C., 685 Ogden Ave.
Bouchard, W. L., 567 W. Madison St.
Bouffleur, A. I., 1178 Washington Boul.
Bridge, Norman, Los Angeles, Cal.
Brockway, Vira A., 52 Campbell Park.
Brophy, T. W., 126 State St.
Brower, D. R., 597 Jackson Boul.
Brown, I. W., 75 De Kalb St.
Brown, Langer, 757 Washingt'n Boul.
Bryan, C. J., 1079 Washington Boul.
Burgess, A. J., 1102 Grand Ave., Milwaukee, Wis.
Burroughs, W. M., 885 W. North Ave.
Burwash, Henry J., 721 N. Hoyne Ave.
Bush, Bertha, Rogers Park, Ill.
Butler, Geo. F., 794 W. Adams St.
Chandler, Ralph, 135 Grand Ave., Milwaukee, Wis.
Chapman, C. F., 594 Washington Boul.
Christopher, W. S., 408 Centre St.
Clarke, Wm. E., River Forest, Ill.
Clausen, Jas. J., 1063 Milwaukee Ave.
Cleveland, Geo. H., 951 Harrison St.
Colburn, J. E., 34 Washington St.
Coleman, W. F., 34 Washington St.
Cooke, Jean M., 1609 Diversey Boul.
Copeland, W. L., 866 W. Monroe St.
Corwin, A. M., 691 W. Harrison St.
Cotton, A. C., 677 Jackson Boul.
Coulter, J. W., 103 State St.
Dal, John W, 499 N. Robey St.
Danforth, I. N., 758 W. Adams St.
Davis, Thos. A., 987 Jackson Boul.
Dewey, F. J., 302 S. Oakley Ave.
Dickerman, Edw. T., 103 State St.
Dodson, John M., 568 Washington Boul.
Earle, Frank B., 903 W. Monroe St.
Eckley, W. T., 385 Washington Boul.
Edwards, A. R., 2818 Indiana Ave.
Eisendrath, Daniel N., 3035 Indiana Ave.
Etheridge, Jas. H., 31 Washington St.
Evans, W. A., 103 State St.
Favill, H. B., 138 Pine St.
Ferguson, H. M., 40th St. and Cottage Grove Ave.
Fisher, John, 277 La Salle Ave.
Fitch, C. M., 645 W. Monroe St.
Fitch, W. M., 645 W. Monroe St.
Foster, A. H., 779 W. Monroe St.
Friend, E., 70 State St.
Friend, S., 141 Wis. St., Milwaukee, Wis.
Froelich, Hans, 1426 Montana St.
Fütterer, Gustav, 716 Fullerton Ave.
Gavin, E. F., Waukegan, Ill.
Gehrmann, A., 103 State St.
Gentles, H. W., 210 E. 51st St.
Gill, Jas. C., 833 Warren Ave.
Graham, D. W., 672 W. Monroe St.
Grinker, J., 952 Milwaukee Ave.
Grim, U. J., 247 W. Madison St.
Gunn, Janet, 70 State St.
Hall, R. N., 339 Warren Ave.

Halstead, A. E., 804 Warren Ave.
Hamill, Edwin, 823 S. Western Ave.
Hamilton, J. B., 61 Market St.
Hammon, G. M., 683 W. Adams St.
Hansen, Z. P., 304 Washington Boul.
Harlan, A., Masonic Temple.
Harris, M. L., 100 State St., No. 612.
Hartman, F. S., 506 Congress St.
Haven, Jos., 57 Gordon Terrace, Buena Park.
Hawley, C. W., 70 State St.
Hayford, Ernest L., 848 Jackson Boul.
Hektoen, Ludvig, Rush Med. Coll.
Helvie, Chas. A., 3977 Cottage Grove Ave.
Henkel, F. W. E., 538 Ashland Boul.
Henrotin, Fernand, 358 La Salle Ave.
Herb, Isabella C., 225 Dearborn Ave.
Herrick, Jas. B., 751 Warren Ave.
Herzog, Maximilian, 350 Centre St.
Hessert, Wm., 25 Roslyn Pl.
Hoadley, A. E , 683 Washington Boul.
Hodges, F. J., Anderson, Ind.
Hollinger, J., 100 State St.
Holmes, E. L., 81 Washington St.
Hook, E. I., 1522 N. Rockwell St.
Ingals, E. F., 84 Washington St.
Jay, Frank W., 2510 Indiana Ave.
Johnson, Frank S., 2521 Prairie Ave.
Keith, Katharyn E., Adams and Paulina Sts.
King, Herbert M., 86 Jefferson Ave., Grand Rapids, Mich.
Klebs, Edwin, 52 Walton Pl.
Kerr, N., 239 N. State St.
Latham, V. A., Rogers Park, Ill.
Leach, W. D., 1105 W. North Ave.
Leahy, M. M., 6801 Wentworth Ave.
Leahy, Sarah J. M., 6801 Wentworth Ave.
Lee, E. W., 84 Washington St.
Lee, Edward H., 5 Blue Island Ave., New Era Bldg.
Le Count, E. R., 1418 W. Madison St.
Lewis, C. J., 783 Carroll Ave.
Lewis, H. F., 4426 Lake Ave.
Linnell, B. M., N. Halsted and Clybourn Ave.
Loomis, E. B., 145 S. Robey St.
Luken, M. H., 587 W. North Ave.
Lumley, R., 1074 N. California Ave.
Lyman, Henry M., 200 Ashland Boul.
McArthur, L. L., 100 State St.
McCollum, J. L., 626 W. Lake St.
McCullough, J. R., 87 Park Ave.
McIntyre, C. J., 884 Grand Ave.
Mergler, Marie J., 84 Washington St.
Meyer, Adolf, Worcester, Mass. (Pathologist Worcester Lunatic Hospital.)
Mitchell, L. J., 71 Laflin St.
Montgomery, Frank W., 100 State St.
Moorhead, E. L., 422 Ashland Boul.
Moras, E. R., 171 Blue Island Ave.
Morris, John L., 103 State St.
Moyer, Harold N., 103 State St.
Mueller, G., 1068 Milwaukee Ave.
Murphy, J. B , 34 Washington St.
Newman, H. P., 103 State St.
Newton, G. W., 878 W. Adams St.
Noel, E. P., 577 W. Congress St.
Noel, Jos. R., 358 Ogden Ave.
O'Byrne, C. C., 747 W. Monroe St.
Ochsner, A. J., 710 Sedgwick St.
Olney, T. A., 1413 W. Madison St.
O'Neill, J. W., 1421 N. Clark St.
Parker, Chas. A., 894 W. Lake St.
Patrick, Hugh T., 34 Washington St.
Patton, J. A., 2088 Gladys Ave.
Patton, J. M., 237 S. Hoyne Ave.
Pettyjohn, Elmore, Alma, Mich.
Pinckard, C. P., 103 State St.
Preble, R. B., 1907 Deming Ct.
Prendergast, Jos., Lake St. and Kedzie Ave.
Pfeifer, Jno. P., 1214 Milwaukee Ave.
Price, O. J., 538 W. Adams St.
Pritzker, L. J., 239 W. Division St.
Pusey, W. A., 103 State St.
Regent, M. N., 564 S. Halsted St.
Rhodes, J. Edwin, 84 Washington St.
Richards, Annette S., 821 Warren Ave.
Ries, E., 100 State St.
Robinson, W. F., 100 State St.
Robison, Jno. A., 297 Ashland Boul.
Root, Eliza H., 489 W. Monroe St.
Ross, J. W., 925 Warren Ave.
Ryan, L., 1285 W. Van Buren St.
Salisbury, J. H., 982 W. Adams St.

Sandberg, Karl F., 622 N. Hoyne Ave.
Schaeffer, F. C., 582 Washington Bd.
Scott, T. A., Algon, Iowa.
Schroeder, Wm. E., 4323 Prairie Ave.
Senn, Emanuel J., 532 Dearborn Ave.
Seville, Fred F., 1620 W. Madison St.
Sippy, B. W., 143 Oakwood Boul.
Shaw, D. Lee, 707 Jackson Boul.
Skeer, J. D., 681 Washington Boul.
Skelton, L. L., 42 Seeley Ave.
Slaymaker, S. R., 1418 W. Madison St.
Somers, G. H., 505 W. Adams St.
Steele, D. A. K., 103 State St.
Stehman, H. B., Presbyterian Hospital.
Strong, A. B., 533 W. Monroe St.
Tebbetts, J. H., Hollister, Cal.
Test, Mrs. Dr. A., Dundee, Ill.
Thomas, H. M., 31 Washington St.
Thometz, Jno. L., 999 W. 12th St.
Treat, R. B., 247 W. Madison St.
Turck, F. B., 555 Dearborn Ave.
Twining, S. D., 210 Grand Ave.
Van Hook, Weller, 4043 Grand Boul.
Van Hoosen, Bertha, 489 42d St.
Waite, Lucy, 98 Laflin St.
Walls, Frank X., 108 State St.
Waugh, Wm. L., 1102 Masonic Temple.
Weaver, Geo. H., 535 Washington Boul.
Weber, Samuel L., 100 State St.
Wells, Franklin C., 359 Warren Ave.
Wescott, C. D., 31 Washington St.
West, S. G., 401 Warren Ave.
Wilder, Wm. H., 100 State St.
Williams, Jno. C., 169 Webster Ave.
Wing, Elbert, 55 33d St.
Woley, H. P., 3311 Cottage Grove Ave.
Worthington, H. C., Oak Park, Ill.

## Regular Monthly Meeting, Dec. 9, 1895.

Dr. Weller Van Hook, President, in the Chair.

Dr. J. B. Murphy read a paper entitled:

# FIBROMYOMA COMPLICATING PREGNANCY; FIBROMA OF VAGINAL WALL.

### FIBROMYOMA COMPLICATING PREGNANCY.

Nettie S., age 39, colored, married, admitted to the Cook County Hospital Oct. 19, 1895; family history negative; was married two years ago, no children, no miscarriages nor abortions; has always enjoyed excellent health with the exception of the present trouble. Menstruated at about 14, was regular, fairly profuse, lasting about four days; no clots, never hemorrhage. Present illness began in July, 1895, with a cessation of menstruation. It has not reappeared since. Has not had sexual intercourse for three or four months. After the suppression of the menses, noticed a tumor just below the umbilicus. This has rapidly increased in size since that time. It has not been accompanied with pain. There has been no backache; the greatest discomfort has been produced by pressure of the tumor against the edge of the ribs. No urinary symptoms; there has been no discharge.

Physical examination: Patient well nourished; large physique, considerable adipose, abdomen very markedly distended and irregular in contour. Nodular growth can be felt in the abdomen, extending above the umbilicus, and especially to the right side, where it presses against the margin of the ribs. One of the nodules below the umbilicus is about the size of a child's head, of hard consistence and fairly movable. The whole mass can be moved laterally about two and one-half inches, but not up or down. In the median line, from two inches below the umbilicus to the symphysis, fluctuation can be felt. It is apparently deep-seated, and surrounded by an irregular margin. No fetal heart-sounds nor placental souffle can be heard. Vaginal examination reveals a large hard mass, entirely filling the pelvis. The os can be felt above the symphysis. By pressing the tumor up, the sound can be introduced into the uterus two and one-half inches, but not farther, it being extremely difficult to get the os in position for the introduction of the sound. The tumor in the pelvis is very firm, smooth on surface, and of very hard consistence.

Diagnosis: Uterine fibroid, with cystic degeneration. The

rapidity of growth and the absence of the history of hemorrhage somewhat oppose the diagnosis of fibroid, but this was explained subsequent to the operation.

Celiotomy: Oct. 25, 1895. Tumor found to be free from adhesions. On lifting it out of the abdomen, through a very long incision, and turning it to elevate the large nodule out of the pelvis, the left broad ligament ruptured close to its attachment to the tumor. There was profuse hemorrhage for a few seconds. The ligament was clamped with a long pedicle forceps, broad ligaments ligated and excised. The uterus was situated on the anterior surface of the pelvic portion of the tumor, and was about six and one-half inches in length. An elastic ligature was placed upon the stump, allowing the cervix to remain, so as to treat the pedicle externally. Two large pedicle forceps were placed above the ligature; uterus amputated. There was no blood in the pelvis. The parietal peritoneum was sewed to the cervix, all the way around, just below the elastic ligature. The abdominal wound was closed down to the pedicle, packed around with iodoform gauze and dressed antiseptically.

Time for operation, thirty-two minutes. The mass weighed six pounds six ounces; it consisted of a large irregular fibroid, growing from the posterior wall of the uterus. The uterus was enlarged about six inches and contained a sac of fluid. When opened, a fetus of about three months was found in the sac, which had not been ruptured. The question of pregnancy had been thoroughly considered before operation, and thought impossible from the patient's statements and the absence of physical signs.

The impregnation accounted for the great rapidity of the growth, it being borne in mind that the patient had never noticed the tumor until July.

The patient made an uninterrupted convalescence; she did not vomit from the anesthetic, and at no time did her temperature reach 100 degrees. The highest pulse rate was 96, and that was immediately after the operation. There was no secretion from the stump, which remained perfectly dry for fifteen days, when a slight serous exudate appeared at its base—the line of separation. The pedicle sloughed on the twenty-seventh day after the operation; patient is now sitting up in bed. This completes a series of ten consecutive abdominal hysterectomies with ventral fixation of the pedicle, for large fibroids, not previously reported, all of which recovered.

That pregnancy should complicate uterine fibroma, is not surprising, as Gusserow, in quoting Bayle's statistics, states that twenty of every 100 women over 35 years of age have fibromata of greater or lesser size; and Klob states that 40 per cent. of all women over 50 years of age have fibromata.

That pregnancy does not appear more commonly with fibroma, is accounted for, 1, the fibroma itself tends to sterility, as it produces a pathologic condition of the endometrium, except in the sub-peritoneal variety; 2, that the fibroma does not attain a con-

FIGURE 1.

siderable size in the majority of cases, until after the child-bearing period is past; and 3, that the fibroma in the great majority of cases does not produce any disturbance during the period of gestation, and in many cases does not complicate labor. If it has attained a marked size before impregnation, its development is greatly enhanced by the pregnancy. The variety of fibroma in which the muscular element predominates over the fibrous, increases most rapidly under the stimulus of pregnancy. The tissue becomes edematous and doughy, as may be noted in the pos-

terior wall of the uterus and the portion of the tumor attached to it, in the specimen presented.

The uterine fibroid of large size rarely admits of the completion of the period of gestation. It usually terminates in abortion, hemorrhage, impaction in the pelvis, labor pains, placenta previa, rupture of the uterus, death of fetus or sepsis. That the presence of fibroma with pregnancy may not deserve surgical attention, was well established by Theodore Landau (Volkmann's *Sammlung klinische Vorträge*, No. 26, Neue folge). He expressed himself in the following words:

"A myoma which rests in or on an impregnated uterus, does not of itself, demand the attention of the surgeon. Only when the tumor produces unpleasant symptoms is active interference indicated. The principal of these unpleasant symptoms are mechanical or pressure symptoms, as incarceration of the uterus in the pelvis, galloping increase in size of growth, nephritis, uremia, ascites, etc., as well as the reflex manifestations of pressure, cardiac, respiratory and gastric. When these disturbances are sufficiently severe to demand the physician's attention, the question arises—What shall be the procedure? Will it be an enucleation of the fibroma, an induced abortion, an abdominal hysterectomy, or an abdominal extirpation of the fetus, without the removal of the uterus and appendages? The selection of operation will depend on whether the immediate emptying of the uterus is necessary, and if so, whether it is possible for the fetus to pass from the uterus, through the cervix and vagina; or, whether it is desirable to have the tumor itself removed, at the same time that the patient is freed from the fetus. When the pelvic passage is blocked, the only question to be considered is laparotomy."

This statement was made three years ago. The improvements in technique and statistics of abdominal hysterectomy have poduced an entire change in the conditions which guide us in our selection of pro-

cedure. It is questionable whether induced abortion in the presence of a large fibroid is not as serious a procedure to-day as an abdominal hysterectomy in the hands of an expert operator. It is certain that if the tumor itself demands removal, it is better that the tumor, uterus and fetus in situ should be removed at once, without attempting a previous abortion. The recognized dangers in parturition of a myomatous uterus are atony, hemorrhage, peritonitis, gangrene of the tumor, rupture of the uterus and

FIGURE 2.

retention of the placenta. These dangers are all present with abortion, some in a lesser and some in a greater degree than in labor at full term. The dangers of sepsis and hemorrhage are very much greater in induced abortion, while the dangers of rupture and gangrene of the tumor are less. Gusserow reports a death from intraperitoneal hemorrhage in induced abortion, from rupture of the veins around the tumor.

The statistics for simple myomectomy, without removal of the uterus collected by Landau, represent

eighteen cases at different periods of gestation, ranging from twelve weeks to seven months, and in the hands of fourteen different operators, show four deaths and seven miscarriages. It was first performed by Péan, Dec. 15, 1874. It can be seen that the mortality for this operation is 22 per cent. and for abortion about 40 per cent. (Würkert[1] collected twenty-seven cases with seven deaths), not encouraging from either standpoint, notwithstanding the beautiful results produced by Schroeder, Landau, Frommel (four cases and one death), and others. The same author collected eighteen cases of supervaginal amputation of an impregnated myomatous uterus at different periods of gestation, ranging from two to eight months, by different operators, with seven deaths, a mortality of about 39 per cent. (first performed by Kaltenbach, March 21, 1880). The operations of enucleation and amputation, from these statistics, are to be considered very grave undertakings, both for the life of the fetus and the life of the patient. Still, these statistics were collected before 1890, and the operation of abdominal hysterectomy in that period had a much greater mortality than now. It is to be hoped, therefore, that the statistics of the future, as well as of the past two years, will show a great improvement in the results of the amputation of the gravid myomatous uterus, over the period preceding 1890. Landau concludes: "Hysterectomy should be the operation of selection, in submucous, intramural and multiple fibroid, enucleation coming in question only where the tumor is pedunculated or of small size, and subserous."

The difficulties of operating on the impregnated uterus, contrary to belief, are less than in the non-impregnated, and Hoffmeyer says whoever has seen an operation on the gravid uterus must admit that this statement is true. The vessels are larger, the uterine body is lifted up out of the pelvis and the ligaments are more easily reached in the impregnated

[1] Centralblatt für Gynecologie, No. 45. Page 1056, 1893.

than in the non-impregnated uterus. The danger following the operation, the same author says, should be less, if care be taken to remove all of the placenta and membranes.

For operation, fibromata are conveniently divided into 1, impacted pelvic myomata. These are the most favorable for operation and they usually originate from the cervix uteri and can be enucleated through the vaginal wall, without opening the peritoneal cavity. This procedure, says Chrobak, should always be followed, except where the tumor is larger than a child's head. 2, Extra- or retro-vaginal impacted fibroids. These may originate in the cervix, or in the lower portion of the corpus uteri, and are usually in the process of the enlargement of the uterus, lifted out of the pelvis into the abdomen (Spiegelberg), and are removed by laparotomy. This may occur, even though they be retro-vaginal primarily, and originate from the cervix. 3, Abdominal fibroids. The latter usually originate from the body of the uterus, and are removed by celiotomy.

When should the operation be performed? In the process of enlargement, the uterus lifts itself out of the pelvis; the fibroid may remain in the pelvis or accompany the uterus. The symptoms of impaction, as a rule, are transitory, as the uterus accommodates itself to its surroundings. If, however, these symptoms persist, they must be relieved, either by lifting the uterus and tumor out of the pelvis, or by enucleating the tumor. The rule laid down by Schroeder is that the operation should be postponed as late as possible. He says the prognosis of hysterectomy is more favorable, particularly of retro-cervical myoma, the later in pregnancy it is performed, and most favorable, if performed at the end of gestation, because at this period we jeopardize the mother less, and favor the preservation of the child. When the period of gestation is complete and abdominal section is indicated, we must then decide whether it shall be Cæsarean section, Porro or hysteromyomectomy. The

statistics of the Cæsarean section with fibroma show the results to be extremely discouraging; the majority of the cases terminated fatally, even with Sänger's method. The Porro, without the removal of the tumor, can be accomplished in only a small number of cases and should not be attempted. Hysteromyomectomy is the most desirable as well as the most favorable, both to the mother and the child. The question of treatment of the pedicle, whether it be extra or intra-peritoneal, or a total extirpation, must be decided by the individual operator, as each can obtain better results with the method with which he is most familiar. True, the extra-peritoneal variety tends to longer convalescence, but it has the advantage of leaving the peritoneum practically without an abrasion.[2] Gusserow collects in all 228 cases; the mother died in 123, a mortality of about 54 per cent., and 67 children, a mortality of 30 per cent. This includes the operations performed in the pre-antiseptic period, and a few in the antiseptic period, but does not include any cases of the aseptic era. Chrobak in 1893 successfully treated a case of this kind, in which he performed the total extirpation on the three-month impregnated uterus with internal treatment of the stump. From Schroeder's standpoint, the most desirable time to operate is at the completion of the period of gestation, and the most favorable operation a hysteromyomectomy.

In the case here presented, the indication was for immediate hysteromyomectomy, as it was not possible to even sound the uterus from the vagina, and delivery through the vaginal route could not be thought of. The tumor was producing pressure symptoms, and pregnancy had only existed for three months. The broad ligaments were quite well elevated above the brim of the pelvis; the laceration produced in the left was caused by the great distance to which the uterus had to be elevated before the tumor, which was situ-

[2] This can also be accomplished by the total extirpation, with only a line of suture in the peritoneum in the floor of the pelvis.

ated deep in the pelvis, could be turned out. The application of the ligature and clamps was less difficult than in the average abdominal hysterectomy where pregnancy was not present. The statistics collected by Gusserow are certainly not encouraging for allowing the pregnancy to continue to the full period of gestation. It would seem that the operation

FIGURE 3.

at the seventh month should give more favorable results to the mother and scarcely less to the child, as the mortality to the latter is already 30 per cent. The cases reported by Dr. Thad. A. Reamy, of Cincinnati; Dr. Wm. J. Taylor, of Philadelphia; Dr. Henry B. Stehman, of this city; Dr. Chrobak, of Vienna, and the case here reported, are illustrations of the results

that may be obtained in early hysteromyomectomy where the tumor is complicated by pregnancy.

### FIBROMA OF VAGINAL WALL.

In the year 1882 there appeared from Keinwächter, an article on "Vaginal Myoma and Fibroma" (published in the *Zeitschrift für Heilkunde*, Band iii, S. 335, Praag), in which he collected fifty-three cases. It is the largest collection that I have been able to find. Breisky, in the year 1886, added five to this number (Die Krankheiten der Vagina, *Deutsche Chirurgie*, Lief. 60, S. 163), which included the cases of von Hermann, two from Gaye, one from Casewell, and one of his own. In addition to these, I find one from Hasenbalg (*Zeit. für Geb. und Gyn.*, Band 23, Heft 1, p. 52), and one from Archibald Donald (*Med. Chron.*, January, 1889, p. 103). The one reported by E. Hasenbalg was polypoid in shape. Of the total number, twenty-nine were in the anterior, twelve in the posterior, five in the side; others not given. The tumor may reach a considerable size. Oliver and Jacob's cases weighed a kilogram. In two old cases reported by Baudier and Gremler, the tumors weighed ten pounds. They are more frequently sessile than pedunculated. The development of the tumor is extremely slow. It may be observed at all ages. Martin reports a case in a child at birth. Tractzl found one in a child 15 months old. It produced obstruction of the urethra and rectum. They are most commonly detected at middle age, and are often found in old people, where they have existed for many years. The symptoms produced by them are merely mechanical, *i. e.*, pressure upon the bladder, urethra, rectum and surrounding tissues. One case was reported that was accompanied by uterine hemorrhage. The diagnosis is not difficult to make, the greatest care being necessary to differentiate it from cysts in the vaginal wall close to the urethra, and fibroma of the cervix uteri. It presents a smooth, hard surface and can be distinctly separated from the uterus in the majority of cases. When

located in the anterior vaginal wall, it usually begins at the urethra, close to the sphincter, and spreads laterally between the mucous membrane, as in the following case, viz:

S. B. was admitted to the Mercy Hospital Oct. 17, 1895.

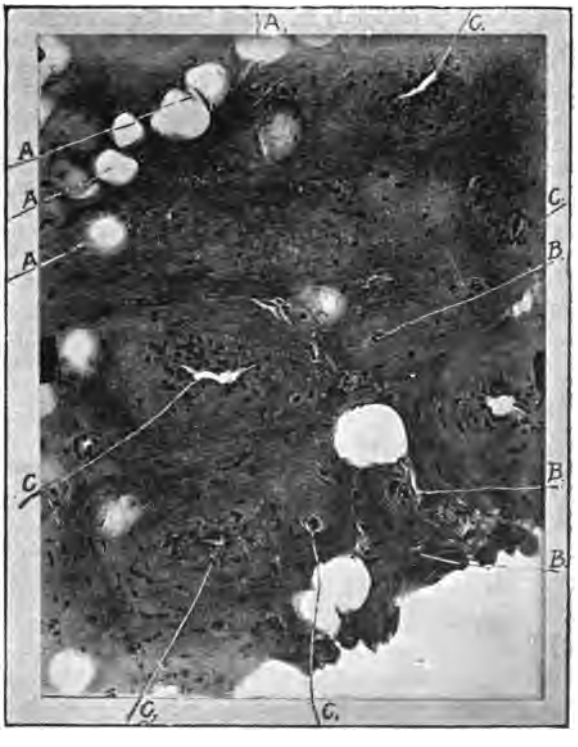


FIGURE 4.

Family history negative. About four years ago, patient noticed that a tumor projected from vagina. It grew with moderate rapidity, and when about the size of an apple, it ulcerated on the surface and gave a very offensive discharge. The tumor up to this time had not caused any unpleasant symptoms, with the exception of a heavy, dragging sensation in the pelvis. She

was operated on at that time (two years ago) and the protruding portion removed. About six months ago, she discovered that a prominence still remained in the anterior wall of the vagina. There was no pain nor discomfort. It has gradually increased in size; there were no urinary symptoms.

Examination: The smallest portion of the tumor is apparently attached to the wall of the urethra, in the median line. It extends from that point to the left, out to the margin of the pelvis. It can be distinctly separated from the uterus, to which it is not attached. The largest portion presses upon the left side of the pelvis, in front. Rectal examination shows that the tumor is about an inch from the cervix uteri, and hugs the left pelvic wall closely.

Diagnosis: Fibroma of vaginal wall.

Operation: An incision was made in the anterior vaginal wall, beginning at the urethra, and extending to the left an inch and a half. The surface of the tumor was exposed, and it was readily enucleated with the finger from the submucous vaginal tissue. Cavity packed with iodoform gauze. Uninterrupted convalescence. The tumor measurements are, 9½ c. long, and 5 c. in diameter; the thick end being 4 inches and the smallest 2½ inches. It weighs 57 grams.

Microscopic examination: Myxofibroma of the vagina. The tumor is a typical fibroma, the seat of fatty and mucoid infiltration. The sites of fat masses are shown at *A*. The mucoid infiltration is not even. This material did not stain with iodin, nor with methylen violet. With eosin it stained somewhat more deeply than the other tissues though not markedly so; it was soluble in water. The conclusion was that it was mucus. The number of vessels in the tumor had been very large. Two factors, endarteritis and infiltration obliterated many of them, and greatly diminished the caliber of others. Some entirely obliterated are seen at *B*. Others partially excluded at *C*.

### PRESENTATION OF SPECIMENS AND DISCUSSIONS.

Dr. H. B. Stehman presented a *Fibroma*. The patient from whom I removed this fibroma was 35 years of age, married, and had never been pregnant before. While she had been aware of the existence of the tumor, previous to within two months she had experienced no discomfort from its presence, and it is doubtful whether she would have sought medical advice except for the fact that her condition was rather to her discredit. Her family physician was somewhat in doubt as to the pregnancy, but the suppression of menstruation, morning sickness, changes in the mammary glands and the appearance of the cervix, added to the rapid growth of the tumor with the attendant

pelvic discomfort, left no doubt in the matter. She was told that her choice lay between a miscarriage or hysterectomy, and taking into consideration the size of the tumor, was informed that the risk of the latter was no greater than the former, and probably a little less. At her request the tumor was removed, amputating at the cervix and bringing the stump, previously attached to the peritoneum, into the lower angle of the wound. The operation was done in August, 1893; the convalescence was uneventful, the patient returning home at the end of five weeks. This growth had developed from the fundus of the uterus in such a manner as to completely hide it from view, but the sketch shows the lobes of tumor separated

Pregnant uterus with contents, and fibromata.

with the uterus incised antero-posteriorly upon its anterior surface, exhibiting the fetus in utero.

Dr. W. T. Eckley presented: 1. *Anencephalic monster*, removed post-mortem from an ectopic pregnancy of eight months. The fetus presented the usual appearances of this variety of monster. At the autopsy the inferior mesenteric artery of the mother was of unusual size. 2. *Craniorhachischisis*. The fetus had but six dorsal vertebræ. There were two thumbs on one of the hands.

Dr. A. J. Ochsner presented a *fetus*, showing the effects of an extensive amnionitis. The specimen which I show you is interesting in that it shows in various parts the effects of ab-

normal pressure upon the fetus. The lower extremities show the effects of this pressure the least. The hand and arm on the left side show the effects of pressure to quite a marked extent. As you see, the hand is clubbed, and there is probably an absence of the lower end of the radius as a result of pressure. Upon the right side the arm is entirely missing. The colon and the liver project from the unclosed abdominal cavity, from which a portion has been removed also by pressure. There is no arm upon the left side, it having been amputated probably in the same manner. The nose and forehead are deformed. I do not know what to call this deformity; there is a band extending upward from the mouth elevating the upper lip. The left eye is almost entirely closed, and there is a considerable amount of fibrous tissue extending along the cicatricial band. As to the history of this case I will only give it to you briefly. The patient was a laboring woman, 40 years of age, who had formerly borne several children. She came to the hospital in labor, so to speak; that is, she had labor pains. An examination showed that the uterus was probably empty. A diagnosis of extra-uterine pregnancy at term was made and confirmed by various practitioners, among them Dr. John Bartlett. It was decided not to attempt to deliver the child by abdominal section, one reason being this, that notwithstanding we had made a diagnosis, we were not absolutely positive about it. Another reason was that the fetal heart sounds were not sufficiently strong to warrant the necessary danger to the mother. The probabilities of obtaining a living child by an abdominal section were not sufficiently strong to influence us to expose the mother to the danger that would be necessary to deliver the child at term by this method; consequently we waited for six weeks. The child died two days after the labor pains began; at least no further motion was felt, and the fetal heart could not be heard after this time. At the end of six weeks we removed the child by abdominal section. The placenta was left in place, the sac attached to the abdominal wall, and the cavity from which the child was removed was packed with gauze in the torm of a Mikulicz drain. In the meantime the amniotic fluid had decreased to a very marked extent. At the end of three weeks the placenta was removed, after which the wound healed by granulation, having remained aseptic

throughout. The patient returned to her home two months after the operation and carried about some sick children for two or three weeks, and as a consequence developed a ventral hernia, which gave us an opportunity to make an accurate diagnosis concerning the location of the fetus. During the

Monster. extra-uterine pregnancy. 1, amniotic band; 2, superior maxilla; 3, clubbed hand; 4, liver; 5, colon.

first operation we supposed the fetus was in the broad ligament, and that the placenta was attached in the direction of the uterus. However, in the secondary operation it was an easy matter to determine the location of the extra-uterine

pregnancy, because the ventral hernia had attached to it what was left of the sac which had contained the fetus. It consisted of the broad ligament which was spread out at one end. At the upper end to the right the ovary was located; consequently we then made a positive diagnosis that the fetus had lain in the broad ligament. I will say regarding the history of the mother that at about the third month she began to have repeated hemorrhages which continued for some eight weeks, confirming our diagnosis of extra-uterine pregnancy. Six weeks after the second operation the mother again become normally pregnant.

Dr. Joseph Haven presented *a kynocephalous monster.* I do not present this little monster for the purpose of opening the old controversy as to the possibility of maternal impressions being imparted to the fetus in utero, as it would lead to a great deal of discussion, but because this little freak of nature is interesting. I will briefly give the history of the case, and ask you to compare the two specimens before you. Some twelve or fourteen years ago I was in attendance upon a family in this city, one of whose members was a little girl 8 or 10 years old, extremely nervous and high strung, who possessed an uncontrolable fear of dogs. Anything in the canine race, even the picture of a dog, would distress her. Her mother explaining the matter to me said that while carrying the child in utero she had been frightened by a dog, and that the girl had inherited that fear. As the child grew older she did not outgrow that tendency. During an attack of typhoid fever, in her delirium she had frequent visions of dogs, so that it was often necessary to employ narcotics to quiet her. The child grew up and was married, shortly after which she became pregnant. About the sixth week of pregnancy I was sent for one afternoon in a hurry. I found Mrs. D. hysterically excited. I was told that in going out of the yard a neighbor's dog jumped upon her and terribly frightened her. She was put to bed, began to flow, and a miscarriage seemed imminent. But she was tided over. I saw her daily after that for some time. She assured me that her child would be marked like a dog. I tried to disabuse her mind of this idea. Time went on and about the third month the same dog jumped on her again and bit her in the foot, inflicting a slight lacerated wound. It was some time be-

fore I could go to the case and when I reached the house a miscarriage had just taken place. I took possession of the fetus, being careful that the mother should not see it. On account of the peculiarity of the specimen removed I secured

Monster, extra-uterine pregnancy. 1, amputation at shoulder; 2, liver; 3, colon.

the dog that had been the occasion of so much trouble, and to-night I show you the skull of the dog which I would like to have you compare with the little monster.[1] Those who believe in the transmission of maternal impressions will get some consolation from examining these specimens, and those who be-

lieve such results happen as mere coincidences will have to account for this freak as best they can.

Dr. Jos. B. De Lee (by invitation) presented a *hyyoplasic monster*. The specimen which I shall present to-night is a rather rare one. It belongs to that class of monsters that are described as hypoplasias, and the hypoplasia in this case occurred at an early stage of development. The fetus is well developed. You see only the upper half, but the lower half was perfectly normal. The technical name for the deformity which you see is cyclops, or synophthalmus, or another name for it is arrhinencephalus. The deformity is produced by an arrest in growth of the three anterior cerebral vesicles of the brain. The interior of this skull, if I had permission to dissect it, would show a large cyst which would represent the cerebrum, and at the base would be the cerebellum normally developed. Anteriorly there has been no distinction between the eye vesicles. They did not separate, and therefore form the eye in the median line. This monster shows a well developed single eye. Owing to non-development of the cerebral vesicles flexion was not complete, so the nose, or the representative of it, is this process which you see above the eye. It is a beautiful specimen in that it shows one single eye which is complete.

The other specimens which have been presented by the members were interesting in several respects, and they belong also to the class called hypoplasia. One of them was a hypoplasia, the result of pressure from amniotic bands. The extra-uterine pregnancy cases are particularly liable to present amnionitis. This amnionitis has been disputed by several authorities who claim that a normal amnion can, in the absence of the liquor amnii, at an early period become attached to part of the young fetus and thus interfere with its development. Abdominal hernia is sometimes ascribable to the same cause. The non-development of the forearm in this fetus presented by Dr. Ochsner is an interesting feature ascribable also to amniotic

[1] The general appearances are well shown in the photograph which is reproduced here. The peculiarities not brought out by the photograph are, the extreme breadth of the shoulders, the great chest development and the caudal appendage. The tail was originally three quarters of an inch in length, but has suffered from much handling. The sulcus around the neck was occasioned by the cord originally used to suspend the specimen in the jar.

bands. It is an anencephalus, and the specimen by Dr. Eckley was a similar one. The other was a specimen of craniorachischisis, a common deformity. None of the gentlemen have given us any points about the clinical history or course of monsters. Possibly that was because we have here no monsters that would cause obstruction in labor. A diagnosis of double monster before labor is impossible. No one has yet diagnosticated a double monster before labor, and the nearest any one has come to it was to diagnose twins. A diagnosis of single monster has been made several times. In a case like the one reported by Dr. Eckley, the absence of the brain could have

Kynocephalous monster with skull of dog.

been diagnosed from the abdominal findings. Another anomaly that occurs in single monsters that is probably more common is hydrocephalus. That could be diagnosed. The double monsters that cause trouble do so in three ways. First, those monsters that have a reduplication of the upper half of the body, with two faces attached to one body. These are called diprosopus, or double-faced monster. These monsters cause a disturbance in labor by the marked increase in the circumference of the part. The other form of monster of this class which will cause trouble in labor is the one in which there is an in-

crease in the lower half of the body, where there will be two individuals joined together below. This is called dipygus, and there may be three or four legs. Another form of monster for our study clinically is that in which there are two individuals adherent at the head or breech. One is called craniopagus and the other ischiopagus, or the pygopagus. Some three years ago there was an ischiopagus monster shown in the museum here in which two children, then 16 months old, were attached to each other by the buttocks. Such a case would cause little difficulty in labor, needing possibly a little traction. Thirdly, a most interesting monster is that like the Siamese twins, with two children joined together at the breast, or thoracopagus. Since this junction is very movable, anomalies can occur in which one fetus will be half delivered, and the other will apply itself transversely across the inlet. The case resembles one of interlocked twins and may cause the severest kinds of dystocia.

In the treatment of these three kinds of monsters the method to be pursued will be plain. In the first group, forceps or version and extraction, or if a dipygus extraction by all the feet that present. In the second group, traction on the body of the fetus delivered. In the third group, version of the second twin, then bring the first out, finally deliver the second by the breech. As a general rule breech presentations are more favorable in labor in monsters, and one should seek to turn, if the opportunity presents.

Dr. Gustav Fütterer discussed: *1. Metastasis of carcinoma from the labia majora.* "You know that generally carcinoma of the labia majora by metastasis make their appearance in the inguinal glands. In this case the carcinoma of the right labia was removed very early, and some time after that the patient died. I made a post-mortem examination and found a nodule in the myocardium. I examined the cells and found that they were like the cells of the upper layers of the skin containing eleidin. Perforation into the pericardial sac had taken place and from here an absorption of the cells by the stigmata of the pericardium was effected. You see the epithelial cells mostly in columns. Most of them at right angles to the surface of the pericardium, some parallel to it, all filling out the lymphatic spaces. Fresh specimens of these parts show

that the cells had retained their original character entirely. As far as I know, this is the only case of its kind that has been observed or reported. It may be there are more, but I do not know of any where such a metastasis has occurred from such a superficial carcinoma of the labia majora."

2. *Histogenesis of giant cells, illustrated in a carcinoma of the cervix uteri.*—"You wonder, doubtless, why I show you this because you see such cases so frequently. The reason why I do so is this, that there are large cells which contain comparatively large nuclei and I consider this important as an histologic fact. If you will look at the first specimen you will notice that there is extensive necrobiosis in most of the alveoli of the carcinoma. You will also notice (with low power) that in the necrobiotic parts there are large red spots, and as there has been employed an elective staining for nuclei, you must recognize that these spots are large nuclei. The second specimen, with the high power, shows that these red bodies are nuclei. What does that mean? The necrobiosis shows that there is a lack of nutrition. With lack of nutrition we have lack of water, and according to the experiments made and published by Prof. Jacques Loeb, of the Chicago University, in 1892, such a deficiency of water brings about, first a rigidity of the protoplasm—while the nuclei may multiply—and then, when increased, a rigidity of the nucleolar substances, which will prevent their division. In this case, I would say, there was a local drought, as it were, sufficient to cause a rigidity of the protoplasm, preventing its division, sufficient also, to prevent the division of the nucleoli, but not sufficient to prevent the increase in the bulk of the latter's substance. However that may be, our findings in the specimens which I show to you, and our observations on giant cells in tuberculosis confirm the results of Loeb's investigations and I believe that the latter will bring to us the long-sought-for clew as to the histogenesis of the giant cells. An excessive high or low temperature, or a lack of oxygen (vacuum), will cause the same rigidity of the protoplasm and nuclei successively and, in dealing with those matters, we must always remember, that protoplasm is also present in the nucleus. The latter fact explains the similarity of reaction of the nucleus, and the protoplasm, which only shows a qualitative difference between either."

DR. J. B. MURPHY read a paper on

INTESTINAL OBSTRUCTION FROM ENTEROLITH.

J. McC., aged 47; male; admitted to Cook County Hospital Dec. 1, 1895. Family history negative; used intoxicants and tobacco to excess. Had had gonorrhea three times. Denies syphilis. Suffered from typhoid fever when a boy. About twenty years ago was seized with sudden pain in the epigastrium. He described the pain as a cramp; says it lasted but a few hours; since that time has had many similar attacks, each resembling the present one. Present illness began five days ago. After a large bowel movement, was attacked with severe, steady, aching pain in the epigastrium. This compelled him to go to bed. The following evening he began to vomit a dark-colored material. After a few hours, the odor of the material ejected became offensive. It was impossible to produce a bowel movement. The severe pain, vomiting and inability to produce a bowel movement has continued up to the present time.

Physical examination: Patient well nourished; conjunctiva slightly jaundiced; tongue dry and heavily coated; breath very offensive; face has a pinched expression; knees drawn up. Abdomen distended; irregular elevations can be noticed in its surface; liver dullness normal. Peristalsis movement could be recognized through the abdominal wall. Auscultations revealed strong peristaltic action, most marked in the right epigastrium. No tenderness except to the left and a little above the umbilicus, where deep pressure produced pain. Pulse 90; temperature normal.

Diagnosis: Mechanic ileus without intestinal strangulation.

Celiotomy was performed Dec. 6, 1895, assisted by Drs. Beasley and Wood. Median incision. Small intestine very much distended, a coil secured and held by an assistant. Splenic flexure of colon located; found contracted and empty; advanced along the transverse colon until near the median line, where a nodule was felt in the small intestine. This nodule was drawn into the wound. The intestine about the nodule was about two inches in diameter, and below, five-eighths of an inch. It could readily be seen that the obstruction was produced by a large foreign body in the bowel. Parallel incision was made in the bowel, and the enterolith extracted. Opening closed with

Czerny-Lembert suture. Abdominal wound closed with silk wormgut suture. No drain. The enterolith weighed twenty-five grams. It measured 4.5 c. longest diameter, and 2.75 c. shortest diameter. Its circumference was 12 c. The center appeared to be composed of an old dry mass of plum-pudding, to which other material had become adherent. It would be interesting to know whether this had been the cause of pain for twenty years preceding the operation, and if it had been in the canal that length of time where it was lodged. We do know

Enterolith.

that large foreign bodies may remain in the bowel for months without producing manifestations of their presence. The differential diagnosis between strangulated ileus and obturation ileus in this case, was based on the fact that the man had suffered for five days from obstruction and still was not collapsed nor depressed, which he would have been, had the intestine been strangulated. The patient made an uninterrupted recovery.

## Regular Monthly Meeting, Jan. 13, 1896.

The President, Dr. Weller Van Hook in the Chair.

Dr. Emil Ries read a paper entitled

# ON MEMBRANES DISCHARGED FROM THE UTERUS.

The gynecologist often receives for examination membranes which, he is told, have been discharged from the uterus. Unfortunately he often receives them in a stage of decomposition which makes them hardly fit for microscopic examination. The cause of this may be that the membrane has been retained in the vagina for some time before it was discharged, or that after discharge it has not been preserved with sufficient care. If the membranes are kept in water or in weak solutions of alcohol the decomposition may go so far that the epithelium is thrown off from the surface and from the glands, and the cells of the interstitial tissue stain very badly or not at all. Let me draw your attention to the importance of the careful preservation of such membranes in concentrated alcohol or in a 20 per cent. solution of formol. The shrinking which may be caused by the alcohol is far less injurious as regards microscopic examination than the decomposition.

The first question which we have to consider when we examine such membranes, is whether they are really discharged from the uterine cavity or not. This question is easily answered in the affirmative, if the membranes form a faithful cast of the uterine cavity.

(Figs. 1, 4, 7, 10). The best preserved specimens are three-cornered sacks with a cavity inside. But very often we receive nothing but shreds.

Macroscopic examination can sometimes show directly that the membrane did not come from the cavity of the uterus. Thus we often see shreds of

Fig. 1.



Membranous Dysmenorrhea.

various sizes discharged after vaginal treatment with strong solutions of ichthyol or acetate of lead in glycerin or with tincture of iodin and other astringents. These shreds are discharged without pain and are often found covering tampons which had been applied satu-

rated with one of the solutions just mentioned. These shreds are whitish or brown, the color depending on the remedy previously applied; they are always very thin, as is easily understood after microscopic examination has shown that they consist of the superficial epithelial layers of the mucous membrane which covers the vagina and the vaginal portion. The cells are large, flat, polygonal; they lie closely together without interstitial tissue; they contain a nucleus, which stains readily, and a very clear protoplasm. If seen from the surface a mistake about the nature of these cells is almost impossible, but if sections have been made in a transvere direction the flat cells may appear like spindle-cells and thus a wrong idea as to the nature of these cells may originate in the inexperienced. The microscopic aspect described above, especially the observation that the cells lie closely together and that their protoplasm does not stain must prevent such errors. It needs no further evidence to prove that these membranes are without importance. A few days' rest from treatment and the vaginal mucous membrane will be repaired.

Membranes of quite a different size and of very grave importance are sometimes discharged in cases of puerperal inflammation of the uterus. They are sometimes so bulky that it would be a misapplication of the term were we to call them membranes. They generally have a very disagreeable smell; are soft, sloughing masses and on microscopic examination prove to be parts of the muscular wall of the uterus, containing muscle cells in great quantities. The observation of such shreds establishes the diagnosis of metritis dissecans, a condition in which inflamma-

tion of the uterus produces necrosis of the muscular tissue, parts of which slough away and are discharged in shreds of various size.

Excluding the two kinds of membranes just described, membranes can be discharged from the uterus under the following conditions: 1, dysmenorrhea membranacea; 2, pregnancy in a normal uterus; 3, extra-uterine pregnancy; 4, pregnancy in one horn

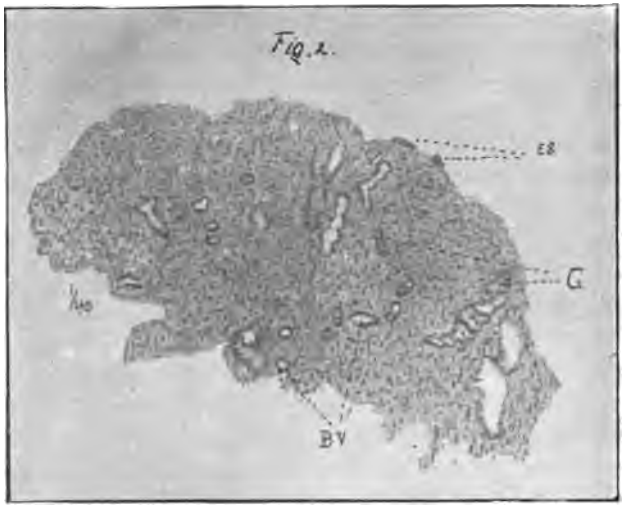


ES, epithelium on surface; G, glands; BV, blood vessels.

of a double uterus, which can be *a*, fully developed, *b*, rudimentary.

The great difference in the pathologic importance of the conditions just mentioned renders a full investigation of the membranes discharged in such cases very useful and sometimes indispensable for an exact diagnosis. For instance the membranes of mem-

branous dysmenorrhea and extra-uterine pregnancy may so much resemble one another macroscopically, that they can not be distinguished without microscopic examination, and the same holds good in certain cases of differential diagnosis between intra-uterine and extra-uterine pregnancy. I shall present a full description of the various membranes and shall then compare them with each other, so as to show the more clearly their similitudes and dissimilitudes.

In menstruation sometimes membranes or clot-like masses are discharged which may be of three-cornered shape representing faithful casts of the uterine cavity. (Fig. 1.) Sometimes only small, soft shreds of such membranes are passed. The most important clinical symptom which accompanies the discharge of these masses is severe colic-like pain, which often stops after the membranes are expelled. The blod-clots discharged are solid bodies, they do not contain a central cavity, their surface is smooth. The shreds of membranes are sometimes very small and often escape unobserved, if the woman pays no special attention to her menstrual flow. If three-cornered membranous sacks are discharged they present a shaggy surface, the corners present irregular openings with ragged borders leading into a central cavity. If the sack is cut open its interior surface is seen to be crossed with shallow furrows and perforated with a great number of minute openings which correspond to the mouths of the uterine glands. On microscopic examination the blood-clots are seen to be largely composed of red blood corpuscles more or less changed in form, between them are white blood corpuscles and the whole clot is held together by a mesh-work of threads of

fibrin radiating around and through masses of blood-corpuscles. Of the epithelium of the surface of the uterine mucous membrane or of the glands or of interstitial tissue there is nothing to be found on or in the

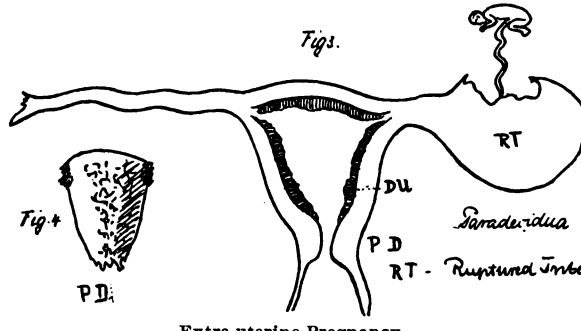


Extra-uterine Pregnancy.

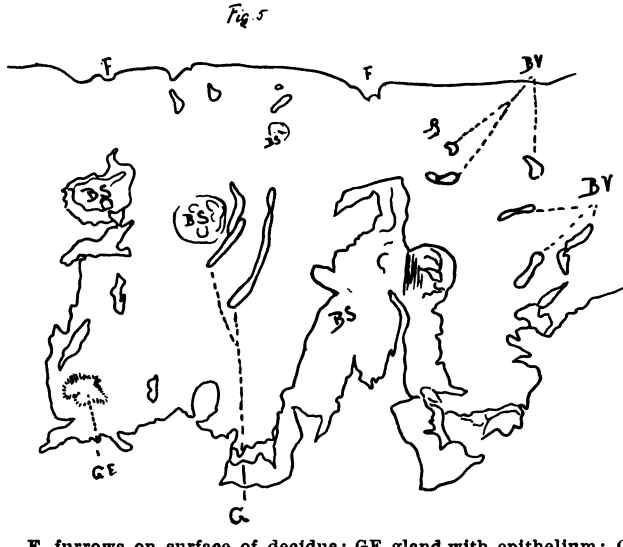


F, furrows on surface of decidua; GE, gland with epithelium; G, gland without epithelium; BV, blood vessels; BS, blood sinus.

clot. The membranes which are sometimes found in the menstrual discharge are composed of the superficial layers of the mucous membrane of the uterus. (Fig. 2.) They contain therefore uterine glands, interstitial tissue, superficial epithelium and blood vessels. The epithelium of the surface is often lost on account of bad preservation of the specimen, but if found it presents a normal aspect. The glands are often hypertrophied as is recognized by their tortuous course. The interstitial tissue contains the normal cells of the areolar tissue of the uterine mucosa and is not changed into decidua.

This latter fact, the absence of a decidua in cases of membranous dysmenorrhea is worth dwelling upon a little longer. Some authors have called the membranes discharged in this disease "decidua menstrualis" and this has led to errors, as some have been induced by this name to believe that these membranes are of similar construction as the real decidua. It is necessary expressly to state that these membranes have nothing whatever to do with pregnancy and that they are not composed of decidual cells. It is therefore better to avoid the name of "decidua menstrualis" altogether.

The connective tissue in these membranes is not changed into decidua cells, it has the same aspect as in the normal or endometritic uterine mucosa. It may contain round-cell infiltrations, or the cells may be pushed asunder by edema or hemorrhage. The blood vessels of these membranes are generally empty or contain only the shadows of red blood corpuscles. The vessels are generally of capillary size, so that arteries and veins can not be distinguished. One

side of the membranes, the side which had been in connection with the uterine wall is always most irregular in outline, causing the shaggy appearance on macroscopic examination. Here the tissue is generally infiltrated with blood, which sometimes is found adherent to the outer surface in small clots.

The discharge of parts of the mucous membrane of the uterus is a decidedly rare and abnormal occurrence. I mention this specially because Dr. Johnstone has recently tried to reëstablish the old and

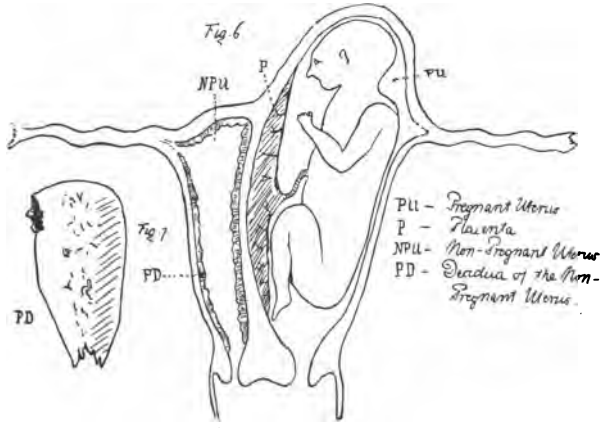


Pregnancy in one Horn of a Double Uterus.

abandoned theory that in normal menstruation the superficial strata of the uterine mucous membrane are shed. The most reliable investigations of Gebhard, of Berlin, and other microscopists have on the contrary proved beyond doubt that in normal menstruation as a rule no tissue is destroyed and that shedding of some strata of the mucous membrane is always abnormal. Specimens taken from corpses can never disprove this and specimens of the uterine mucous

membrane removed from the normal living uterus during menstruation invariably prove that nothing is destroyed or shed. The tissue is infiltrated with hemorrhages which break through the superficial epithelium and may occasionally tear off a few epithelial cells in bursting through them. But the mucous membrane as an organ is not thrown off in normal menstruation.

We have now to consider the membranes which are produced in, and sometimes expelled from the uterus in connection with pregnancy, whether this pregnancy occurs inside the uterus or outside.

If the fetus is inside the uterus the mucous membrane of the uterus produces the decidua vera, serotina and reflexa. The serotina represents part of the placenta and is therefore partly removed in connection with the placenta. The reflexa may be retained, if parts of the fetal membranes are retained and may be discharged with them. The vera may be discharged to a greater or smaller extent along with fetal membranes or it can be discharged alone. These membranes are never casts of the whole uterine cavity, but are always shreds of various size and very irregular form. If parts of the decidua are discharged along with parts of the fetal membranes, we find under the microscope the chorion with more or less atrophic chorionic villi easily recognized by the star or spindle-shaped cells of the embryonic connective tissue, of which the chorion consists. (Fig. 13). The epithelium of these atrophied chorionic villi is always lost. The chorion reposes on a layer of decidua cells, which surround the atrophied villi of the chorion. The cells of the decidua reflexa generally are indis-

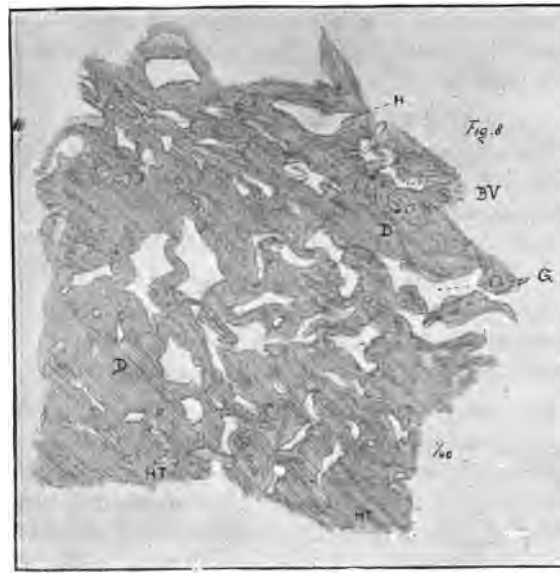


H, hemorrhage; HT, hemorrhagic tissue; G, glands; D, decidua; BV, blood vessels.

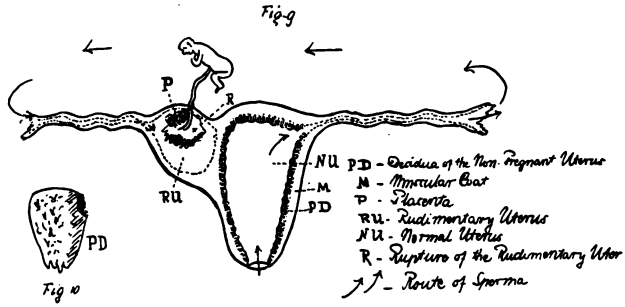


Pregnancy in the Rudimentary Horn of a Double Uterus.

tinct, the whole tissue staining diffusely. This is always seen if the case is not one of very early pregnancy. In the later stages the reflexa undergoes hyaline degeneration and the whole membrane has a homogeneous aspect. If parts of the vera are discharged along with the reflexa they look very much like the latter; often they are infiltrated with numerous round cells.

If we get such shreds for examination and find parts of the chorion in them, we can give a positive diagnosis of pregnancy inside the uterus. If we find only decidual tissue we can only give a diagnosis of pregnancy, but are not enabled summarily to decide that this pregnancy is inside or outside the uterus.

A decidua can develop itself in a uterus which does not contain a fetus under the following conditions: 1, tubal pregnancy (Fig. 3); 2, pregnancy in one horn of a double uterus; *a*, both horns being fully developed (Fig. 6); *b*, one horn being rudimentary (Fig. 9).

There are some other varieties of abnormal location of a fetus which I shall not further describe here, as the formation of the decidua in these cases is the same as under the conditions just mentioned.

If the fetus is in the tube the uterine mucous membrane undergoes the same change as if the fetus were in the uterus itself, while the tubal mucous membrane forms the decidua vera of the fetus. I call the uterine decidua in such cases a "para-decidua" to avoid mistakes. Such a para-decidua is also invariably developed in the empty horn, if the uterus is double and one horn is pregnant. I have had the good fortune to observe the comparatively large num-

ber of four such cases while I was assistant to the gynecologic clinic of the University of Strassburg. In three of these cases both uteri were well developed and the labor was to all appearances the same as in a normal simple uterus. The fourth case was a case of double uterus, one horn of which was rudimentary;

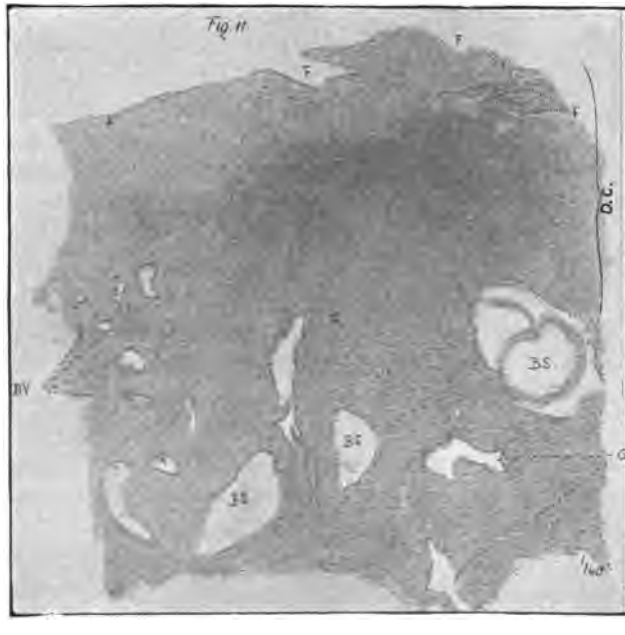


**BV, blood vessels; F, furrow of surface; G, glands; BS, blood sinus; DC, decidua compacta.**

only the body of the rudimentary uterus was developed and there existed no communication between the two uteri (Fig. 9). The rudimentary uterus contained the fetus, which had grown in it until the fifth month, when the uterus ruptured and the fetus was born into

the abdominal cavity. The rudimentary horn was removed and the patient recovered. This description suffices perfectly for the establishment of this case as one of impregnation by external migration.

In all of these four cases a para-decidua was discharged from the empty uterus; in three cases, among them the case with the rudimentary horn, parts of the para-decidua were passed on the day of the confinement, the rest a few days later; in the fourth case the para-decidua was passed three or four days after the confinement as a complete cast of the uterine cavity. In cases of tubal pregnancy the para-decidua is generally discharged soon after the death of the embryo; there are, however, exceptions to this rule. The para-decidua of tubal pregnancy is passed either in shreds or as a complete sac.

If we compare complete specimens of para-deciduas passed in tubal pregnancy and in pregnancy in one of a double uterus, we observe a marked difference in the macroscopic appearance. The para-decidua of a tubal pregnancy is a three-corned sack with openings at the three corners corresponding to the two tubal and the cervical orifices of the uterus (Fig. 4). The para-decidua passed from the non-pregnant horn of a double uterus has only two corners and openings with shaggy borders, while the third corner is rounded and presents no opening (Figs. 7 and 10). The cause thereof is that such a uterus contains the orifice of only one tube; the corner opposite the orifice of the tube is round and the decidua can be separated here without any interruption of its continuity (Figs. 6 and 9).

These para-deciduas present a shaggy outward sur-

face, while the surface looking toward the cavity of the uterus shows a network of more or less shallow furrows, which surround islands of smooth tissue, which is dotted with very minute openings corresponding to the orifices of the uterine glands. The size and thickness of these membranes vary very much. Each individual membrane has thinner parts corresponding to the fundus and the lateral borders of the uterus. The para-

Fig. 12.

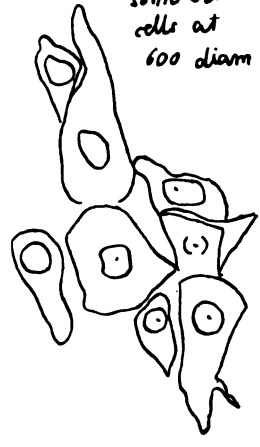


deciduas of tubal pregnancy vary in thickness up to three millimeters, the para-deciduas in cases of double uterus are between four and seven millimeters thick, the size of the latter is usually twice or three times the size of the para-deciduas of tubal pregnancy.

The microscopic examination of these membranes shows them to be largely composed of fully developed decidual cells with large clear bodies and a comparatively small vesicle-like nucleus (Fig. 12). The

size of these decidual cells varies according to the progress which the pregnancy has made in the same way as in the decidua vera of a normal pregnancy. The decidua cells lie closely together, leaving only narrow spaces between them, in which sometimes round cells are impacted. In tubal pregnancy the expelled para-decidua contains mainly the compact layer; the spongious or glandular layer remains in the uterus. Some authors, among them Abel in his recently published work on "Microscopic Technique in Gynecology," assert that these membranes never contain glands, if they are not removed artificially. But I possess specimens of para-decidua cast off by the uterus itself, in which there are quite distinct glands with well-preserved epithelium (Fig. 5). In cases of pregnancy in one horn of a double uterus, both the compact and the glandular layers are expelled; in one of my specimens the glandular layer is remarkably well developed (Fig. 8). The epithelium of these glands is usually much flattened out, so that it is sometimes very difficult to distinguish it from the endothelial layer of vessels. The blood which is often contained in these spaces does not enable us to make a differential diagnosis between blood-vessels and glands, as some spaces which are lined with distinct epithelium and are thereby characterized as glands, also contain blood.

The epithelium of the surface is seen occasionally in para-deciduas of tubal pregnancy as described by Abel; in one of my specimens of para-decidua from a double uterus it is very well preserved and is in direct continuity with the epithelium of the glands.

The blood-vessels are dilated in all para-deciduas and

choked full with blood-corpuscles. The endothelial cells of the vessels generally present the same swollen appearance as in normal pregnancy. Besides these blood-vessels are seen many comparatively large spaces filled with blood-corpuscles and fibrin; they form the so-called blood-sinuses and are generally found near the inner surface of the membranes (Fig. 5). The surface which had been in connection with the uterus generally presents some large blood-

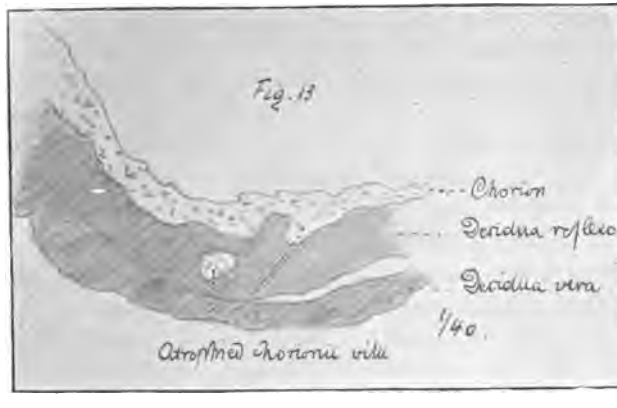


sinuses and the whole tissue on this side of the membranes is infiltrated with blood-corpuscles.

The normal interstitial tissue of the uterine membrane is often preserved in the deep layers of the para-deciduas, generally much infiltrated with round cells.

The mechanical process by which the membranes here described become detached from the uterus is not definitely settled. But if I consider the regular occurrence of hemorrhagic infiltration along the line

of separation of these membranes, para-deciduas, deciduas and membranes of membranous dysmenorrhea, I can not help conceiving the idea that these hemorrhages have something to do with the detachment of these membranes. I can not deny that they may be a consequence as well as the cause of the separation and that this theory needs much further evidence before it is firmly established.

After having reviewed these different membranes it will be well to point out the main symptoms by which we are enabled to make a differential diagnosis between them. The history of the case generally gives some valuable indications as to the nature of the membranes passed, especially so in cases of membranous dysmenorrhea, where a history of more or less regularly repeated discharge of membranes is highly significant. By microscopic examination two kinds of membranes can be diagnosed without any difficulty, the membranes consisting of vaginal epithelium and the blood-clots. For the rest of the membranes the main question to be answered is whether there is pregnancy or not. If we find chorionic villi the diagnosis of intra-uterine pregnancy can be given with absolute certainty. If we find the membranes composed of parts of the uterine mucosa with well-preserved glands and epithelium without any decidual cells, the diagnosis of dysmenorrhea membranacea may be safely pronounced. The main difficulty arises, if we find decidua cells in the membranes. Some authors assume that decidua cells are no proof of the existence of a pregnancy, because decidua cells have occasionally been observed in cases of simple endometritis. But it seems to me that there

exists a wide difference between the occurrence of a few decidua cells in an otherwise normal interstitial tissue and the composition of a whole membrane by decidua cells. One swallow makes no summer and one decidua cell makes no decidua. But if we observe that a membrane passed from the uterus is totally or largely composed of decidual cells, if we find the whole specimen like those above described as decidual or para-decidual membranes, I believe we need not apprehend a mistake if we give a diagnosis of pregnancy. To decide whether this pregnancy is intra- or extra-uterine it is of the greatest help to have the whole membrane for examination. Their size, the thickness, the number of the openings at the corners of the sacks give most important clews.

Finally, the aspect of all the membranes above described can be much changed by degeneration or hemorrhages and round-cell infiltration, so that eventually an exact diagnosis is impossible. In making a diagnosis from the descriptions above given it must always be borne in mind that absence of a symptom is of very inferior value to positive observation.

DISCUSSION.

Dr. M. L. Harris—I was in hopes that some of the expert gynecologists present would have something to say on this paper. Anything which will help us in making a diagnosis of extra-uterine pregnancy is of great importance, because as we know, this condition is extremely difficult to diagnose. The practical importance of this paper to me can be summed up in one point, namely, the diagnostic value of the decidual membrane in extra-uterine pregnancy. It is universally acknowledged now that a decidua invariably forms in the uterus in extra-uterine pregnancy. Is such a membrane ever shed from the uterus where the individual is not pregnant? It would hardly seem necessary to raise such a question had not such an

authority as Olshausen recently denied the possibility of such an event in this way. He says: "While I am not able to state positively that it is impossible for such a membrane to be shed during menstruation, still I do not believe it ever occurs, and that when it does it is an indication of extra-uterine pregnancy and simply shows how very common this condition is." This statement, however, can not stand. There is no doubt but that such a membrane may be shed during menstruation. Cases have been reported by Franqué, for instance, where there was a periodic discharge of a membrane during menstruation from the age of 8 years up. Are we able to differentiate such a membrane shed during extra-uterine pregnancy from one thrown off during menstruation? This point does not seem so clear. We may take the points which have been given as diagnostic of the menstrual membrane, preservation of the epithelial cells, multiple hemorrhages, fibrin layers, serous infiltration, separation of the cells by round cells; but none of these points is diagnostic of a menstrual membrane. All of them may occur in a true decidual membrane. Again, a point which has been relied upon to differentiate the decidual membrane is this, that the connective cells, so-called decidual cells are always much larger than are found in menstrual membranes. The size of the decidual cells is no criterion by which we may diagnose the true decidua. Franqué made a large number of accurate measurements of the connective tissue cells in menstrual and decidual membranes, and concluded that we were not able to differentiate one membrane from the other simply by the size of the cells. Again, the growth of the decidual membrane is a very gradual process, the rapidity of its growth is variable, and the length of time which pregnancy is supposed to exist does not always produce a decidual membrane of the same degree of advancement. For instance, the decidual membrane will grow more rapidly or slowly, according to the distance of the fetus from the uterus, as was shown some time ago by Wyder. When the decidual membrane is fully formed and shed, so that we have a membrane made up wholly of decidual cells without glandular tissue we can be very sure of the diagnosis. When we have the membrane in the intermediate stage we are unable to differentiate a decidual from a menstrual membrane. Such is

the opinion of Franqué after a thorough investigation. He stated that the microscope alone would not enable us to differentiate these membranes in all cases. We must have a decidua which is quite complete in its formation, otherwise we can not say it is a decidual membrane, because the menstrual membrane may contain all of the points which go to make up the decidual membrane, even an increased proliferation of connective tissue, and correspond very closely to a decidual membrane in its early formation. The same opinion is likewise held by Hofmeier, Ruge, Meyer, Löhlein and Fritsch from their own individual investigations. However, the value of the membrane when it can be differentiated in the diagnosis of extra-uterine pregnancy is considerable. I think that is the most important point which we can make from this paper, and it is an extremely valuable one.

As to the hemorrhages into the membrane and the cause of separation I had an opportunity to examine a membrane from a typical case of membranous dysmenorrhea some time ago, and I was greatly impressed with the hemorrhages into the deep layer. There was no doubt that this was a case of menstrual membrane from the history, and I was fortunate in securing the membrane soon after it had been discharged. It contained the ordinary uterine glands, the epithelium being preserved except where it had been lost from handling. In the deep layer were multiple hemorrhages, and so much infiltration of the membrane with blood that one could hardly fail to be impressed with the possibility of these hemorrhages being instrumental in causing its separation; still Löhlein concluded that the hemorrhages were not the cause of separation of the membrane, at least not the main cause. Other factors, with which we are not familiar, he considered to be the chief cause of the separation.

Dr. Emil Ries (closing the discussion)—I agree with Dr. Harris perfectly in some points. For instance, the difficulty of making a diagnosis in early extra-uterine pregnancy is undoubtedly very great. I have myself had a specimen of shreds of membrane where I could not make a diagnosis, though I had numerous specimens of membranous dysmenorrhea and of extra-uterine pregnancy to compare them with. It was a case of uterine hemorrhage after menstruation had occurred one

week too late, so that from a clinical standpoint a diagnosis of extra-uterine pregnancy had been made, though there were no distinct symptoms of this condition. There was no collapse; a tumor could not be distinctly felt. In this case the woman discharged with her irregular hemorrhages a few small shreds, and I examined them. I found cells resembling decidual cells, but the whole membrane was so much infiltrated with round cells that I could not get a clear view of the structure of this membrane, and from the microscopic appearance of the membrane I could not give a positive diagnosis. On the other hand, a microscopic diagnosis can be made very valuable where the clinical diagnosis is obscure. I remember a case where a woman had not menstruated for three months and then had hemorrhages. An examination revealed the uterus to be slightly enlarged, and to the right side of it was a distinct tumor which could be distinctly traced to the tube, so that the doctor had made a diagnosis of extra-uterine pregnancy, considering the hemorrhages the consequence of the rupture or of the death of the fetus. I got a little three-cornered sack from this uterus for examination, the macroscopic appearance of which resembled that of a para-decidua, but when I examined it under the microscope I found chorionic villi. This case could not be one of extra-uterine pregnancy, inasmuch as the fetus had been aborted and the irregular hemorrhages were the consequence of retained decidua and chorionic villi. The microscopic diagnosis may be of great value in such cases.

Considering the value of the decidual cells in the diagnosis of pregnancy, I know that there has been a very severe controversy between several German gynecologists, which has lasted for many years, but has been abandoned because nothing new has been advanced about it. What seems to be the most important fact is that, without any doubt, in cases of simple endometritis cells can be found in the mucous membrane of the uterus which resemble decidual cells in size and which have the large nuclei of the decidual cells, the bodies of these cells not staining well, the nucleus staining very well. But as I said in my paper, there is a vast difference between a few cells resembling decidual cells and a membrane entirely composed of decidual cells. Dr. Harris mentioned the size of the decidual cells. I do not think it is safe to rely upon their size.

That there are intermediate stages between the connective tissue cell and the decidual cell is undoubtedly true. The decidual cell is nothing but a connective tissue cell which has grown. We observe sometimes intermediate stages where the cell is so small that it does not look like an ordinary decidual cell, or it may be so large that it does not look like a normal cell of interstitial tissue. These are the cases where the diagnosis is difficult. Of course in cases of membranous dysmenorrhea it is not only the question of hemorrhages and edema and normal interstitial tissue cells, but one very important symptom is the presence of normal or slightly hypertrophied glands. In cases of extra-uterine pregnancy, or pregnancy in a double uterus, the glands disappear very soon; the epithelium becomes flattened out, whereas in membranous dysmenorrhea as a rule the glands and epithelium are well preserved, so that they can be readily recognized. The diagnostic importance of microscopic examination in these cases is inferior to that of such an examination in cases where the question is one of malignant or benignant neoplasm. But as I believe, it has been shown that in most cases the microscopic examination is of great diagnostic value.

Dr. L. Hektoen presented gross specimens of the brain and the spinal cord hardened in various ways, such as alcohol, formalin and Müller's fluid. He had found, however, that a mixture of ninety-five parts of Müller's fluid and five parts of commercial formalin was an extremely useful combination for the preparation of gross brain specimens, the tissue becoming rapidly firm and elastic, not brittle as in Müller fluid alone, and the markings of the cut surface remaining very distinct. The hardening process is very rapid in this mixture; in three to four weeks, or even less, a brain will be in very favorable condition for division into transverse sections; the fluid should be changed as often as it becomes turbid or altered in its original color. The specimens can be permanently preserved in alcohol which will wash away the excess of Müller's fluid.

As shown by the microscopic specimens presented, human and animal spinal cords prepared in this mixture can be stained with Weigert's method as early as after one week. The specimens that have remained two weeks or so show perhaps a deeper staining. The exact behavior of brain tissue prepared

in this mixture has not yet been accurately determined.

The Müller's fluid and formalin mixture is also an excellent fixative and hardening agent for ordinary tissues that are to be examined histologically. It acts very much more rapidly than Müller's fluid and the blood is especially well preserved.

A mixture of Müller's fluid ninety-five parts and formalin five parts is consequently warmly recommended foı the preparation of gross wet brain and cord specimens on account of rapidity of action, on account of the firmness and elasticity of the specimen, and the definite outline of the cut surface. It is also recommended in those instances where it is desirable to obtain specimens of spinal cord suitable for Weigert's differential stain within a shorter time than is possible when Müller's fluid is used alone. Finally the addition of formalin to Müller's fluid will be found to hasten, intensify and improve the action of the latter in these cases in which Müller's fluid is ordinarily used for histologic purposes.

PRESENTATION OF SPECIMENS AND DISCUSSIONS.

Dr. F. Henrotin presented a specimen of

EXTRA-UTERINE PREGNANCY,

apparently due to rupture through the fundus of the uterus at an early time. The specimen had been removed by laparotomy which disclosed the fetus attached to the lower part of descending colon producing obstruction. The fundus of the uterus showed a large, irregular tear, through which the fetus and part of the placenta seemed to have passed. The tubes and ovaries were normal.

Dr. D. D. Bishop presented the following specimens:

TUBERCULOUS PERICARDITIS.

This specimen is an example of chronic adhesive tuberculous pericarditis obtained through the courtesy of Dr. L. J. Mitchell. The patient was a negro, aged 23. The heart and adherent pericardium weighed 650 grams. The adjacent peribronchial lymph glands were converted into large caseous masses, but careful examination of the other organs and tissues revealed no other tuberculous foci. The two surfaces of the pericardium are adherent; along the line of union numerous areas of caseation are seen, and upon the surface are many small nodules. There is some infiltration into the myocardium, especially near the base

of the heart. Microscopic examination shows caseation, round cell infiltration with epithelioid cells, but giant cells were not found. A limited number of tubercle bacilli were also found. The specimen is of considerable interest because of the fact that tuberculosis was not present in any other organs except in the peribronchial lymph glands. Tuberculous pericarditis of the chronic variety has been described, and all of the authors agree that it is an uncommon condition, unless associated with general tuberculosis or pulmonary phthisis. It occurs now and then in association with tuberculosis of the peribronchial lymph glands, or tuberculous abscess in the anterior mediastinum, or perhaps tuberculosis of the sternum or some of the adjacent ribs. If tuberculous pericarditis exists as a primary condition without extension from adjacent structures, it must be very rare indeed.

### FIBROMYOMA OF THE STOMACH.

The second specimen I wish to call attention to is presented because of its rarity. It is a small fibromyoma discovered in the wall of the stomach. The patient was a negro and advanced in years. The tumor apparently springs from the muscular coat proper. As we examine it macroscopically it seems to be covered by mucous membrane. It was firm, and whitish bands were seen passing through it, which suggested a fibroid tumor of some sort. In the fresh condition it measured one inch in length and a half inch in breadth, projecting a half inch above the level of the serous membrane and one-sixteenth of an inch above the level of the mucous membrane. The outline was oval and the margins fairly abrupt and circumscribed. There was no necrosis upon the surface.

Sections of the tumor show the structure to be one of more or less connective tissue fibers and cells having broad staff-like nuclei, which we recognize as muscle cells, entitling the tumor to the name of fibromyoma.

### ADENOCARCINOMA OF THE COLON.

In this bottle is a small tumor about the size of a hickory nut, which projects into the interior of the intestine and is pedunculated. It appears papillomatous upon its surface, but when cut it is quite firm. It was situated about the middle portion of the descending colon some little distance above the sigmoid flexure, and was found in a patient 84 years of age.

Microscopic sections of the tumor show it to be composed largely of well developed tubular glands lined with columnar epithelium and fairly well formed fibrous framework. In places the tubular glands are quite atypical, the structure not being complete in some parts, and in others the outline of the gland being irregular, suggesting to us the appearance we often see in columnar-celled carcinoma of the intestinal tract.

Dr. E. R. Le Count presented and discussed the following:

PANCREATITIS WITH DISSEMINATED FAT NECROSIS.

The first ones are specimens from a case of so-called fat necrosis which occurred in the practice of Dr. W. C. Williams. Dr. Williams has already reported the case to the Chicago Medical Society, and shown the specimens there. They are deemed of sufficient rarity to warrant a second presentation. The specimens were sent to the laboratory of Rush Medical College by Dr. A. D. Bevan, who saw the case in consultation. The clinical history was briefly as follows: A woman, age 40, had been suffering from apparent slight indigestion for a week or ten days, previous to Sept. 2, 1895. On that date, following a light lunch, she experienced violent abdominal pain, followed by vomiting of a brownish bile-containing fluid. Vomiting at frequent intervals, severe frontal headache, and paroxysmal pain continued during the night and following morning. Severe pain was experienced on attempting to sit up. Examination on the second day revealed weak pulse, slightly subnormal temperature, and as regards the abdominal region, no localized swelling, no ascites, no abnormal dullness, but deep-seated tenderness. Death, preceded by a slowly developing weak heart action, which failed to respond to stimulation of any kind, and by coma and cyanosis, took place on the third day. At the autopsy the changes found were limited to the abdominal cavity and consisted mainly in the presence in the subperitoneal fat of multiple, small (.5 to 1 or 2 c. in dia.), grayish, granular, slightly raised areas, with more or less serrated margins and irregular circular outlines. The peritoneum over such areas was lessened in luster, but was not the seat of any fibrinous exudate. These areas were distributed throughout the whole abdominal cavity wherever subperitoneal fat existed; in the omentum, mesentery, pancreatic and para-pancreatic fat, etc. Slight hemorrhage into the post-pancreatic tissues

and posterior portions of the pancreas was found. The mucous membrane of the small intestines was a diffuse red color and slightly swollen. The kidneys were soft and opaque. The epi- and peri-cardium appeared normal; the myo-cardium flabby; other organs normal.

Bacteriologic examination: The colon bacillus was isolated from the heart muscle, kidneys, pancreas, and the gray areas in the mesentery.

Histologic examination: The examination of fresh sections, sections hardened in alcohol and Müller's fluid and fixed in Flemming's solution, all showed the opaque areas in the subperitoneal fat to be made up of an amorphous, granular, non-staining substance in which were many needle-shaped crystals radiating from a common center. The osmic acid reagent did not discolor these areas as it did the surrounding fat. No fat cells were found in the opaque areas, nor were they surrounded by any zone of cell infiltration. The pancreas showed some areas of infiltration with blood, an increase of interacinous connective tissue, a marked absence of nuclear staining reactions, and a round cell infiltration only in the head near the duodenum. Marked round cell infiltration of the mucous membrane of the duodenum was present and, to a less extent, in other parts of the small intestines. The epthelial lining of the kidney tubules was swollen and the cells granular.

The résumé of the present knowledge concerning disseminated fat necrosis by Thayer (*Am. Jour. of the Med. Sciences*, October, 1895) and an editorial in the JOURNAL OF THE AMERICAN MEDICAL ASSOCIATION, Nov. 2, 1895, on the same subject, are of such recent date as to render any allusion to literature superfluous. It suffices to say that the opinion of Langerhaus, that the opaque areas were produced by a combination of fatty acids, freed by a fat-splitting ferment of the pancreatic secretion, with lime salts, was confirmed by Barker of the Pathologic Laboratory of the Johns Hopkins Hospital, who resolved the crystals found in such areas back to fat globules by the use of glacial acetic acid, and demonstrated the presence of lime salts in the areas with oxalic acid.

COLLOID CARCINOMA OF STOMACH WITH EXTENSIVE PERITONEAL INVASION.

The second case from which it is desired to show specimens

occurred as a coroner's case. The autopsy was done by Dr. L. J. Mitchell, who sent the specimens to the laboratory of Rush Medical College for examination, and to whose courtesy I am obliged for the privilege of presenting them.

The clinical history is unknown. The anatomic diagnosis made at the autopsy is as follows: Colloid carcinoma of cardiac end of stomach, of omentum, of peritoneum, with serohemorrhagic effusion and multiple free carcinomatous colloid masses in the peritoneal cavity. Adhesive pericarditis, hypertrophy of heart, fusiform aneurysm of ascending aortic arch, with rupture and hemorrhage into pericardial adhesions, cyanotic atrophy of liver, chronic nephritis, left inguinal hernial sac, single left testis, hypoplasia of right seminal vesicle, retention cyst of left epididymis. The chief interest centers in this large colloid carcinoma of the stomach and its regional invasions.

The stomach shows at the pylorus an orange-sized nodular mass surrounding the pyloric orifice. There are no ulcers of the mucosa, which in the fresh condition was pinkish and not thickened.

The omentum is deformed, drawn up into a semilunar, grayish-white mass of firm consistence, which is 26 c. wide and 3 c. thick.

The peritoneal cavity contained about nine liters of a reddish fluid with hundreds of small globular masses, jellylike and varying in size from pin head to bean. The peritoneal layers were everywhere covered with small and large whitish nodular masses, some of which were sessile, others pedunculated. Section of these showed them to contain clear or yellowish jellylike material. In the pelvis these masses were larger. The spleen and liver were adherent to the diaphragm. Microscopic examination of the free bodies in the peritoneal cavity showed them to be made up entirely of colloid material. The interesting features in these specimens are the size of the tumor, the metastatic peritoneal secondary tumor nodules, the free colloid masses in the peritoneal cavity, and the fact that death resulted from rupture of an aneurysm of the aortic arch into the pericardium.

Dr. F. Tice presented a specimen of

PULMONARY STENOSIS.

This specimen of a heart is not presented because of its

extraordinary rarity, but from the fact that clinically an uncommon diagnosis was made which was substantiated by the post-mortem. The patient from whom the specimen was obtained entered Cook County Hospital Dec. 9, 1895. He was 23 years of age, and gave a history of having been sick for three months, the symptoms being those of typical pulmonary phthisis. The symptoms did not in any way refer to cardiac trouble. Physical examination of the lungs revealed typical bilateral pulmonary phthisis. The heart was considerably enlarged. On auscultation a murmur could be heard over the aortic valves, not very distinct, in the second right intercostal space. A more decided systolic murmur could be heard to the left in the second intercostal space, which was transmitted a slight distance upward toward the left shoulder. The significance of the murmur was not fully appreciated at first. To Professor Babcock is due the credit of having made a diagnosis of either pulmonary stenosis or aortic aneurism. The case on December 12 left the hospital, and no more was heard of him until the 7th of this month, at which time it was learned that his body was at an undertaker's place, where Dr. Richter and myself had the privilege of making an autopsy. The post-mortem findings of the lungs were those of adherent pleuritis and ulcerative pulmonary phthisis; there was fatty liver, and slight changes in the kidneys. Upon opening the heart the aortic and mitral valves were found to be practically normal, the tricuspids in a similar condition, if anything slightly thickened. On cutting the pulmonary artery transversely and looking down into its opening, we saw at the bottom a process which resembled very much as though a nipple had been forced up into the bottom with a slight opening at its apex. The cusps are entirely adherent along their borders, forming one continuous mass. The right heart is appreciably enlarged. The post-mortem diagnosis was pulmonary stenosis. There was also found upon closer examination a patulous foramen ovale, which would admit one large-sized match and possibly two could have been passed.

An interesting question to consider in connection with this specimen is: Was the pulmonary lesion a congenital one? We are informed by Osler that the condition of pulmonary stenosis is exceedingly rare, and that in the majority of cases it is con-

genital. A pathologic condition of the pulmonary valves (stenosis) is almost always associated with a patulous foramen ovale, which we found in this case, substantiating to some extent the idea that it was congenital. If we conclude that it was not congenital but acquired, we are then confronted with the relation of the pulmonary lesion to the pulmonary phthisis. We are taught that in mitral lesions in which we get congestion of the lungs, that tuberculosis is less frequent, and that in some cases we have a reparative process and find upon post-mortem examination ancient tuberculosis, on the same principle that an osseous tuberculosis of an extremity can be benefited in some cases by circular constriction above the lesion. In this case we naturally had a reverse condition, that of pulmonary stenosis, and a reduced amount of blood in the lesser circulation, this producing a *locus minoris resistentiæ*, into which the tubercle bacilli found an easy invasion.

Dr. Hektoen—The foramen ovale is so frequently patent to the degree shown on this specimen, even in adults, that I do not consider its condition in this particular specimen as favoring either one or the other of the two interpretations advanced in regard to the genesis of the pulmonary stenosis.

## Regular Monthly Meeting, Feb. 10, 1896.

The President, Dr. Weller Van Hook in the Chair.

Dr. M. L. Harris read a paper on

# STRUMA GELATINOSA—STRUMA COLLOIDES.

Of the various pathologic changes which may occur in the thyroid gland, that of colloid formation is the most frequent. In order, however, that this colloid formation may receive the title of struma colloides it is not sufficient that a little colloid material be found in the vesicles or follicles throughout the gland as this is often a physiologic condition, especially in later life, but the colloid formation must occur in a circumscribed area or areas, sharply defined from the normal gland tissue and independently of it.

Furthermore, as Wölfler states, there is in these cases an atypical new tissue formation, a budding of the gland tubules, so that what we really have is an adenoma, in the tubules of which the colloid material accumulates, leading to their distension; hence the name applied by Wölfler of adenoma gelatinosum. These new growths may be single or multiple, and when multiple may be scattered throughout a single lobe or both lobes of the gland. The colloid material may liquify, thus forming little cysts, which, owing to pressure atrophy of intervening walls, may coalesce, producing large cysts. As illustrating these different varieties, I will briefly mention the following cases, operated on during the past year:

*Case 1.* Large single Colloid Adenoma.—E. K., age 21, German; single. Mass size of a goose egg occupying left lobe of thyroid of about one year's standing.

Operation: Enucleation; suture without drainage; primary union; recovery.

*Case 2.* Multiple Colloid Adenomata of one lobe with cystic degeneration.—Mrs. W., age 44. German, married. Multiple nodules involving right lobe of thyroid, extending from upper part of thyroid cartilage to below the upper end of sternum; of several years' standing; lately increasing in size; considerable dyspnea, voice affected.

Operation: Enucleation of all the tumors, two of which were cysts containing thin, dark, bloody-looking fluid. One of the cysts, size of small hen's egg, extending behind the upper end of sternum, enucleated with some difficulty on account of location. Wound closed without drainage. On second day quite profuse hemorrhage occurred from place where cyst had been enucleated, which was easily controlled by removing a stitch and packing with iodoform gause. Primary union and recovery without further incident.

*Case 3.* Large Multiple Colloid Adenomata; both lobes.—Mrs. K.. age 44. American; married. Has had large neck for seventeen years. Since last child-birth, three years ago, tumor has grown quite rapidly. Considerable dyspnea, particularly on lying down. Both lobes of thyroid involved.

Operation: Enucleation. Kocher's transverse incision; wound sutured without drainage. Primary union. Recovery.

The tumors removed from Cases 1 and 3, some twenty in number and varying in size from a pea to a goose egg, are presented. That there is an increased growth of gland tissue in these masses is very evident. The new growth starts in the primitive vesicle or follicle of the gland. The connective tissue envelope of the follicle is pushed aside, and being increased in thickness by the irritation produced by the new growth, forms an investing connective tissue layer or capsule to it. It is the presence of this connective

tissue capsule that enables one to enucleate these growths from the surrounding gland tissue.

A microscopic examination of sections of these masses shows very beautifully the gland follicles lined with epithelial cells and greatly distended with the colloid material. In the section here presented, which was taken from one of the small and presumably younger growths, are seen toward the periphery, many tubules or follicles which contain as yet no colloid material. The rapid proliferation of the epithelial cells seen in these tubules leading to the formation of double and even multiple layers of cells shows clearly the active part taken by the gland elements in these cases, and substantiates the statement of Wölfler that these growths are all primarily adenomatous, the colloid formation being a secondary degeneration.

Other follicles are seen containing large masses of detached epithelial cells, many of which take the nuclear stain very poorly, while in others the contained mass takes the diffuse eosin stain, in which, however, can be distinguished very faint circular and broken circular outlines of nuclei, showing that here the detached cells have undergone colloid degeneration en masse. In some tubules the amount of colloid material is very small and seems to be produced by the layer of cells lining the follicles, while others are distended enormously and contain in addition to the colloid mass many detached cells about the periphery. The capsule inclosing these masses is not simply the connective tissue septa pushed aside, but there is here also an hyperplasia as the increased number of connective tissue nuclei in the section clearly show.

In the removal of benign growths of this character complete thoroidectomy is no longer permissible, no matter how extensively the gland may be involved. These growths, being encapsulated, can always be enucleated after the method of Socin, except where inflammation or calcareous or other degenerative changes have occurred. The best incision is the transverse cut of Kocher. It affords easy access to the entire gland and furnishes the best scar. This latter point is one of considerable importance and has been particularly studied by Sultzer. He examined the scars in 100 cases following operations by various incisions. Of sixty-two scars following oblique or longitudinal incisions, in only one could the scar be considered faultless; the others either contracted so as to interfere with the freedom or range of motion of the neck or were wide, shining and disfiguring; while of thirty-eight scars following transverse incisions thirty-two answered all the demands of a linear faultless scar. The incision should be free enough to allow easy access to all parts of the gland. The sterno-hyoid, sterno-thyroid and occasionally the omo-hyoid muscles should be divided and turned aside. In incising the gland tissue down to the capsule of the tumor, proceed where the tissue is thinnest, in other words, at the point where the tumor approaches nearest the surface, due regard being had for the large thyroid vessels, which are readily recognized breaking up on the surface of the gland. Do not begin the enucleation until certain of being within the right layer of the capsule, as tearing in the gland substance leads to very profuse and troublesome hemorrhage. After the enucleation considerable

oozing is frequently encountered, to check which packing with iodoform gauze is commonly employed, the packing being removed on the second day and the wound closed. I have usually been able to dispense with this packing by firmly approximating the walls of the cavity by a few mattress sutures of catgut. The posterior surface of the gland must be avoided in passing these sutures on account of the proximity of the recurrent laryngeal nerve. The mortality of enucleation in these cases is practically nil, being less than 1 per cent.[1] The last point to be considered is the question of recurrence after enucleation. Sultzer was able to follow out sixty-three cases of enucleation. Of these, forty-four remained free of recurrence, while in nineteen, other nodules developed; eight times in the same lobe operated upon and eleven times in the opposite intact lobe.

DISCUSSION.

DR. F. C. SCHAEFER—There came under my care recently a case which might be appropriately reported in this connection. I removed a parenchymatous goitre for exophthalmos four weeks ago from a girl aged 18 years. You will notice that it is similar in appearance, excepting the shape, to the specimens exhibited by Dr. Harris. On looking at it from a distance you might think it was an enlarged kidney. At the time of its removal (four weeks ago) it was six inches long, two and a half inches wide and two inches thick at the central part. At one point above its middle portion it presented a hook-like projection, an "accessory" lobe which extended under the trachea, and as the trachea was already flattened by pressure from the body of the goitre, this accessory portion added materially to the embarrassment of respiration. I succeeded in enucleating one-half of the growth, the remainder had to be excised. The gland is very dense and hard. Microscopically the follicles can be seen packed to distention with epithelial cells, irregular in

[1] Kocher.

outline, with an occasional spot of colloid. Undoubtedly the disease began in the follicles and the cells of the parenchyma were stimulated into activity by the cell proliferation in the former. A special point in the case is the exophthalmos. The girl presented all the symptoms of Basedow's disease, excepting the bronzed skin. She had marked tachycardia, pulse rate 145; difficult breathing; husky voice; slight protrusion of the eyeballs; tremors of the muscles of the entire body, more especially of the chest muscles. The patient was excessively nervous, could not sit quietly in a chair, and had extremely restless nights; would toss about in her sleep and was frequently obliged to get up two or three times during the night to breathe. I felt, under the circumstances, that the goitre should be removed. The eyes on ophthalmoscopic examination by Dr. H. M. Starkey and myself showed spots of hemorrhage and anemia in the fundus, also congested veins. Sight very much diminished, R. E. V. 20-200, L. E. V. 10-70. In operating I followed the same incision as Dr. Harris (Kocher's) extending across the neck. On the left side I took out only a small portion of the growth, to avoid the sequela of myxodema. The young lady is improving every day, her respirations are improved, pulse rate 105 and she claims that her sight is already much better. I hope ere long to be able to present the patient.

Dr. D. N. Eisendrath read an abstract of a paper entitled

SPONTANEOUS DISLOCATIONS OF THE HIP-JOINT OCCURRING IN THE COURSE OF ACUTE INFECTIOUS DISEASES.

Traumatic dislocations of the hip are of such relative frequency that they interest the surgeon but little more than dislocations of the other joints. Not so with spontaneous luxation of the hip. But few cases of this kind have been reported. They were first observed, in 1853, by Lorinser, who reported a dislocation of the hip occurring spontaneously during typhoid fever. Roser, in 1857, called attention to the fact that this condition was known to Hippocrates, who ascribed it to hydrops of the joint. Numerous post-mortems made during the present century confirmed this theory. Parise attempted to reproduce it by injecting fluid into the joint, and found that the head moved away from the acetabulum. The capsule in order to stretch was obliged to assume a spherical shape, pulling the

head with it. The only modern writer who disagrees with this theory is Verneuil, who believes that it is produced through muscular action. He claims that there is a paralysis of some of the muscles about the hip-joint and that their antagonists pull the head out of the acetabulum. This theory has no other supporters. Güterbock reported four cases, in 1874, occurring during the course of typhoid fever. These took place suddenly without any trauma, the only symptom of a joint affection having been pain in both hips. Verneuil, in 1883, reported six cases occurring during acute articular rheumatism. Delens added two to the list of spontaneous luxation of the hip, these occurring during typhoid. Sainton also reported a number of cases in 1892, and Champenois recently collected and published ten cases, all taking place during convalescence from typhoid fever. The right hip was most frequently affected. Kirmisson reduced a dislocation which occurred during acute articular rheumatism on the twelfth day in a girl 18 years of age, and also published a case in which the dislocation occurred during scarlatina. Phocas, in 1894, reported a typical case in which a dislocation of the hip occurred during convalescence from typhoid. The writer, in addition to the case reported, saw a double dislocation of the hip which had taken place spontaneously during scarlatina, at the clinic of Professor Lorenz in Vienna. The case observed was one of a girl 12 years old, who was admitted to the service of Dr. Sick in the Hamburg Hospital. During an attack of influenza a spontaneous backward dislocation had occurred. Six months after this happened she was operated upon by Dr. Sick, who found the acetabulum filled by inflammatory tissue, the head of the femur and the acetabulum exactly corresponding in size. The capsule was almost completely destroyed. There was no osseous focus. The head was replaced after the acetabulum had been curetted to remove the inflammatory tissue which filled it. Recovery took place very slowly, the wound having suppurated. The occurrence of such a spontaneous dislocation during an attack of influenza would seem possible, since during this disease exudation into joints takes place, as Franke has recently reported. This is the first case in which such a dislocation has been observed during influenza, the other diseases in which it

has occurred being scarlatina, typhoid and acute articular rheumatism.

DISCUSSION.

DR. M. L. HARRIS—The question to be raised in most of these cases is whether we have to deal with an arthritis, or with a case of osteomyelitis. In the first place, these cases almost invariably occur during the developmental period, before complete growth is reached. The tendency of micro-örganisms to localize themselves and develop in growing bone is well known. These cases of dislocation of the hip-joint occur more frequently in certain infectious diseases than in others. For instance, typhoid fever is a disease in which dislocation of this joint is apt to occur, and we know the typhoid bacillus in this disease can always be found in bony tissue. Other organisms are not so liable to locate themselves in bone, and in the diseases produced by them we do not have dislocations so often. In scarlet fever we frequently have effusion into the joint, but dislocation of it is comparative rare. Effusion into joints occurs in other infectious diseases, as in measles, mumps, dysentery and variola, but dislocations in those diseases, however, are very rare, showing that there must be something besides a synovitis to produce the dislocation. Crepitus has been observed, as in the case mentioned by Dr. Eisendrath, and when the joint was opened there was found erosion of the acetabulum, showing that there was osteomyelitis present. The great frequency with which the hip-joint is affected is another point in favor of osteomyelitis. As is well-known, the femur is the most common bone to be affected by osteomyelitis. In ordinary osteomyelitis from pyogenic infection the upper end of the femur and pelvic bone or hipjoint are affected many times to once of any other joint. To give an illustration, in twenty-two cases, by Müller, the hip-joint alone was affected sixteen times, the remaining six cases being distributed, showing the great frequency with which the hip is involved. Here it was found that the acetabulum was the part primarily affected in 25 per cent. of the cases. Another thing which points to the fact that these cases are probably osteomyelitic is the failure to reduce the dislocations and keep them so. In dislocations which follow typhiod fever reduction and retention have been very seldom accomplished. If we have a

dislocation of an intact bone there is no reason why the reduced dislocation should not be retained. Ankylosis occurs quickly after these dislocations, much quicker than it does after traumatic dislocations, showing again disease of the osseous tissue. So I think the majority of these cases are not, strictly speaking, cases of synovitis but of the osteomyelitis, the infection extending secondarily to the synovial membrane.

DR. EISENDRATH (closing)—I believe in a certain proportion of cases that the dislocation is due to a primary osteomyelitis rather than a primary synovitis. I do not know whether the cause of suppuration in this case was an infection from without, or from some osteomyelitic focus in the head of the bone, or whether it was due to the scarlatina through which the patient had passed four weeks previously. But there is one case recorded in which an abscess appeared at the popliteal space, that might possibly have been construed as an abscess which had come from a primary osteomyelitic focus. There are undoubtedly cases where dislocation occurs as in articular rheumatism and scarlatina, where we have associated with it a primary synovtis and not osteomyelitis. In the case in which it occurred after influenza we could find no foci at the time. The true acetabulum was covered with inflammatory tissue; but the cartilage itself was eroded in a few places. There were no osseous lesions to be found.

EXHIBITION OF SPECIMENS.

DR. E. J. SENN exhibited specimens of *Pyosalpinx*, which were of particular interest because of their size and marked contortions. The specimen was from a woman 29 years of age, who had been married ten years, and had not given birth to any children. The trouble had existed for six years. The symptoms were those ordinarily present in such cases, with marked pains in the lumbar region of a decidedly intermittent character. There was a constant discharge of pus from the cervix uteri.

DR. WILLIAM HESSERT asked if the paroxysmal pains were followed by purulent discharge from the uterus.

DR. SENN—No; the discharge was constant.

DR. EMIL RIES called attention to the value of the specimens as examples of the contortions of the tubes as described by Freund, which he thought to be due to the rudimentary devel-

opment of the tubes, the embryonal or infantile characteristics being preserved.

DR. JAMES B. HERRICK presented specimens from a case of

TYPHOID FEVER WITH FATAL INTESTINAL HEMORRHAGE COMPLICATED BY ECTOPIC GESTATION.

The specimens were obtained from the body of a woman who had come to the County Hospital, Jan. 25, 1896, dying ten days later of acute anemia following intestinal hemorrhage. The anatomical diagnosis (Drs. L. Hektoen and F. Tice) was as follows:

1. Accidental Findings: Adherent pleuritis; healed pulmonary tuberculosis; adherent pericarditis; chronic endarteritis and valvular endocarditis; chronic nephritis; ureteral anomaly.

2. Typhoid fever: Splenic tumor, enlarged mesenteric glands, ulcers in ileum and colon, blood in cavity of intestines, typhoid bacilli in heart's blood, in spleen and kidney.

3. Ectopic Gestation: Uterus slightly enlarged, left tube normal, right tube to be traced for one-half its length; in median line of uterus and firmly united by adhesive bands to the uterus and to the neighboring intestinal coils, a gestational sac the size of a large cocoanut and containing a mummified fetus, placental tissue and an old blood clot. Attention was called to two facts of interest in connection with the case: 1. The rarity of the combination of typhoid fever and ectopic pregnancy. A somewhat extended, though not yet completed, search through the medical indices had failed to show a previously recorded case of this kind. The case seemed to be unique. 2. The difficulty presented in diagnosis. The woman had given a history of an abortion at three months induced by the ingestion of drugs. Following the supposed abortion she had flowed for quite a number of days. Then there had developed a chill, headache, malaise, anorexia, fever. We were in the midst of an epidemic of typhoid. The question naturally arose whether the case was one of typhoid fever or of puerperal septicemia, the globular mass easily felt above the symphysis being taken for an enlarged uterus perhaps containing a dead fetus or undischarged secundines. The absence of local tenderness, of uterine discharge and of fetor, and the resemblance

of the general symptoms to those of typhoid, lead to a policy of expectancy. This was rewarded in a few days by the appearance of rose-spots, enlarged spleen and a fatal intestinal hemorrhage, making clear the diagnosis of typhoid fever. Even had the existence of extra-uterine pregnancy been made out during life, the question of infection through the uterus, or the infection of the contents of the sac, would have arisen and would have rendered an early diagnosis a matter of extreme difficulty. A closer scrutiny of the history of the case in the light of the post-mortem findings, lead one to think that there had been a right tubal pregnancy with rupture about seven weeks prior to the patient's entrance into the hospital. For there is a somewhat indefinite account of abdominal pain at that time with some collapse or syncope.

Dr. F. C. Schaefer presented a *Uterus with large Fibroid Tumor*, which had been removed by abdominal hysterectomy. The tumor was lobulated, weighing eight pounds. One lobe had filled the cul-de-sac of Douglas. The uterine canal was three inches deep. Patient did nicely after the operation.

Dr. Emil Ries exhibited a *Vermiform Appendix with a Fecal Stone* in its lumen, which had been removed by operation. The symptoms were peculiar in that inability to urinate was present from the onset. The diagnosis was made by the detection of swelling about the appendix by rectal examination.

Dr. Weller Van Hook referred to a similar case in which diagnosis of lead colic and renal calculus were successively made. The rectal examination finally cleared up the diagnosis.

## Regular Monthly Meeting, March 9, 1896.

Dr. James B. Herrick, Vice president, in the Chair.

Dr. James B. Herrick read a paper entitled

# TWO CASES OF PERNICIOUS MALARIA WITH RELAPSE.

In the reports of pernicious malaria I would direct attention to the following facts:

1. The comparative rarity in this climate of the pernicious type of malaria.

2. The somewhat unusual complication in an adult of convulsions (Case 1).

3. The occurrence in the child of convulsions oft repeated and resembling the petit mal of epilepsy and yielding only to quinin.

4. The ready explanation of the cerebral symptoms, afforded by recent pathologic studies.

5. The illustration of the necessity of blood examination as an aid to diagnosis.

6. The course of the temperature in Case 1 characteristic of the pernicious tertian fever, prolonged stage of fever, precritical rise, etc.

7. The relapse (Case 1) with change of type to the quotidian.

8. The lesson that even yet needs an occasional enforcement of the specific effect of quinin.

COMA; FACIAL PARESIS; CONVULSIONS; RELAPSE; RECOVERY.

*Case 1.*—Nov. 9, 1895, there was admitted to the County Hospital to the medical service of Dr. Norden, to whose kindness I am indebted for the privilege of seeing and reporting

the case, a young man who was in such a condition of stupor that no history could be obtained. Nor could those who brought him to the hospital furnish any facts concerning the duration of the illness or its past course.

The face was somewhat flushed, the skin dry, the pulse 108 and rather weak, respiration accelerated, 24 to 40. The temperature was 104 degrees F. There was no exanthem. No bruise, mark or other evidence of injury, and no focus of suppuration could be found. No enlarged glands were detected. The tongue, while moist, was heavily coated; the patient was too stupid to protrude it.

The examination of the head was negative save for a slight paresis of the facial muscles on the left side. The retina was negative. The lungs and heart upon physical examination revealed nothing abnormal. The limbs, the osseous and muscular systems were negative. The urine contained neither albumin, sugar nor casts. The only positive finding was an enlarged spleen, the edge of which was distinctly palpable, two fingers' breadth below the costal arch. The temperature on admission at 4 P.M. was 104. The next morning at 2 o'clock it was 98.8, pulse 94.

Late in the evening of the same day an examination of the blood showed the plasmodium malariæ. Dr. Lemke, the house physician, who made the examination, found but a solitary parasite in the four slides examined. But this was so unmistakably the malarial organism that the diagnosis was beyond question. The parasite was endoglobular, somewhat irregular in contour, filled about one-half of the rather pale red corpuscle and contained fine, actively moving, dark pigment.

November 10: In stupor; temperature normal.

November 11: 12:15 A.M., chill lasting one and one-half hours. Patient during chill did not shake violently. Axillary temperature after chill 104.2. Patient very stupid. At 8 P.M. temperature 105. Quinin sulphate, gr. XV, was ordered to be given at 4 A.M. and at 4 P.M. for six doses; also five drops of Fowler's solution three times a day.

November 12: 4 A.M., convulsion lasting about two minutes. Pulse 100; temperature 98.6, respiration 28. 2 P.M., quinin bisulphate gr. XV, given hypodermically. 3 P.M., convulsion lasting three minutes; urine negative. 6 P.M., vomited.

November 13: 4 A.M., temperature 100.2; no chill; quinin gr. xv.

November 14: 8 A.M., pulse 68; temperature 95.4 (taken twice in axilla and twice under tongue); respiration 18; vomited breakfast.

November 15: Still somewhat dull.

November 16: Considerably brighter; given clothes.

November 18: Mental condition much improved. Denies ever having had convulsions before entrance to the hospital. Says was sick four or five days before being brought to the ward. Had pain in the side and legs; vomiting; severe headache. Has no remembrance of how he came to the hospital. Does not remember chills or fever. During the summer of 1895 was sick in hospital in St. Louis. Does not know exact nature of illness. Spleen still palpable.

The record does not show the temperature between November 20 and December 2, during which period the patient was helping about the ward and kitchen. During this time he did not take quinin.

December 2: Noon, chill; temperature 104; quinin begun.

December 3: 11 A.M., chill; temperature 102.8.

December 4: 3 P.M., temperature 103.3.

December 5 to 8: Temperature normal. Patient left hospital at his own request.

This case presents several points of interest both from a clinical and pathologic standpoint.

*Mode of Infection.*—There is no definite knowledge of when or how the primary malarial infection occurred, though it was presumably in the south. The majority of the cases seen in Chicago are, I think, either imported malarias, drainage-canal cases, or the exacerbations of the disease in those infected long before, and in whom we are forced to assume the disease has remained latent, though what is the true nature of the so-called latency is as yet unsettled. Still, there are seen occasionally, developing in our city's midst, unquestioned cases of paludism in which one is at a

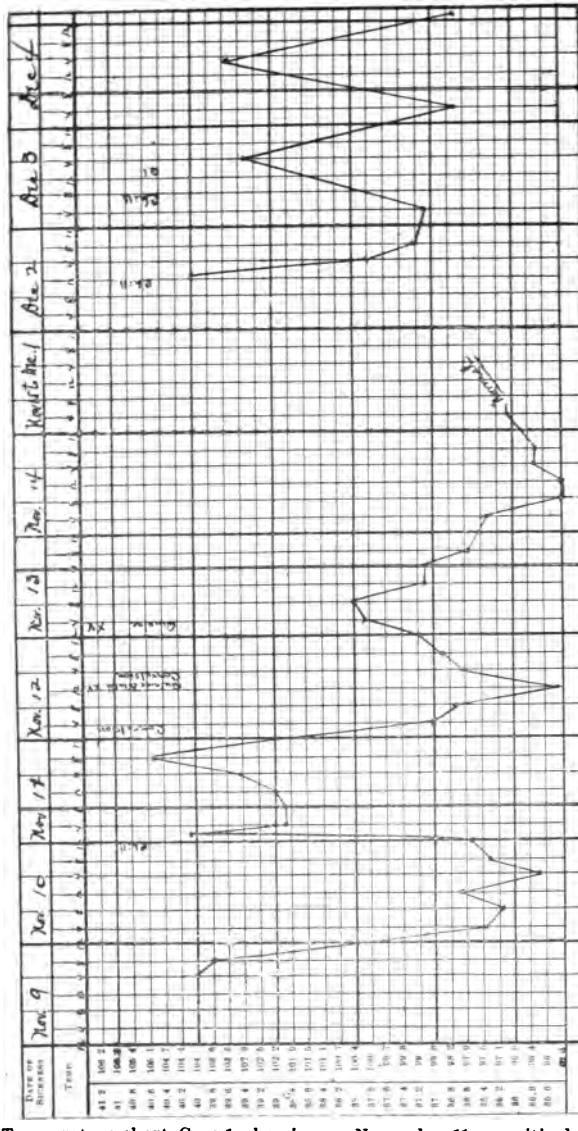


Temperature chart, Case 1, showing on November 11 precritical elevation of temperature, followed by pseudo-crisis. From November 14 to December 1 the temperature was normal and is not shown. The relapse is shown beginning December 2. December 5 the temperature was normal and remained so for three days, at which time the patient left the hospital. Some quinin was given by the mouth between November 10 and 14, but much of it was vomi'

loss to know where to look for the source of infection.

*Value of Blood Examination.*—The case illustrates the positive value of blood examination. Without such an examination a diagnosis in a case of this character, in a supposedly non-malarial district and with no previous history would be at the best guess-work. One would be hesitating between cryptogenetic septico-pyemia, cerebral abscess, meningitis, concealed pneumonia, etc. With the blood examination the diagnosis is a matter of certainty, treatment is clearly outlined and followed by brilliant results. We may, with reason, say that death was averted by the vigorous exhibition of quinin in this instance.

*The Parasite.*—While a more thorough study of the parasite would have been desirable, being prevented largely by the necessity of early administration of quinin, we may fairly conclude that the type of organism was the æstivo-autumnal. The paucity of plasmodia in the peripheral blood, but one organism being found after careful search in four specimens, argues in favor of the estivo-autumnal type, where the parasite is found in far greater numbers in the visceral blood. One is scarcely warranted in asserting, from the inspection of a single endoglobular parasite, half-filling a somewhat pale red corpuscle, the parasite containing a small amount of fine pigment in active motion, that the parasite is of a certain definite variety. Yet this description fits some of the larger forms of the estivo-autumnal type better than it does the half-ripe forms of the tertain or quartan.

*The Temperature.*—The course of the temperature is that of severe estivo-autumnal fever. During the first attack, the severe one, the paroxysms were of the

tertian type. The febrile period, it is to be noticed, is the prolonged period of twenty-four hours characteristic of the pernicious forms of the disease. I would call attention also to one other characteristic of the temperature. After the chill on the morning of November 11, the axillary temperature was 104.2. Two hours later it had dropped to 102 degrees, and it rose again to reach its highest point, 105 degrees, sixteen hours later. This precritical elevation of temperature, with pseudo-crisis (calling to mind the pseudo-crisis of pneumonia) is emphasized by Marchiafava and Bignami in their description of the estival or pernicious tertian fever. Thayer and Hewetson in their monograph give a graphic representation of this same peculiar behavior of the temperature in the severe autumnal fevers.

*Effect of Quinin.*—The beneficial effect of quinin given hypodermatically is well illustrated by the accompanying temperature charts.

*Relapse and Change of Type.*—It is of interest also to note the change of type of the paroxysms during the recidivation beginning December 2. Here we see a well-marked quotidian type. The autumnal malarial fevers, whether passing under the name of pernicious tertian or a estivo-autumnal fevers, are marked by an apparent lawlessness in the behavior of the temperature. This has not yet been found associated with a definite cycle of development of the parasite. The cycle may be of indefinite length or there may be various groups of plasmodia maturing at frequent intervals thus accounting for the great length of the paroxysm or the presence in some cases of a continuous or remittent fever. The quotidian

type in this case may have been due to the destruction by the quinin of some of the weaker groups of plasmodia and the remaining of two groups having a cyle of twenty-four hours as in a double tertian. Thayer and Hewetson conclude as the result of their study of this form of disease that "the cycle of existence of this parasite has not been followed out in an entirely satisfactory manner" (p. 160).[1]

*Pathology of Pernicious Malaria.*—The explanation of the cerebral symptoms—stupor, facial paresis and convulsions, is to be sought in the blood vessels of the brain. The cerebral phenomena of malaria have been explained at various times on the score of congestion, of melanemia with pigment emboli in the capillaries (Planer 1854, Frerichs and others), and of endothelial swelling of the cerebral capillaries and consequent narrowing of the lumen of the vessel (Kelsch and Kiener). Since the plasmodial epoch, however, these manifestations have been regarded as due to the toxemia that undoubtedly accompanies hemic plasmodial develpment, or to the organic disturbances produced in the encephalon by the aggregation in the vessels of infected corpuscles.

While not denying the possible agency of toxemia in the production of malarial delirium, coma, convulsions or paralysis, one can not overlook the fact that in numerous instances there has been disclosed such plain obstruction of cerebral vessels by impacted infected corpuscles as to make it unnecessary to invoke the aid of an intoxication hypothesis. Such palpable mechanical interference with circulation must

[1] The Malarial Fevers of Baltimore, Johns Hopkins Hospital Reports, Vol. v. 1895. A most complete bibliography of malaria since the announcement of Laveran's discovery is given in the monograph.

seriously alter the nutrition and consequently the functions of the brain. At times aphasia, local paralysis or convulsion point to a distinctly focal brain lesion. The physicians in our Southern States not infrequently describe cases of this sort. In the case in hand there was a slight facial paralysis. Marchiafava in a case with bulbar symptoms found occlusion of the medullary vessels by plasmodial thrombi. Danilewsky[2] found in the blood of a patient with paludism a large, free, semilunar form, evidently from its pigment, a hemocytozoön. In width it was nearly the diameter of a red blood corpuscle; in length it was about three times the diameter of a red corpuscle. He calls attention to the possibility of a mechanical obstruction of a capillary or arteriole by such a large body, with marked consequences if the vessel were in the medulla. So that circulatory obstruction would seem to be the cause of many of the cerebral symptoms in pernicious malaria.

The Italians, Marchiafava and Celli, and Bastianelli and Bignami have called attention to the fact that the infected corpuscles red and white, particularly in the cerebral vessels, can be seen lining the vessel wall, perhaps as Mannaberg[3] suggests because of a certain acquired viscosity. Circulatory obstruction and thrombosis would thus be favored. Mannaberg depicts from some of Golgi's specimens, cerebral vessels lined and filled with infected corpuscles both pigmented and unpigmented. Dock[4] also shows a microphotograph of a cerebral capillary with numerous pigmented corpuscles.

---

[2] Danilewsky, für Kenntniss der Malaria-mikroben bei Menschen. Centralblatt f. Bakt. und Paras., xviii, No. 8. Sept. 19, 1895.
[3] Mannaberg, Die Malaria Parasiten, p. 161.
[4] Dock, Pernicious Malarial Fever, Amer. Jour. Med. Sciences, 1894.

Minute hemorrhages from vessels thus thrombosed are mentioned by many, *e.g.* Bastianelli and Bignami, Mannaberg, Golgi, Dock, Councilman and Barker. Attention may be called, in passing, to the finding of similar capillary and arteriolar thromboses in other than the cerebral vessels. In cases where gastric symptoms have been pronounced, the vessels of the stomach have been found plugged with infected thrombi.[5] The same condition has been found in the intestinal vessels. It is still unsettled why, in a given case, the infected corpuscles select the vessels of a certain organ or certain vessels of one organ and shun others.

*Rarity in Chicago.*—So far as I can learn this is the second case of pernicious comatose malaria admitted to the County Hospital in the last few years, *i.e.*, since systematic examination of the blood has been made in all suspected cases. During this time scores of patients with malaria, chiefly from the drainage-canal district, have been seen in our wards.

COMA; EPILEPTIFORM CONVULSIONS; RECOVERY.

This case was seen in consultation with Dr. M. H. Stephens, to whom I am indebted for many of the facts.

*Case 2.*—Louise T., 5 years; native of Canada. Said to have lived in malarial district. Mother neurotic; father died of cerebral hemorrhage. Frail, nervous, poorly nourished as a babe. "Brick-dust" in urine. At 15 months, convulsions lasting from 10 P.M. to 7 A.M., followed by fever which mother said was "typhoid pneumonia." Dec. 31, 1894, 10 P.M., convulsion followed during night by a second one. Regained consciousness only after many hours. History of fever somewhat doubtful. Many attacks of petit mal at this time. These are

[5] Barker, A Study of Some Fatal Cases of Malaria. Johns Hopkins Hospital Reports. Vol. v, 1895, p. 239.

said to have continued with more or less frequency until the fall of 1895.

Oct. 17, 1895, at noon, seized on the street with convulsion. Regained consciousness at 8 P.M. Dr. Stephens administered chloroform to ward off what appeared to be threatening convulsions.

October 18: Temperature A.M. normal.

October 19: 9:30 A.M., chill; temperature at noon 104.5.

October 20: Forenoon, chill; temperature 103.5. Between 4 and 6 P.M., normal.

October 21: Temperature 105.2; no further chills; temperature irregular from this on, varying between normal and 104.

October 22: Patient seen in consultation with Dr. Stephens.

*Examination.*—Mind clear, urine negative. All organs negative save an enlarged and plainly palpable spleen. No typhoid spots. Next day, October 23, blood examined and a single hyaline endoglobular body with small amount of blackish pigment found; this believed to be the malarial plasmodium.

October 26: Temperature 101 degrees at noon, following this normal. The later history of the case is best learned from Dr. Stephens' letter of Dec. 23, 1895:

Dear Dr. Herrick:—Your inquiry regarding Louise T. is just received. I am very glad to say that the child is doing well. The quinin, two-grain doses, three times a day, was continued for about a week. Then the dose was reduced. The fever rapidly disappeared and the little girl was out in about two weeks. She had no "petit mal" attacks from time of her severe convulsion at the beginning of her illness, until about two or three weeks ago. She had had no quinin for about a month. Had been on syr. ferri iod. and syr. hypophos. co. About two or three weeks ago she began having mild attacks beginning with one or two a day and increasing rapidly until she had from twelve to fifteen during the day. For a time I kept her on sod. bromid and also liq. sodii arsenitis, with no effect. Began giving quin. sulph. gr. i three times a day about a week and a half. She improved rapidly and is now free from the mild attacks.

Yours sincerely, M. H. STEPHENS.

I regard this case as malaria for the following reasons: 1, lived in malarial region in Canada; 2, the previous febrile attacks attended by convulsions from which recovery had taken place, may well have been malarial, their repetition tends to exclude masked exanthemata, pyemia, malignant endocarditis, cerebral abscess, etc.; 3, remittent fever and chills; 4, enlarged spleen; 5, exclusion of other diseases; 6, yielding to quinin; 7, the detection of the plasmodium.

It is perhaps assuming more than can be proven to say that all the epileptiform attacks were due to malaria. But it seems warrantable to assume that in a neurotic child, the malarial infection acting upon an irritable cortex was the exciting cause of an outbreak of an otherwise dormant epilepsy. The prompt response of the petit mal to quinin, when bromids, etc., had failed, is very significant of a persistent mild malarial toxemia, that might be entirely symptomless and overlooked were not the child predisposed to cortical irritation.

Krafft-Ebing[6] records a case resembling in some particulars the one I have reported. The case is of such interest that I give a synopsis of it:

Male, 29 years, rheumatic, with mitral lesion. August, 1886, intermittent fever, treated for three months; no epilepsy, no delirium. June, 1888, relapse. During fever fell and injured right mastoid process. Since then muscae, dimness of vision. Two days after injury slight attack of unconsciousness. July, two attacks. August, two attacks. September: Daily attacks of unconsciousness with convulsion; fever and delirium; no aura; no scar tenderness; cranial nerves, retina, sensibility, urine, all negative. Slight amblyopia; no hysterical stigmata. Spleen enlarged and easily palpated. February 17, 1891: Chill and convulsion. Up to March 8, there were daily sev-

[6] Zur Intermittens Layvata, Wiener Med. Presse, 1892, 1-4.

eral attacks with convulsions. The delirium that played a prominent part is accurately described. Fever persistent. March 8: Quinin, gr. v daily. March 16: Quinin, gr. xv daily. Temperature gradually fell to normal, spleen decreased in size and on April 1, patient left hospital apparently well.

April 10 reëntered hospital with large spleen, and fever. Repetition of epileptiform attacks with delirium. Recovery May 15, under quinin.

Symptomatically this was an epileptoid neurosis. Naturally traumatic epilepsy had to be considered. Krafft-Ebing regards it as a case of masked malaria in which an injury to the head determined the point of the malarial attack, making of the brain a *locus minoris resistentiae*. Unfortunately no blood examination was made.

DISCUSSION.

DR. L. L. MCARTHUR—I would ask if in looking up the literature of the subject you have found anything in regard to suppression of urine by occlusion of the vessels of the kidney from the plasmodium? The reason I ask the question is, that, during the present week, I have had a case of malaria poisoning of the pernicious type referred to by Dr. Herrick, develop in a patient convalescing from a hernial operation at the Chicago Hospital, under the best of sanitary conditions. It is quite inexplicable how it may have originated. The temperature ranged extremely high, 103 to 105.5; the blood was laden with plasmodia, as shown by Dr. Frank Johnson. There was persistent vomiting, with pain in the back so marked that my attention was turned chiefly to the kidneys; the quantity of urine voided being eighteen ounces in twenty-four hours, heavily laden and highly colored; no albuminuria, no blood, no casts. But the plasmodium being found in the blood and the fever yielding to quinin, made me think that it was a malarial affection of the kidney. Possibly an embolic effect of the renal vessels, as suggested by the paper.

DR. SANGER BROWN—I would ask Dr. Herrick if in looking up the subject he has found that the plasmodium is discovered in patients who are not subject to malaria, or who have none of the positive symptoms of the disease. I saw in consulta-

tion a month or two ago an interesting case in which a man of 60 had attacks of unconsciousness, which were repeated several times in the course of three or four days. In the intervals he was not quite clear mentally. The question arose as to whether they were preliminary to a stroke of apoplexy, that is, small hemorrhages, or not. His son, who is quite an accomplished pathologist, made a careful examination of the blood and found the plasmodium in several slides. About a week after this the man had an attack of apoplexy which was fatal. If the blood had not been carefully examined in this case and the plasmodium found, it doubtless would not have been thought of attributing the symptoms to malaria. It would be regarded simply as the premonitory or preliminary light attacks of apoplexy or cerebral hemorrhage. I would also ask whether in the comparative number of plasmodia found in the accessible blood the examination bears any constant relation to the severity of the malarial symptoms, assuming that the cases which have been cited were cases due to malaria. If the symptoms were due to malaria, it would seem that they were severe, and the plasmodia ought to have been very numerous.

Dr. D. W. Graham was reminded by Dr. Herrick's paper of an experience some years ago before the plasmodium had been demonstrated. The patient while spending some weeks in Louisiana, where malarial fever was very common, had daily chills, and on his return became comatose and hemiplegic. He was given large doses of quinin with the hope that his condition was due to malaria. Although thought to be a case of cerebral hemorrhage by the consultant, consciousness soon returned and the hemiplegia passed away with the exception of a slight weakness of the afflicted arm. The effect of the plasmodium on the cerebral circulation, as given by Dr. Herrick, would seem to explain in a very satisfactory way this and many similar cases.

Dr. Wm. Hessert—Dr. Herrick has brought out many important points in his paper, one of which is the examination of the blood in all cases of doubtful diagnosis, and even in cases where the diagnosis is more or less positive. Having had occasion to examine blood very frequently, I have come across phenomena, an explanation of which I have been unable to offer. For instance, I have seen minute particles of freely

mobile material consisting of fine granules, these particles being in active motion. I have found bodies of different sizes and shapes in the blood. Some were dumb-bell shaped, others more or less biscuit shaped, and still others that were spherical. They were evidently not blood-plates, being opaque and yellowish in color, and not collected in clumps. The motion of these bodies was rapid, and I have been unable to tell whether they have ciliary appendages or not. In some instances I have found cilia, and for instance some in my own blood had cilia, and I certainly had no malaria. I have been unable to stain these bodies, which is an important point. I would like to get information from Dr. Herrick as to whether he has seen these phenomena himself. Some of the granules I speak of may be explained in this way, namely, I have seen eosinophilous cells in fresh slides break up, the granules becoming free and scattering through the field; but the nature of the other bodies I have been unable to determine.

Dr. Robert B. Preble—My remarks are suggested by the question asked by Dr. Brown as to whether the malarial plasmodia have ever been found in the blood of patients who show no symptoms of malaria. Without answering this question, I would like to draw attention to a few bodies found in the blood, which may be readily mistaken for the plasmodium. The malarial plasmodia, in their typical forms, are easily and positively recognized; but it is not always easy to say, that a certain body which you see in the blood, is or is not a plasmodium. We gather from the wording of Dr. Herrick's paper that he was somewhat in doubt as to the malarial nature of the second case and he expressed himself very guardedly as to the nature of the body found in the blood and believed by him to be the plasmodium of malaria. A not infrequent error is to mistake a cremated red corpuscle for a plasmodium. One often sees a red blood corpuscle with a number of small clear circles arranged about the center of the disc of the corpuscle. The border of the disc is unchanged. This gives one an appearance somewhat resembling the sporulation form of the plasmodia. The difference, however, is so great that error is impossible, when the true segmentation figures have been seen once. Another thing, which may also lead to error, is the movement of the granules of the protoplasm of the white corpuscles. This

motion is sometimes as active as that of the granules of the plasmodia and resemble it perfectly. The differences between a white corpuscle and a red containing a plasmodium, are so great that error is possible only when one forgets that the granules of the white corpuscle move at times. Dr. Hessert has mentioned the fact that auto-mobile bodies are often found in normal blood. The knowledge of this fact is not so general as it should be. These bodies show a great variety of forms and are often so active, that the slide must be kept in constant motion to keep them in the field of the microscope. They are, no doubt, frequently mistaken for the plasmodia. Before closing, I would like to draw attention to a very common error in the method of examination of the blood for plasmodia. It is common practice to dilute the blood with a solution of methyl blue, in this way staining the plasmodia. I believe that this is a fruitful source of error, for while it stains the plasmodia, which can be recognized as easily unstained, it also stains other bodies which can now be mistaken for the organism. Thus a member of the profession, who holds and deserves a high position, showed me a lymphocyte stained with methyl blue and which he believed to be a plasmodium. That error would not have been made if the specimen were unstained. This error is only an example of the many which may and do occur with this method of examination and I agree with Thayer and Hewetson that it is best to examine fresh specimens unstained.

Dr. Herrick (closing)—In answering the question of Dr. McArthur, I would say that plasmodial emboli have been found in the kidneys, chiefly, I believe, in connection with hematuria. As to the question asked by Dr. Brown with regard to finding plasmodia in non-malarial blood, I think that it is almost a contradiction in terms to say that plasmodia can be in the blood without malaria. We must assume, I think, that if a patient has the plasmodium in his blood he has malaria. Yet he may be free from symptoms. The question of latency of malaria is one that is by no means clearly understood. In patients who are entirely free from fever, who have been cured by quinin, the malarial plasmodium can sometimes be detected, and particularly are the crescent forms of the plasmodium persistent, long after all febrile manifestations have disappeared. This will call to mind the analogous finding of diphtheria bacilli in

the throat in cases of diphtheria that clinically are cured, as well as the finding of tubercle bacilli in the sputum of those without symptom or sign of phthisis. The case which Dr. Brown speaks of might possibly be one of malaria with a thrombus due to infected blood corpuscles, a hemorrhage as the result of obstruction of a blood vessel by such corpuscles, an accidental combination of malaria and cerebral hemorrhage, or a mistake in recognizing the plasmodium.

The second question Dr. Brown asks is whether there is a relation between the number of plasmodia found in the blood and the malarial manifestations. That may be possibly true with regard to tertian infection, but with reference to the estivo-autumnal type, there is not that relation. The visceral blood, for instance, will contain a multitude of plasmodia, while the peripheral blood may be examined repeatedly and the plasmodia will be found absent. In the County Hospital case, the first one I reported, an unusually grave one, there is no question with regard to the diagnosis; yet in the blood on four slides only one plasmodium was found after careful examination. Dr. Graham's case may have been one of the severe cases of malaria with obstruction of a blood vessel from infected corpuscles.

Dr. Hessert and Dr. Preble have called attention to a very important point, and it is gratifying to see two gentlemen who have done so much in examining the blood frankly admit the great difficulties in recognizing plasmodia. As Dr. Preble says, when we have a typical ripe tertian organism it is recognized beyond the shadow of a doubt, yet there are many forms that are difficult of recognition, particularly the smaller ones that are but half developed, and the hyalin forms. And there are many things that can mislead the physician in examining the blood. I have seen in unstained specimens the eosinophilous granules referred to by Dr. Hessert. The coarse granules of the eosinophilous cells, when scattered about, resemble hyalin bodies. But staining brings them out clearly with acid rather than with an alkalin dye. They can readily confuse one. There are other forms that are apt to cause confusion, *e. g.*, the blood plates.

I was interested in reading an article by Paltauf (*Centralblatt f. Bakt. und Par.* xi, 1892, p. 95), in which he clearly

demonstrates that several cases of malaria in children, reported by Hochsinger, were not cases of malaria at all. Hochsinger submitted specimens to Paltauf for examination, and he came to the conclusion that in every single specimen where Hochsinger had found plasmodia, he had mistaken blood plates for the plasmodia. I am glad that Dr. Preble brought up the question of staining a fresh specimen of blood. It seems to me it is a dangerous method of examination unless we have an absolutely fresh and carefully filtered staining fluid, and one that we know contains no foreign material. It is certainly wrong to carry about in the pocket a methyl-blue solution for several weeks, then place a drop of the methyl blue on the tip of the finger, prick through that, and thus get a specimen of the blood. Many of these solutions will contain microörganisms, as well as precipitates, and the examination in that way can not be as reliable as by the examination of a fresh specimen of blood.

Dr. H. B. Stehman read a paper entitled

## BOVINE TUBERCULOSIS.

Tuberculosis in cattle has become a recognized factor in the production of tuberculosis in the human family.

The weight of evidence is rapidly accumulating to show that tuberculous food is directly responsible for the transmission of this disease in many individual cases. It is stated that of the mortality of the race 7 per cent. is due to tuberculosis, but the casual observer will readily see that this is but a partial statement of facts, for we all know that many cases with sufficiently pronounced lesions to produce death, are not classed in this category. The nature of many infantile diseases and lesions of important viscera in adults are only too frequently unrecognized. They are treated as inflammations of some sort, when in fact they are nothing more nor less than genuine tubercular affections. The prevalence and fatality of the disease

makes it all the more important that we should discover and if possible prevent the causes and conditions which are active in its dissemination.

It is now admitted that food from a tuberculous animal, whether milk or meat, which has been infected, may produce tuberculosis, and especially is this true in infants, in those greatly prostrated from some febrile condition of a typhoid type and in those cases predisposed to the disease.

The investigations that have been made within the past two or three years, show that tuberculosis prevails pretty generally among our cattle and especially is this the case among our dairy herds. The reports which come to us from different States emphasize the fact that the affection is not limited to any special locality. Herds have been tested in which it was found that as high as 75 per cent. were affected, though this is exceptionable; nevertheless, it is not uncommon to find as many as 30 per cent. so diseased. The statement has recently been made that in the State of California (THE JOURNAL, Vol. XXVI, p. 240) 15 per cent. of the cattle are infected, but this estimate is far above the generally accepted opinion of veterinarians, who tell us that about 5 per cent. of the cattle of this country are tuberculous. In our own herd we found four diseased out of thirty-eight that were tested.

The opinion seems to prevail that the disease is most prevalent among the best bred herds, but the recent reports coming from the New York Board of Health show that of those condemned, the common stock more than out-numbered all the pure breeds (*Country Gentleman* Vol. LXI, p. 231). Tuberculosis

steals upon cattle as insidiously as it does upon human beings; in fact, in its incipient stage, or even when quite far advanced, whether it involves the thoracic of abdominal viscera, or both, physical signs are of little or no avail in making a diagnosis. It is only by the use of tuberculin that it can be positively detected. The disease may involve important viscera to a considerable degree and yet physiologic functions may not be impaired or the nutrition disturbed. It is only by the use of tuberculin hypodermically injected that the affection may be recognized by any degree of accuracy. The experiments at home and abroad have only strengthened the opinion of careful observers on the reliability of tuberculin as a diagnostic measure, and while it may not yet be recognized as an infallible agent, nevertheless the difficulty lies not in the value of the agent itself, but in the lack of experience and wisdom which is necessary to interpret the conditions which follow its exhibition and correctly differentiate them from pathologic or even physiologic symptoms which they closely simulate. The value of tuberculin lies in the fact that its exhibition produces a toxemia which manifests itself in a decided temperature rise where tuberculosis exists in an incipient or moderate state of development, but in those cases where the disease is far advanced no such reaction takes place. Fortunately, however, in those cases the symptoms are so manifest that the lesion may be recognized by the usual physical signs. The best authorities tell us that a characteristic reaction after the administration of tuberculin of two degrees above the normal is proof positive of tubercular infection (Bureau of Animal Industry). It only remains,

however, to ascertain what is the normal temperature of each individual case, for as stated, there are various conditions, such as metritis, pregnancy, heat or handling that may increase temperature and thus modify the value of the initial observations. The temperature is usually taken by the rectum; from four to six observations are made, from twenty-four to forty-eight hours previous to the injection of tuberculin.

The temperature rise occurs from nine to sixteen hours after the inoculation, and if the toxemia is profound we find symptoms such as general weakness, coughing, animal refuses food, coat is rough, breathing is labored, forearms are extended, eyes are glassy, and in thoracic lesions characteristic signs may be easily recognized. In other cases enlarged cervical and mammary glands may also be detected. This temperature manifestation may last with slight variations for a day or so and then gradually subside. In ordinary cases the animal suffers considerable from the intoxication, and in many cases the pathologic changes are increased by the use of tuberculin, so that they pass into a rapid decline.

Where, however, no tuberculosis is present the injection does no harm as was formerly supposed. It was our experience that in the healthy cattle within forty-eight hours all the functions were normal, and in a few days the milk flow was reëstablished. This limited observation is confirmed by a large array of testimony (Pennsylvania Reports), and consequently this objection holds good no longer as an excuse for refusing to try this test. Besides, even though tuberculin is derived primarily from the product of the

bacillus of tuberculosis, it undergoes such changes in course of its preparation that the article we call tuberculin is nothing but a chemic substance, and of course can not originate tuberculosis. Recent reports (State of Iowa) from those who have studied the subject carefully show that tuberculosis is not transmitted from parent to offspring; this observation among cattle has long since been observed in the human family by the profession. The disease spreads among herds either by the indiscriminate housing together of healthy and diseased cattle, or the infection is produced by the the milk fed to calves from tuberculous cows.

The report of the English Royal Commission appointed to investigate this subject, says: "We have obtained ample evidence that food derived from tuberculous animals can produce tuberculosis in healthy animals." It says further: "The ordinary processes of cooking applied to meat which has got contaminated on its surface are probably sufficient to destroy the harmful quality, but it would not avail to render wholesome any piece of meat that contained tuberculous matter in its deeper parts. The boiling of milk, even for a moment, would probably be sufficient to remove the very dangerous quality of dangerous milk." The Commission reports that "while the recognition of tuberculosis during the life of the animal is not wholly unattended with difficulty—nevertheless in most cases it can be detected with certainty in the udders of milk cows." But more recent investigations prove that milk may be tubercular and yet the udder of the cow show no evidence of disease.

Roth (*Mod. Med.*, Vol. IV, 12, p. 314) tested thirty-six cows which showed no evidence of disease

in the udder and in twelve the milk and cream contained tubercle bacilli. Twelve pigs were fed upon the same milk and five became diseased. Twelve out of eighty-eight guinea pigs inoculated with tuberculous milk became tubercular. Of twenty-one calves fed upon the same milk eight became infected.

H. W. Conn (*Hoard's Dairyman*, Vol. XXVI, No. 51, p. 1006) states that recent statistics from abroad show that of 45,000 swine slaughtered for market 11 per cent. were found tuberculous, and that a more careful study shows that of the swine fed at creameries upon the skim milk and slime of the centrifugal machine from 60 to 70 per cent. were found diseased. Further, it has been found that butter made from cream gathered by the separator contains more bacilli than that made from raised cream.

The specimens which I present were removed from the animals slaughtered; you will notice various structures, lungs, liver, diaphragm, pleura, mediastinal, mammary and mesenteric glands, all showing various degrees of tubercular lesion. To me, however, the most gratifying specimens are the small mesenteric glands which scarcely show sufficient tubercular degeneration to be recognized, and yet this is all the macroscopic evidence we could find showing tubercular infection. These specimens were removed from a cow 6 years old, weight 1,100 pounds, Durham. Temperature observation previous to testing averaged 101.6 degrees; the first observation nine hours after injection was 102.6, eleven hours after 104.2, fifteen hours after 105, and then it dropped to 104, varying from this to 103.2 for twelve hours.

The searching quality of tuberculin is most strik-

ingly shown in this test, and it speaks volumes in its favor. For it is evident that if tuberculin will cause reaction in an animal so slightly affected, by its intelligent use one can with great confidence rid a herd of all infectious animals. The specimens showing the extensive distribution of tubercular nodules over the lung and diaphragm illustrates to what degree a cow may be tubercular and yet show little or no constitutional disturbance.

To my mind this was a case of unmixed infection. This cow was a Holstein-Friesian, 8 years, weight 1,100 pounds, well nourished and gave a large flow of milk. Her average temperature previous to testing was 102.3 degrees. Nine hours after injection temperature was 107, eleven hours later 107.2, thirteen hours later 106.2, fifteen hours later 105.2, the temperature gradually receding to 104, where it remained for a number of hours. Previous to the exhibition of tuberculin this cow would not have been thought of as tubercular. There were no cervical glands involved, the udder was normal and upon auscultation the signs were negative. After injection, however, auscultation revealed signs which only could be produced by a pathologic lesion such as I now demonstrate.

DISCUSSION.

Dr. E. R. LeCount—I would call attention to the fact that not only the milk but also the meat of tuberculous cows is dangerous. In certain experiments reported by Strauss the beef from tuberculous cattle which showed nothing wrong to the naked eye, was submitted to the temperature ordinarily used in cooking such meat, and then injected into guinea pigs and rabbits, producing typical tuberculosis in which the tubercle bacilli were found. A mere inspection of the meat, therefore, is insufficient to demonstrate its harmlessness.

PRESENTATION OF CASES AND SPECIMENS.

DR. J. HOLINGER presented three cases of *cholesteatoma* of the ear, with specimens, and discussed them as follows:

*Case 1.*—Twenty years old, was operated upon in fall of 1893. He was treated in the Eye and Ear Infirmary for several months for suppuration of the right ear, the drum of which was vacant, and granulations were removed at several instances, yet the fetid discharge did not become less or thinner. The general condition was very poor. The boy was anemic. He was learning the trade of a plumber but could not work longer than an hour at a time, then became tired, dizzy and had to stop. Since the operation he works steady. The greatest improvement in his general condition was noticed soon after the operation, when two months after his discharge from the hospital his nurse did not recognize him. Now nothing of his anemia that he suffered with from childhood can be proved. His ear stopped discharging and there is only one small moist spot near the Eustachian tube, all the other very large cavity is covered with healthy, dry epidermis, and can be controlled through the external meatus. His hearing was, before the operation, zero for whisper and six feet for conversation. It is now three meters or ten feet for whisper.

*Case 2.*—Patient is 22 years old and was sick since his second year. After three weeks of observation, during which polypoid granulations, and finally the almost entirely loose hammer were removed, and regular syringing of the attic with Hartman's antrum tube did not have any effect whatever on the bad-smelling, thick secretion, which carried considerable masses of epidermoid scales; the operation was performed middle of December. The bone was eburneous, and granulated very slowly. Three weeks after operation the whole wound was covered with Thiersch's skin grafts. During a narcosis of bromid of ethyl Dr. Beard was kind enough to cut the flaps out of the patient's arm, while I removed the granulations from the bone and stopped the hemorrhage. After the patient had recovered from the narcotic the flaps were put in place. The greatest part of them took. I did not succeed, however, in covering the Eustachian tube, in consequence of which you see a small, red granulation back of its opening, the only moist place in the whole cavity. Different experiences of several authors (Profs.

Siebenmann, Betzold, Schwarze), as well as my own, convinced me long ago that the perpetual opening behind the ear is the only operation that is able to prevent these cavities from suppuration and necrotic process, with the final perforation into the skull and meningitis. In this patient the other ear shows a typical cholesteatoma with large scales. But there was never retention or decomposition of secretions or necrosis, therefore I did not operate there. The hearing distance on the operated ear was two feet for conversation, now it is one foot for whisper. The ear that was not operated upon was the better one before, and had a hearing distance of five feet for conversation.

*Case 3.*—Wm. M., 17 years, came to my observation in Post-Graduate Medical School two weeks ago. I removed a large polypoid granulation from the posterior upper margin of the drum, which was vacant with the exception of a narrow adhesion that connected the mallet to the anterior wall and the promontory. You see now the white epidermis distinctly descending the promontory. It is only the neighborhood of the Eustachian tube that it does not cover yet. There you find a few granulations. The other middle ear of the patient is entirely covered with epidermis, which you can see through a big perforation of the drum. The rest of this membrane you see back and in front of the displaced mallet. The hearing of both ears of this patient is very poor, only four feet for conversation. The specimens are temporal bones, for which I thank Dr. Hektoen. I performed there the regular Zaufal operation, as I did it in these cases. One shows the operation before its most dangerous step, the removal of the bridge between antrum, external meatus and middle ear. The other one after this, and opens a free view into the middle ear, attic with ossicles, antrum. In all cases of cholesteatoma, however, the conditions are not as clear as in the normal, and then you have to make your way without antrum in the hard bone, and avoid the facial nerve, which takes often considerable knowledge of anatomy of the temporal bone.

Dr. L. L. McArthur—*1. Fibroid Tumor of the Scrotum.*—A patient came to my office not long ago with a tumor of the scrotum for the purpose of having it aspirated. Clinically, the tumor presented the conditions which obtain with a hydrocele.

The tumor was firm, small above, large below, smooth in outline, and quite fairly elastic, yet harder than it seemed possible for a hydrocele to be. It was not translucent either to sunlight or the electric light; therefore I made a hypodermic puncture before resorting to aspiration, finding that the needle went into a solid growth. The patient was sent to the hospital for its removal, the nature of which could not be determined prior to operation. By manipulation it was free from the testicle and lying above it, extending from the external inguinal ring to the bottom of a rather large scrotum. The specimen has wasted about 25 per cent. in size through the influence of alcohol. The cord ran down on the inner aspect of the tumor. On cutting through the tissues of the scrotum as one does in hernia, the various layers were recognized, and it was seen to come down upon the peritoneum. On opening the peritoneum I found a hernial sac in which lay a tumor which had but one small adhesion on the inner aspect of the tumor; that is, the finger could be swept completely around the tumor except on the inner aspect as it lay in the scrotum, and the index finger could be readily carried through the inguinal ring into the abdominal cavity. There was no history of a change in size from position. There was no history of intestinal or mesenteric contents coming down into the hernial sac. On studying the adhesion which existed on the side of the growth mentioned, it was found to have, after cutting through the peritoneal wall which covered the tumor, a connection with the vas deferens as near as could be made out. The patient says that it was always larger than the opposite side, but that in the past nine months prior to operation, it had increased and become painful. As the tumor had somewhat the characteristics of a fibrosarcoma, it was decided to resect the vas deferens and remove that portion which was attached. This was done.

Microscopic examination of the growth proved it to be a fibroid tumor which seemed to start from the vas deferens and filled the hernial sac. It was a hernial content. The peritoneum was resected up around it, especially the part which folds around the testicle in its descent and makes the tunic. The patulous character of the inguinal canal made me believe it to be a congenital growth, and the continuation of the peritoneum with the bursa of the testis showed that that was prob-

ably true. A small portion of the peritoneal sac was ligated off to make a normal bursa over the testis. A ligature was applied to the distal end of the vas deferens to prevent the escape of seminal fluid. The patient made a good recovery.

2. *Cyst of the Appendix.*—The next case is one that occurred in the practice of Dr. Frankenthal, of this city, and a relative of his family. A young man of 25 had been having for three years repeated attacks of appendicitis which were typical in character, and were usually caused either by excesses or carelessness in the selection of diet. I was called twice during the past three years to see him on account of these attacks and advised non-operative interference because while the symptoms were fairly acute, they were not alarming. His temperature would range between 100 and 103; the pain was fairly well marked, and an elongated tumor could be distinctly felt. He recovered from his first attack and by being careful in his dietary had none for a year and a half. He had a second attack, after which he paid more attention to his diet and a long time elapsed before he had another attack. Finally, about six months ago, he had a third one, when it was decided to remove the appendix after all the inflammatory symptoms had subsided. Each attack was followed by a rise of temperature, the thermometer often indicating 103 with acceleration of the pulse and the formation of a tumor. In operating, much to my surprise, I found an elongated appendix, five inches in length, markedly distended. A tumor was to be felt before operation which seemed to run down into the pelvis, and it was about the size of an ordinary Frankfort sausage. It was firm, elastic and translucent. Its contents, when allowed to escape, consisted of clear, glairy mucus. It was simply a mucous cyst of the appendix. I present it to you, not that such cases have not been found before, for there have been some reported, yet they are not numerous, but because it seems almost inexplicable how he could have had a temperature as high as he did ranging over a period of ten days without any pus or suppurative process. I can not conceive of his having had a suppurative process in his appendix, and then having it disappear, leaving nothing but a clear mucus. There were no adhesions in this case. The appendix, which was elongated and hanging down in the pelvis, was movable in the

abdominal cavity and showed no attachments to either the mesentery or other intestines. Its neck was totally obliterated.

Dr. Ludvig Hektoen.—It will be remembered that Dr. Van Hook (*Medicine*, March, 1896) described a strangulated inguinal hernia of the vermiform appendix. In the literature he found twenty-nine cases of cystic dilatation of the vermiform appendix; to this number he adds his own case, an unpublished case of Treves and one that came under my observation, making the total number of cases thirty-two. This small number shows the comparative rarity of cystic appendix.

The pathologic condition in Dr. McArthur's specimen, as well as in many other similar specimens, is undoubtedly a partial obliterating appendicitis with consecutive distension of the distal part by the accumulating products of the mucosa and the inflammatory vascular exudation during recurrent attacks of appendicitis, the regional lymph glands being unable to absorb the contents of the cyst because of chronic indurative lymph-adenitis, or because the lymphatic vessels are constricted at the cicatricial closure of the appendiceal lumen, which point is well marked in Dr. McArthur's specimen by the circular constriction near the proximal cut end. This specimen, taken in conjunction with the clinical history, demonstrated conclusively that there may be a partial obliterating appendicitis with consecutive cystic dilatation of the appendix.

Dr. E. R. Le Count—I would suggest as a possible explanation for the fluid in the cyst, that the obliteration not only affected the lumen, but that the inflammation shut off the blood vessels on the outside of the appendix, causing an edema of the tissues.

## Regular Monthly Meeting, April 13, 1896.

Dr. James B. Herrick, Vice-President, in the chair.

Dr. Arthur R. Edwards read a paper entitled

# CLINICAL MEMORANDA.

### I. CASE OF CIRRHOSIS OF LIVER WITH PRE-ASCITIC EDEMA OF LOWER EXTREMITIES.

J. A. N., a laborer, married, 43 years old, American; under observation from Jan. 25 to Feb. 6, 1895. By occupation he was an engineer. His affection began two weeks before entrance, with an initial chill, with pains over the entire body, in every joint and in the head. He had during this period suffered from hourly vomiting, and frequent diarrhea. The bowels had been usually constipated. Hiccough had troubled him excessively. His wife stated that the patient's illness began suddenly with involuntary evacuations from the bladder and rectum, accompanied by an enormous appetite and thirst. His left arm had been limp and painful for some time past. The lower extremities, together with the other parts, have grown emaciated till some six days since, when considerable anasarca about the legs and ankles developed. He had always lived in this State. He married a year ago. His wife noticed large veins in the legs, but had never seen any upon the abdomen.

Examination: Involuntary urinary and fecal evacuations existed with retention of urine, 4,100 c.cm. of urine being withdrawn at one time. The urine contained no albumin nor sugar, was neutral, sp. gr.

1013, 2.3 per cent. urea, no pus nor casts in the sediment. Respirations varied from 18 to 20, the pulse from 80 to 90, and the temperature from 98 to 101 in axilla. He vomited frequently. Rectal examination was negative. Upon the trunk and lower extremities appeared an eruption of erythema nodosum, upon which basis bullæ later developed. His legs and feet were much swollen. Upon both legs and over both inguinal and hypochondriac regions were observed very large, extremely tortuous veins. The eyes and discs were negative. The blood examination showed no changes in stained specimens. Sordes existed upon teeth and lips. The lymphatic system, the bones and muscles were negative. The heart was not enlarged in any direction, the first tone over the apex being weak, and the second aortic tone was considerably accentuated and transmitted into the cervical vessels. No murmurs were obtained. The radials were not hard and the pulse was 90, regular and compressible. Marked pulsation existed in the jugulum and supra- and infra-clavicular regions. The second pulmonic tone was questionably accentuated. The lungs were tympanitic laterally and anteriorly, no râles were heard in front, respiratory excursion was demonstrated on both sides, although it was hard to get the patient to breathe deeply. Over the lower lobes behind, hypostasis was diagnosed from the presence of inspiratory râles and relative dullness. The liver on percussion lay within the usual limits, except that tympany existed over the location of the entire left lobe. The spleen was indeterminable on palpation. No free fluid was found in the peritoneal cavity. Rectal examination was negative. The umbilicus presented

no changes. There was no icterus. Marked delirium, slight cyanosis toward the end, emaciation, and a subnormal and even collapse temperature were noted. The genitalia were hyperemic and slightly eroded by the ammoniacal urine.

The prognosis from the first was absolutely unfavorable, and the therapy of free stimulation, alcohol and supporting measures were wholly unavailing. The case is, therefore, presented wholly for its diagnostic and pathologic phases.

Diagnosis: An arterio-sclerosis with secondary cardiac hypertrophy having been diagnosed, there was still an underlying disease which threatened life. The findings were few and the chief interest centered in the greatly dilated veins in the abdomen and legs, which obviously indicated obstruction. The argument, diagnostic and pathologic, was to my mind most interesting. Was the obstruction intra-thoracic? The venous ectasia was rather too low to favor this construction. Was then the return venous flow impeded in the vena cava or in the portal vein district? No cause could be invoked for the theory that the cava was compressed; there was no tumor, no inflammatory focus, etc., hence attention was directed to the liver. There was no real jaundice, no ascites and no splenic tumor; yet knowing that a free collateral circulation may prevent or succeed in time a hepatic cirrhosis, and that the passive congestion of cirrhosis may in exceptional instances antedate the ascites, the antemortem diagnosis of hepatic cirrhosis was made (in the presence of the late Dr. D. D. Bishop, Dr. Stout, Dr. Skinner and Dr. Hardie).

The necropsy findings were in brief: Kidneys,

10 x 6 x 3.5 cm., 10 x 6 x 3 cm., 300 gm.; surface slightly roughened; capsule freely separable; showing no marked naked-eye changes; microscopically, some slight arterial alterations and inconsiderable islets of connective tissue change were observed. The heart weighed 420 gm.; the left ventricle was 20 mm. thick and the aorta was somewhat atheromatous. Lungs: Some few adhesions in the right pleura; moderate marginal emphysema; mechanical hypostasis. Spleen: 170 gm.; very marked perisplenic changes, explaining the inconsiderable size of the organ compared with liver. Liver changes: 28 x 18 x 18; 5 x 8 x 6 cm., 2,000 gms.; surface smooth, no adhesions; porta free; the organ was universally red; the lobules were centrally fatty and in their periphery exhibited delicate strands of connective tissue. Microscopic examination revealed a typical fatty alcoholic cirrhosis without any striking anomalies. The gastro-intestinal tract was negative. The peripheral veins conformed to the clinical signs. The vena cava was not compressed, not involved in any cicatrix, not the seat of any thrombosis, etc. The subperitoneal veins, especially in the right inguinal region, were varicose even to bursting. The clinical diagnosis of a latent hepatic cirrhosis, with collateral circulation sufficient to obviate ascites and splenic tumor, was confirmed.

Labadie-Lagrave states that pre-ascitic edema of the lower extremities may appear as an initial or as an almost isolated symptom of cirrhosis. It was first described by MacSweney in 1876, then by Giovanni, by A. Gilbert and H. Presle (Thèse de Paris, 1892). While edema as a rule accompanies or follows the ascites, it may antedate the appearance of ascites

by months, even 1½ years. When it accompanies the first cirrhotic symptoms, it is a sign of diagnostic importance.

It may occur not from portal vein stasis alone but from cicatrices around the cava, cachexia, heart or renal complications.

Thierfelder believes the occasionally earlier appearance of anasarca before ascites is often more apparent than real, since edema is better seen by patient and physician alike. Such edema may be due to meteorism or fluid pressing upon the cava or iliac veins. Bamberger explained edema of the lower extremities in isolated cases by the fact that the pars hepatica of the cava inferior suffered contraction by shrinking of the cirrhotic liver.

However, I am convinced that none of the enumerated causes operated in this concrete instance. The great collateral circulation opened channels of communication between the vena porta and venæ epigastricæ, by means of which the blood flows from the latter to the venæ crurales and produces an edema of the lower extremites before a great degree of ascites is present. Monneret has described an instance in which, by the mechanism suggested, the overfilled epigastric veins produced edema of the abdominal walls.

### II. CASE OF ASCITES CHYLOSUS.

The following case entered the service of my friend Dr. Worthington, by whose courtesy and that of Dr. F. A. Besley, I was enabled to study the case clinically and report it. I performed the postmortem in the presence of Drs. Worthington, Besley, Olney, Wood and Richter.

The case presented no remarkable clinical features but details are in place because of the rarity of the complicating chylous ascites.[1] The patient aged 32, married, of American descent, barber by trade. Under observation two months. The family history was negative beyond the death of a sister from gastric tumor. The patient had a diarrhea for past seven or eight years which recurred several times a year, each time lasting three or four weeks, amenable to careful dieting. Three weeks before entrance, he had a severe chill with fever and suffered severe pain in the left side. He coughed and expectorated freely. No hemoptysis.

Physical Examination: Mind clear; eyes negative; tongue coated but moist; pharynx, ears, scalp, calvarium negative. Lungs: On both sides there was flatness below, reaching as high up in axilla as level of nipples; there was also absent or greatly diminished breath sounds, greatly decreased vocal fremitus, distant crepitant and subcrepitant râles; at level of flatness was bronchophony and above it were an increased percussion note, exaggerated breathing and a few râles. No respiratory excursion existed on either side. Cardiac percussion gave a triangular shaped area of dullness, with its apex directed upward, its sides, which diverged downward, passing wide of the sternal margins and fusing with the dull areas on either side. Over the basis was heard a to-and-fro murmur which was simplified into a systolic murmur at the apex. The murmur was a typical friction rub. The cardiac action was visible only in the second and third left intercostal spaces. While

1 Edwards, Ascites chylosus s. adiposus, "Medicine," August 1895.

the pulse was full yet the heart tones were very distant. The liver dullness merged with that of the lungs, indefinable above but reaching three inches below the normal lower limit of hepatic dullness. Spleen not palpable. Great abdominal meteorism, but fluid could not be positively affirmed, although considerable effort was made to find it, since the abdomen was prominent. One week prior to death, free fluid was demonstrated in the peritoneal cavity. The pleural cavities were each tapped three times, and clear yellow serous fluid of sp. gr. 1013 was obtained. The pericardial sac was also tapped in the fourth left intercostal space, and a sero-sanguineous fluid withdrawn with a sp. gr. of 1021. The temperature curve was irregular, remittent in type, with apyretic intervals of variable duration. The pulse was uniformly high, as was also the respiration rate. The patient was treated with guaiacol, malt and cod liver oil, and later, whisky, strychnia and digitalis were added. Diuretin and potas. acetate were also employed as diuretics. The urine was negative. The clinical diagnosis was: 1. Effusive pericarditis, probably tubercular from the hemorrhagic character of the exudate and the cachectic condition of the patient. 2. Pulmonary compression from double hydrothorax (no bacilli were found clinically). 3. Liver of passive congestion. 4. Hypostatic edema and ascites. The clinical diagnosis was confirmed in every respect except regarding the interpretation given the ascitic fluid which was chylous and not purely serous.

Postmortem five days after death: Slight postmortem lividity; no rigor mortis; nourishment fair;

pericardium contained three ounces of a bloody serous fluid; the two layers were covered with shaggy fibrinous flakes; both leaves of pericardium were rough and, where not rough, edematous; the exudate was one-fourth to one-half inch thick over the heart. The endocardium was wholly negative, both parietal and valvular. More careful examination of the deeper layers of the exudate revealed innumerable small tubercles, and upon the diaphragmatic surface of the pericardium was a large solitary tubercle as large as a walnut. The myocardium was pale, firm and, nearest the pericardium, edematous.

The peritoneal cavity was full of a malodorous, milky fluid which contained some few yellow flakes. The peritoneum was smooth and glistening throughout its entire parietal and visceral expanse. Stomach and intestines negative. Diaphragm reached to the sixth rib on the right side and to the eighth on the left. Appendix free from adhesions. The liver was fully a hand's breadth below the costal arch; its edge was rounded and its markings fairly distinct. In the left pleural cavity were some few firm adhesions with an eruption of miliary tubercles on the diaphragm. The right lung was free, crepitated feebly above and the lower lobe was devoid of air. Firm adhesions over left upper lobe, lung crepitates feebly, lower lobe airless. Spleen 18 x 4 x 15, soft, flabby, friable. Kidneys, dark in color; capsule peels readily; cortical markings distinct.

Anatomic diagnosis: Chylous ascites; hydrothorax and pleuritis; pericarditis effusiva tuberculosa; parenchymatous degeneration in the liver and kidneys; splenic tumor.

I have lately misplaced the record of the chemic analysis, but fat was present in traces. There was a very slight but distinct sugar reaction, while albumin was present. Microscopically, the fluid was teeming with bacteria on account of the late date of the autopsy and leucocytes bearing granules were sparsely scattered through the sediment, together with amorphous granular masses. The case must then be included in the class of chylous ascites, the number of which is very small, since scarcely a dozen cases are recorded in which sugar was found. Cases of chylous ascites are indisputable when 1, macroscopie rupture of the chylous tracts, 2, microscopic rupture of the same are demonstrated, and 3, when sugar is found. In the genuine chylous ascites, rupture may occur anywhere in the chyle system. The return chylous flow may obstruct anywhere from the smallest to the largest vessels.

However, in the case reported no such rupture nor obstruction could be demonstrated, if we except the obvious impediment to the chyle and vascular flow, the pericarditis and the myocardial inadequacy. The presence of sugar, when diabetes is excluded, is proof positive of chylous ascites.

Our explanation of the chylous effusion is the following: The cardiac power was reduced by the infiltration of the myocardium, per contiguitatem, from the inflamed pericardium. As evidence, we note the edematous subpericardial portion of the heart's musculature. A second cause of reduction in the heart's efficiency resides in the compression of the viscus by the pericardial exudate, which explains the pallor of the myocardium on section. The cardiac

obstruction was reflected peripherally into the venous system, hence the synchronous cessation of the normal centripetal chyle flow. Serious stasis in the distal chyle vessels resulted with final attenuation and rupture of their walls.

It is highly probable that the ascites was primarily serous and became only later chylous. There are some seven instances of this transition on record. The nature of the fluid was in this, as in other instances, a postmortem surprise, but never has chylous ascites been diagnosed before death or paracentesis, since there are no infallible, nor indeed even highly suggestive, diagnostic signs. Its proper recognition would have necessitated a prognosis even graver than that of a tubercular pericarditis, but it could in no wise have had any therapeutic value.

103 State Street.

DISCUSSION.

Dr. Herrick—I should like to ask Dr. Edwards if there is not but one other case or at least very few cases in which cardiac obstruction has produced chylous ascites?

Dr. Edwards—I think there are more than that. Dr. Busey, of Washington, wrote an article on the subject in which he thought there were a number of cases where, for instance, a tricuspid lesion or a secondary endocardial lesion, or even a lung obstruction which would affect the right heart caused chylous ascites; but they are relatively few, and I think there were only three authors, Niemeyer, Busey and one other who called attention to that point.

Dr. Burgess—I will confine myself to the description of a case of cirrhosis of the liver which I have recently seen, which also had unusual vascular disturbances of the liver itself. I never saw the patient during life, but I understand that the first that was known of him was that he had some attack of heart trouble and an examination revealed that he had a myocardial lesion and also had a systolic venous pulse; at this time

there was some anasarca, and the liver dullness in the vertical direction was much increased, about six inches, and on depressing the abdominal wall the liver could be taken in the hand and pulsation felt. Care was taken to exclude all communicated pulsation, and the diagnosis was that there was a pulsation in the liver itself, in the substance of the liver. The case went on and finally a great deal of ascites developed, and that is about all I remember of the clinical history. At the autopsy the liver was found in an advanced state of cirrhosis. It was smaller than normal; the well-known ax-shaped liver was present. The condition of the heart was, that there was a competent pulmonary and aortic valve, with incompetency of the tricuspid and mitral valves; the ascending vena cava was very much widened; the veins which empty from the liver were very much widened and in passing a stream of water from the tap into the liver it could be seen distinctly to swell out, and then on squeezing out the water, which was not a great amount, and repeating the process the same thing happened over again; so in this case the pulsation of the liver was marked enough to be well felt, and of course was due to the pulse of the right ventricle going through the tricuspid, which was incompetent.

Dr. Wiliam Hessert read a paper entitled

## CEREBRAL SYPHILIS, WITH REPORT OF CASES.

I need offer no apology for the introduction of a subject such as this, as it is well deserving of our attention by virtue of its high degree of importance in diagnosis and treatment. The frequency of syphilis of the nervous system is becoming more and more appreciated, thus securing for it an earlier recognition and the establishment of a more definite train of clinical phenomena than formerly. Gray, writing only four years ago, would make no more than a tentative diagnosis of cerebral syphilis, unless there were present, 1, undoubted specific infection; 2, con-

vulsions or hemiplegia, or 3, marked success of specific treatment. Gowers, in his great work, allots to nervous syphilis no special chapter, referring to it among causative agents in the production of endarteritis, cerebral softening, hemorrhage, insanity, etc. I need not dwell upon the widespread prevalence of syphilis, which is one of the most important diseases with which we have to deal. Additions are made daily to the already enormous literature. How many of these cases of syphilis have undergone treatment which can be called approximately curative? Those that submit to the proper régime are certainly in the minority. Only too many of them are lulled into a state of false security by the rapid disappearance of tangible evidence of the disease, and discontinue treatment despite the admonition of the medical attendant.

A chancre of doubtful nature heals under indifferent treatment, or perchance is cauterized; no "secondaries" follow, leaving the individual in doubt whether he is syphilitic, until a subsequent nervous affection is undeniable evidence thereof. Fournier says that just those cases in which the manifestations on the skin and mucus membranes are scanty or absent, are prone to be followed by nervous lesions later on. Especially does this seem to obtain in women, who also are often infected unknowingly, a circumstance which provokes distressing errors in diagnosis, especially among the better classes.

On the other hand, a conscientious course of treatment for one and one-half to two years or more does not necessarily insure immunity from further trouble. Recognizing, then, the ubiquitous nature of syphilis, we should ever be on the alert in cases of nervous

especially cerebral, disease, to establish a possible etiologic connection. It will appear that an *early diagnosis of these cases of cerebral syphilis, before irreparable secondary changes have been wrought, is of incalculable importance.* After secondary degeneration and softening have become manifest, treatment will avail but little, and can not be compared to the success achieved in cases where the alterations are limited mostly to the membranes and arteries. It is for us to heed the warning note that is sounded by the appearance of prodromal headaches, irregular palsies of cranial nerves or slight aphasia, and not wait until a greater calamity overtakes the patient.

A maxim to which I heard Max Joseph, of Berlin, allude is a good one, *ubi dubio, suppone luem*, and safely applicable in medicine generally, as it can do no harm and may be the key to the solution of a perplexing problem in diagnosis. Various well defined types of nervous disease, foremost locomotor ataxia and dementia paralytica, are said to occur with relative frequency following syphilis. Storbeck, of Leyden's clinic, has recently published a table showing the percentage of syphilitic cases in tabes according to forty-eight authors, from the 0 per cent. of Mayer to the 97 per cent. of Déjerme. In his own cases (108) about 30.6 per cent. had syphilis, which he thinks is not higher than might be expected from the frequency of the disease. Leyden is loth to admit any causative relation between syphilis and tabes. The relation of cause and effect in these cases has thus far been only statistical and not based upon pathology, nor supported by the results of treatment.

The cases to which I will refer are due to a direct

involvement of the brain and its investments by the specific proliferative changes. These changes are the same in the brain and cord and cause outward symptoms in so far as they produce local anemias with their sequelæ or interfere with nerve conduction by pressure. The nervous involvement of syphilis is usually classed among the late manifestations, yet it has been known to follow infection from a few months to thirty years thereafter. According to Naunyn, nervous syphilis occurs most frequently during the first year following infection, and decreases year by year thereafter. Many cases have been reported of late, occurring within the first year and during the period of efflorescence (J. Huchinson and G. F. Lydston). Most cases, however, develop after the lapse of several years. I will say that the tendency now is such as to disregard the arbitrary division of syphilis into "secondary" and "tertiary" periods, since the manifestations thereof are found to intermingle to a degree not consistent with any such classification.

Age is variable, averaging 30 to 35, youthful individuals being more often stricken, and males preponderate. To Sternberg (1860) and Heubner (1874) belong the honor of having first identified certain cerebro-spinal meningitic and arterial changes with syphilis. Save minor details their works still enjoy acceptance. Rumpf also asserts that syphilitic disease of the nervous system originates primarily in the blood vessels.

Syphilitic lepto-meningitis, like the tubercular, is prone to affect the base of the brain, about and posterior to the optic chiasm, whence it spreads to the convexity. Separate foci in different stages of devel-

opment may coexist. The pia and arachnoid are primarily involved; as they span the interpeduncular space they appear thickened, opaque and pultaceous. The mass is granulation tissue, which becomes fibrous, sometimes cheesy. The membranes adhere to the cortex, which suffers to a variable degree. The new growth fills out the sulci, thereby smoothing the markings of the convolutions. The cranial nerves and cerebral arteries traversing these masses can not escape involvement, but they are often independently affected. The nerves are infiltrated with round cells producing nodular gummatous thickenings; eventually nerve atrophy occurs. Owing to their situation the optic, third and sixth nerves are first to be attacked, the others escaping more or less.

The arterial changes are those of an endarteritis obliterans; the intima becomes enormously thickened by the growth and organization of round cells, which invade to a lesser extent the other coats. There results progressive narrowing of the lumen and eventually complete occlusion of the same by the cell growth or by thrombosis. As in the nerves, small gummosities occur in the vessel walls. Aneurysms and hemorrhage are uncommon, thrombosis being the most frequent event. Section of the brain sometimes reveals no changes save the arterial. There is never any pus formation and gummata in the interior are infrequent. The effects, secondary and remote, produced in the central ganglia and internal capsule are of vital importance. The arteria fossa sylvii, which supplies motor regions of vital function, is commonly involved by endarteritis. By the narrowing of the lumen, aided by the varying degree of blood pressure,

there are produced vacillating states of anemia, until finally occlusion by a clot produces ischemia in areas of variable size with resultant monoplegia, hemiplegia or aphasia. These latter, rarely hemiplegia, are also evoked by pressure of meningitis overlying motor centers; convulsions may then precede paralysis. If the deprivation of blood be not soon relieved by collateral supply or perviousness of the thrombus, softening with its sequelæ is inevitable.

All writers agree upon certain factors which enhance the tendency to nervous involvement. These are inebriety, venereal excesses, emotional disturbances, worry and overwork; sometimes trauma to the skull.

The character of the pathologic lesions, manifest by their insidious, vacillating and irregular growth and regression—the simultaneous involvement of widely separated areas—the far-reaching influence of impeded blood supply—all these elements obtain in determining a clinical picture of varying aspect. This irregularity, however, is one of the points of identification, together with phenomena which are uniformly constant. Headache is among the first forerunners, often nocturnal and periodic and frequently localized. Its severity may reach an agonizing degree, accompanied by great sensitiveness to percussion of the skull. The cephalalgia may be accompanied by nausea, vomiting or vertigo. This may be the only complaint for weeks and months, even years, until superseded by the first signs of paralysis. There is usually an early psychic involvement, evinced by a change of character, the individual becoming moody, morose, sullen and hypochondriacal. He is, too,

drowsy by day and wears a stupid sleepy look, but is restless and wakeful at night. The keen intelligence is blunted and the memory fails; he shuns society suspiciously. Sooner or later an inability to read and write is noticed and finally the first signs of paralysis appear. It is claimed that with the onset of paralysis headache and vertigo subside.

The palsies are very various, from a paresis of an ocular muscle to complete hemiplegia. Aphasia is frequent and may be the only motor disturbance. The speech, at first irresolute and halting, resembling paralytic dementia, finally becomes inarticulate and the function is completely suspended. The meaning of words is understood, as the aphasia is of the motor type.

I have already referred to the early affection of the optic, oculomotor and sixth nerves, less frequently the fifth, seventh and others. The optic disk reveals neuritis varying from a reddening and blurring of the contour with venous engorgement and swelling of the papilla, to complete atrophy, with a tendon like aspect of the nerve. Vision may be much reduced, and hemianopsia bitemporal or bilateral and diplopia also occur. Oppenheim calls attention to the fleeting and transient nature of the subjective eye symptoms, especially the hemianopsia and contraction of the field of vision. The pupils may be sluggish and unequal and not react to light nor accommodation. Ptosis and strabismus are very common, more so than facial paralysis. The tongue is protruded to the side and the uvula is drawn from the perpendicular. Deafness is rare. These paralyses are often so disposed as to defy localization at one focus. The graver forms of paralysis, monoplegia

and hemiplegia, may be of sudden apoplectiform onset or may develop after hours or days. Consciousness is usually retained, the patient experiencing the more or less rapid loss of power in his limbs. Death during such an attack is not the common outcome, but convulsions and coma are usually fatal. Polydipsia and polyuria occur in some cases, also atony of the bladder and rectum, generally transient. Paresthesias and anesthesias occur where sensory tracts are implicated. Fever is usually absent, although there may be some rise in temperature.

The course of the disease depends largely upon the gravity of secondary changes at the time of commencing treatment. Some cases continue for months or years with only headache or slight mental alteration, perchance paresis in the distribution of some cranial nerve. Others progress rapidly to convulsions, dementia and coma. Some are stricken with hemiplegia, terminating in contractures and atrophy. There may be periods of quiescence, but relapses are possible.

*I can not too much emphasize the enormous importance of an early diagnosis, upon which the whole future of the case hinges.* If recognized and treated early, the outlook is generally good but becomes progressively worse the later treatment is begun. According to Naunyn the prognosis is favorable during the first four weeks of the disease, and after the commencement of treatment, the bulk of improvement will have occurred by the end of the second week thereof. These are two valuable points to bear in mind when rendering prognoses.

The success of treatment is entirely dependent upon

the amount of damage done to nervous substance secondary to the development of specific changes in membranes and arteries. If limited to these latter complete recovery can be assured. If the granulations be by treatment brought to absorption before the secondary alterations are of long standing and permanent, restitution is probable. Buzzard tells of an artery that had been almost occluded, tested by the sphygmograph, and yet it was again made patulous by proper treatment. Irreparable degenerative processes in brain and nerves, with muscular degeneration and atrophy can not be much improved.

We should be suspicious of the presence of brain syphilis under the following conditions:

1. Headache, periodic, nocturnal or localized, accompanied by nausea and vertigo, or the development of mental symptoms described above.

2. Isolated irregular paresis of cranial nerves, especially the third, preceded or not by the above or accompanied by aphasia, alexia and agraphia.

3. Hemiplegia, in youthful individuals occurring slowly or sudden, with no loss of consciousness.

4. Coma and convulsions—excluding opium, epilepsy, alcohol, diabetes, uremia and trauma—extending over days.

Naturally, our suspicions are confirmed by a clear specific history or the simultaneous appearance on skin or mucous membranes of typical lesions.

Is complete recovery possible? Mills says "it is possible to remedy some of the effects of nervous syphilis or to remove some of its symptoms; it is even possible that a cure may be affected; but this, as Gowers asserts, has never been proved." The fal-

lacy of this statement is evident and shown by cases reported by Gray, Althaus, Lydston, Diller, Huchinson and others. Three of my cases recovered completely; one was greatly improved when last seen; one, seen late in the disease, died; one is still under treatment, much improved. I believe that if the proper conditions before mentioned are present, that a speedy and absolute recovery can be secured in a large majority of the cases but that a relapse, as Fournier says, is possible, unless treatment be continued at least two years.

The treatment is that of a syphilis in general, but should be vigorous and the remedies should, when necessary, be pushed to the limit. The "schools" are divided on the relative merits of mercurials and iodids. Gowers claims that on the whole the iodids are the most useful and certain of the two. This opinion is upheld in America generally, and enormous doses of iodids are given, an ounce or more of iodid of potash in the twenty-four hours. Germans rely more on inunctions of mercury, but all use the "mixed treatment." I agree with Lydston as to mercury "first, last and all the time." His suggestion, however, as to its mode of application is as unique as it is impracticable, viz., to rub the patient's scalp and neck with blue ointment so that the seat of trouble may be sooner reached and more directly! This suggestion is totally at variance with the teachings relative to the absorption of mercurial ointment. The opinion has spread, based on experiments of Lewin, Müller, Joseph and others, that most of the mercury applied to the skin is in reality absorbed by the lungs, the lesser portion finding access directly through the

skin. It is sufficient to apply the ointment without any rubbing, avoiding the hairy regions of the body. Spread upon cloths and hung up in syphilitic wards, patients therein recovered from milder symptoms without any other treatment, meanwhile excreting abundant mercury with the urine.

The cases to follow were treated with one drachm of unguentum hydrargyri and a drachm more or less of iodid of potash daily. In all of the cases, except the female, the question of syphilis is positive. Collectively they illustrate most of the variations of the subject under discussion and are typical cases of their kind.

*Case 1.*—Male, age 28, chancre eight years ago. Aphasia, slight dementia, agraphia, alexia, unequal pupils, paresis of lower facial; recovery in four weeks.

The chancre, eight years since, healed under indifferent treatment and had no characteristics of syphilis. No eruption nor sore throat followed. Five years later had a periostitis of sternal end of left clavicle. The present illness began with change in character; he became sullen and morose, walked the floor nights on account of headache and insomnia, whereas by day he was sleepy and would doze during conversation. After a few weeks an alteration of speech became apparent, it was slow and halting, finally becoming inarticulate. It was then found that he could not read nor write. Pupils reacted sluggish, right dilated; slight paresis of right lower facial branches; uvula deviated to left; tongue in median line. No sensory disturbances. Treatment was at once instituted, after three days its effects were apparent, and at the end of four weeks all signs had disappeared except an impairment of the mental faculties, which remained somewhat dull and lethargic. For six months he used inunctions and ever since he has taken iodids off and on. At present, after nearly three years he is apparently perfectly well, does office work but is still eccentric. At no time during his disease were there any palpable signs of of syphilis other than the nervous. In this case the menin-

gitis affected chiefly the speech center, to less extent the base.

*Case 2.*—Female, married, age 43. No specific history; nocturnal headache and vertigo very severe for four weeks; then left hemiplegia and optic neuritis; recovery almost complete in three weeks.

This patient had five healthy children, two still births; youngest child about eight months old and healthy, Denies infection. No previous illnesses. Began four weeks ago with severe headache, worse at night, located in vertex and right temporal region; vertigo, vomiting and general malaise. Then she developed a left-sided hemiparesis, coming on in the course of a few hours with consciousness retained. Unable to walk, left hand grasp feeble, face somewhat drawn to right, sensation on left side impaired. No convulsions; speech unimpaired; pupils equal and react. Had complained of dimness of vision for few days previous; neuro-retinitis right side. Great sensitiveness to percussion over right temporal region. Treatment begun immediately after onset of paresis. Headache gone on third day and great improvement after one week. In three weeks muscular power almost restored, sensation returned; no headache; neuro-retinitis abating. She was feeling very well and passed from observation. Subsequent history not known. She also, when seen, had no signs of syphilis, but the character of the illness was highly suspicious of syphilis and was corroborated by the brilliant results of anti-syphilitic treatment.

*Case 3.*—Infection seven years ago. Complete right hemiplegia and aphasia without loss of consciousness; polydipsia and polyuria; complete recovery.

Patient was a male, age 42; acquired syphilis seven years ago; had slight eruption and sore throat. Was treated for eighteen months with inunctions and pills of protoiodid of mercury with iodids. He considered himself cured and took no treatment since. Patient is addicted to excesses in alcohol, tobacco and venery and owing to the speculative character of his business his nerves are continually on a high tension; he is of a violent and excitable temper. Returning home late one night after a turbulent celebration in honor of an important business transaction, he suddenly felt a sense of weakness in right side of body and tottered to the nearest support. He

had had no headaches recently and was feeling as well as usual. He did not fall to the floor nor did he lose consciousness. After regaining his composure he found that he was not completely paralyzed, and a physician who saw him soon after was able to get a history from him. He also complained then of a headache on the left side. Next morning paralysis and speech worse, and in the afternoon, about eighteen hours from time of onset the condition was as follows: Complete motor aphasia; right pupil larger than left, reaction sluggish; tongue protruded to right; complete right hemiplegia and impairment of sensation. Atony of the bladder and rectum. Sensorium in a somewhat dazed condition. Knowing absolutely his previous venereal history, he was immediately put on antisyphilitic treatment and improvement progressed after the second day. After two weeks speech was normal; he could walk with support, sensation slightly blunted, flexes fingers and moves arm slightly. Sensorium clear, sleeps well, no headache; has great appetite and thirst, and voids large quantities of urine, which contains no albumin nor sugar. After four weeks, walks about and moves right arm freely, but not with former power yet; face symmetrical, tongue in middle line, pupils equal. Sensation and speech restored. After this, recovery was steady and uneventful and at the present time, nine months after the onset, patient is conducting a large business concern and says he never felt better in his life. He still takes mercurial pills. This case illustrates how after a fair initial course of treatment cerebral syphilis may follow later; that absolute recovery is possible.

*Case 4.*—Chancre eleven years ago; headache for last year; aphasia getting worse for two months with agraphia and alexia; improved.

Patient is a male, age 33, clerk, acquired syphilis eleven years ago. Habits regular and moderate. For the last year or so has suffered periodically with headaches, sometimes worse at night; no vertigo. Eight weeks ago while traveling on business he became aware of a heaviness of speech with defective memory. He would forget his destination, neglected his business and lost his former sharpness in business dealings. He gave up and returned home and sought relief in various quarters, but his condition became worse. None whom he

consulted treated him for syphilis, as he, like the preceding cases showed no palpable signs; one advised him to marry. After eight weeks his condition was the following: Patient could utter scarcely intelligible words; the foregoing history was obtained from his father. His expression was stupid and dull in contrast to his former brightness. All movements were slow and languid. Marked tremor of face and hands. Pupils equal and react. No paralysis anywhere save the speech; can not read nor write. Physical examination negative except very slight general adenopathy. Was at once put on specific treatment, but after a few days developed iodism and the drug was stopped, but the inunction continued. After about four weeks' treatment he is back at work, talks, reads and writes as usual; memory as before; tremor entirely disappeared; no headaches—in fact, he feels as well as he ever did, but is still using inunctions. He was apparently quite well for about ten days and then according to the family, he changed again. He became forgetful again, said many foolish and untrue things, was restless at night, squandered money carelessly; in fact, his character quite changed. He is using inunctions and increasing doses of iodids. Patient has improved materially, but still shows some defects of memory and mental torpor. Occasional headaches.

*Case 5.* — Papulo-pustular syphilid; headache, paresis of left arm and leg with no loss of consciousness; optic neuritis; in four weeks almost complete recovery excepting the optic neuritis.

Patient is a male, age 43. No previous illness; uses alcohol moderately; denies a chancre. For nine weeks he has suffered with headaches, worst at night; vertigo at times recurring in paroxysms and becoming worse. A few days ago he first noticed a weakness in his left arm and leg accompanied by a tingling sensation and numbness. This loss of power came on gradually and he was at all times conscious. Speech unimpaired, mental condition as usual. He says the paresis and the skin eruption appeared about the same time. On examination pupils were equal and react; face symmetrical; tongue protruded somewhat to left. Marked weakness of left arm and leg, but some motion is retained, as he can walk dragging his left leg. Knee reflex equal but pronounced; ankle clonus on left side

Hyperesthesia, especially of left arm. General macular, papular and pustular syphilid and mucous patches in mouth. General adenopathy; internal examination was negative. He complained of dimness of vision. Ophthalmoscopic examination showed on the right side venous engorgement, papilla reddened and blurred, slightly swollen. On left side the changes were less marked. Treatment was then begun and its effects were very evident by the end of a week in the cessation of headache and returning power on left side. In four weeks eruption had disappeared; both sides about equal in strength, reflexes equal, no clonus, sensation normal. The optic neuritis had abated considerably, but vision was still impaired. At this time he passed from observation and the further course is not obtainable.

*Case 6.* — Evidence of syphilis; headache and dizziness; change in temperament; drowsiness deepening into coma; optic neuritis; paresis right facial and left arm and leg; ptosis slight on left side; death in coma on tenth day; autopsy, no gross lesions, disseminated endarteritis.

Patient, a male, coook, age 38, was already semi-stuporous when first seen, so that a good previous history was not to be had. He had some kind of skin eruption one year ago. For some weeks preceding present illness he is said to have had headache and vertigo, and his mild temper changed to a violent and irritable one with emotional outbreaks. His drowsiness deepened rapidly of late. Examination reveals patient semi-comatose, but he can be aroused sufficiently to answer some questions. Slight ptosis on left side; movements of eyes free. Pupils irregular and immobile; under atropin they dilated irregularly, tearing up iritic adhesions to lens. Interstititial keratitis on left side preventing examination of fundus. Optic neuritis on right side of moderate degree. Paresis in distribution of right lower facial. Tongue dry and protruded irreguarly. Slight paresis of left arm and leg with hyperesthesia. General adenopathy. Reflexes normal. Involuntary defecation and urination. Temperature normal, pulse 95 to 90. The urine contained albumin with hyalin and granular casts and abundant leucin crystals, but no tyrosin; the amount could not be estimated. On the usual treatment he improved for the first five days—he became brighter, the paresis of left arm and leg dis-

appeared, but the ptosis and right facial palsy remained. He can give a few simple answers, but is still very dull and sleeps a great deal. No tenderness on percussing skull. Urine contains less tyrosin. Occasional projectile vomiting. No convusive twitchings were noticed. On the eighth day the drowsiness again deepened and patient died on the tenth day in deep coma. Autopsy: Slight meningeal thickening at base of brain; no fresh inflammation. Cranial nerves apparently normal. Endarteritis obliterans of anterior and middle cerebral arteries, but no complete occlusion nor thrombosis was found. No aneurysms nor hemorrhage. No gross macroscopic lesions of brain. Of the other organs of interest the kidneys showed a condition of subacute parenchymatous nephritis.

I believe that we have sufficient proof of syphilis in the keratitis, iritis, adenopathy and clinical course of the disease, although the post-mortem findings are not conclusive, being limited in the brain mostly to the arteries. I will not deny that there may also have been a uremic element in the case. I will offer no explanation for the presence of leucin in the urine, occurring as it does most commonly in acute yellow atrophy of the liver, phosphorus poisoning, leukemia and various infectious diseases.

100 State Street.

REFERENCES.

Gray: Am. Jour. Med. Sciences, January 1892.
Gowers: Diseases of the Nervous System.
Heubner: Die syphilitischen Erkrankungen d. Gehirnarterien, 1874.
Ziemssen's Cyclopedia.
Rumpf: Monographie, Wiesbaden, 1887.
Oppenheim: Lehrbuch der Nervenkrankheiten, 1895.
Althaus: Med. News, 1886.
Mills: Med. News, 1895, No. 22.
Lydston: Jour. Am. Med. Assn., 1895, Vol. i.
British Med. Jour., 1895, Vol. i.
Gray: Text-book of Nervous and Mental Diseases.
Morrows: Syst. of Genito-urinary Dis. and Syphilis, Vol. ii.
Diller: Med. News, 1895, lxvi.
Hitchcock: Internat. Clinics, 1894, 45, iii.
Eskridge: Med. News, 1894, lxiv.
Joseph: Lehrbuch der Geschlechtkrankheiten.

Osler: Practice of Medicine.
Orth: Pathologische Anatomie.
Strümpell: Spec. Pathologie und Therapie.
Storbeck: Zeitschrift für Klin. Med., Bd. 29, p. 141.
Huchinson: Archives Surg., Lond., 1895.
Erb: Neurologisches Centralblatt, 1892.

DISCUSSION.

DR. MOYER—It needs no emphasis at this time to point out the immense importance of syphilis as a causative factor in disease of the brain and spinal cord. There is, however, a trifling misconception growing out of the mere use of terms. I see the doctor has labeled his paper, cerebral syphilis with report of cases, and he referred to the fact that Gowers had no chapter in his work on this subject. He would probably not find one upon syphilis of the spinal cord, and yet most of our German confrères have a chapter devoted to these subjects. It is not, however, that the English and American neurologists and the practitioner of general medicine do not recognize the importance of syphilis in the etiology of these disorders. The term cerebral syphilis and syphilis of the spinal cord, as used by our German confrères, is incorrect, as it puts into the nomenclature a new pathologic entity, like chorea, tabes, etc., a something which is caused by syphilis. We do not think it is possible to distinguish clinically the cases of tabes and paretic dementia having their origin in syphilis from those caused by other conditions. There is no doubt that most of the cases occurring in the meninges along the base of the brain, involving one or more of the cranial nerves, or a cerebral peduncle, or perhaps a single branch of the third nerve, or those which occur with a comparatively abrupt onset of symptoms, those cases are almost without exception syphilitic, but I do no think this justifies the term cerebral syphilis; I should say rather they were such and such conditions, affecting certain portions of the brain as the case might be, which were caused by syphilis. There was one case described in the paper which to my mind might justify the term cerebral syphilis. It was the one in which a diffuse endarteritis was found, but no local lesions. I believe that makes a clinical type that perhaps ought to have a chapter in works upon practice labeled cerebral syphilis. I have seen several such cases in which there was a rather abrupt onset with scarcely any local paralysis, early

interference with speech and sluggishness of the pupils; some exaltation of the mental functions, rapidly passing on into mild delirium, stupor and death. At the post-mortem, the findings are not different from those described by the doctor; but, as I say, this discussion really relates to terms and not to facts. The great importance of the doctor's paper is in directing our attention very pointedly to the influence of syphilis in these affections, and particularly in the cases that he describes, those presenting irregular manifestations and those with a comparatively abrupt onset, but this has been recognized for the last twenty years. Within the last eight or ten years, there has been an increasing importance attached to syphilis in the slow progressive degenerations, the ordinary cases of paretic dementia and tabes, and we must now admit, although still denied by a few, that syphilis causes 80 or 90 per cent., or even more of these cases. There is, too, a striking difference in regard to treatment in this class of cases. Those with an abrupt onset are usually quite amenable to treatment; those in which the symptoms come on slowly and insidiously are most rebellious to treatment, no matter how energetically pursued, and I think the reason is found in the fact that the changes in these other conditions are really secondary. Take, for instance, an endarteritis that leads to a rupture of an artery or thrombosis. The secondary conditions are not amenable to anti-syphilitic treatment. The same applies to cases of insidious onset, in which specific treatment does so little and yet it is undoubtedly true that they are of syphilitic origin. The reason of it is that this slow, progressive syphilitic endarteritis has set up the secondary changes, sclerotic in character, and when those changes are once set up, it makes no difference what the cause is, the treatment is practically *nil*, no matter how energetically pursued. But coming to the practical point; the evidence is now so strong that in all these cases it is the duty of the practitioner, even in the absence of a history of syphilis and even where it is denied, to give an energetic anti-syphilitic treatment. I prefer the mixed treatment, but give the iodids in relatively very large doses.

Dr. Wm. Hessert—I think that Dr. Moyer and I agree, only that we express our views in different ways. I meant to say that the subject of cerebral involvement by syphilis has been

described as an entity under a special heading of late by German authors; especially Oppenheim in his last work gives a classic description of cerebral syphilis, meningitis and inflammation of the cerebral cortex. I admit certainly that the subject of cerebral syphilis is as old as the subject of syphilis itself, and thousands of years ago we may say that mankind was affected with the cerebral involvement just as to-day; but the point is that it was not recognized as of late years.

DR. LUDVIG HEKTOEN read papers on

## OBSERVATIONS ON GUMMA OF THE HYPOPHYSIS; AND PRIMARY CARCINOMA OF THE URETER.

### GUMMA OF THE HYPOPHYSIS.

In hereditary syphilis, the hypophysis may be enlarged and indurated, due to connective tissue proliferation.[1] In acquired syphilis, gumma of the hypophysis has been described by Troisier,[2] Weigert,[3] Barbacci,[4] Birch-Hirschfeld[5] and Sokoloff.[6] In these cases there can not be much doubt concerning the truth of the diagnosis. In Troisier's case the origin of the gumma is referred to the capsule of the hypophysis. Boyce and Beadles[7] detail a case of granulomatous infiltration of the hypophysis which they regard as tuberculous, but without having shown tubercle bacilli to be present. The same uncertainty of diagnosis is attached to Wagner's[8] case of "tubercle of the pituitary," which he observed in a girl aged 13 years, without tuberculosis elsewhere.

---

1 Lancereaux, Traité historique et practique de la syphilis, 2d edit., Paris, 1873, p. 288.

2 Bull. de la Soc. Anat., 1874, T. xlix, p. 25.

3 Virch. Arch., 1875, Bd. 65, p. 223.

4 Centralbl. für Allg. Path. and Path. Anat., 1892, iii, p. 301.

5 Path. Anat., 1894, Bd. i, p. 281.

6 Virch. Arch., 1896, Bd. 143, Heft 2.

7 Journal of Path. and Bact., Vol. i, No. 3, p. 359.

8 Arch. f. Heilkunde, Bd. ii, 1862.

The following case of gumma of the hypophysis consequently merits report on account of the rarity of the lesion:

Woman, age 45, died on the same day as she entered the hospital without being able to give any information concerning her history. The post-mortem was made twenty-four hours after death.

The anatomic diagnosis reads: Chronic interstitial nephritis; chronic perihepatitis and perisplenitis; syphilitic cirrhosis of the liver with gummata; gumma of the hypophysis; thick skull; chronic interstitial myocarditis. Bacteriologic examination showed the heart's blood, the lung, the liver, the kidney, and the spleen to be sterile. Only the liver and the hypophysis need to be described at this time.

The liver weighs 1,570 grams. It is adherent to the diaphragm, especially along the falciform ligament. The adhesions are firm and fibrous. The surface of the organ is irregular and in the vicinity of the falciform ligament are puckered cicatricial depressions in the bottom of which the tissue is firm and whitish in color. The consistence is firm. On the cut surface there is observed a marked but irregularly arranged increase in fibrous tissue, but this is also best marked about the insertion of the falciform ligament; here the substance of the organ contains whitish nodules or areas that are inclosed in puckered capsules of fibrous tissue from which trabeculæ radiate in all directions. Larger, homogeneous districts are also present.

The hypophysis is about twice the usual normal size; it is firm, rather homogeneous and grayish-red on the cut surface; the walls of the sella turcica are rough. The hypophysis weighs 1.8 grams.

The skull, which is plagiocephalic, is unusually thick, measuring, at the line of the incision to remove the calvaria, from 8 to 10 mm. in thickness, its bone being very dense, the diploë almost entirely absent, or replaced by compact tissue.

Microscopic examination of the hypophysis shows the entire organ the seat of a diffuse round-cell infiltration, throughout which are scattered numerous multinucleated giant cells. Only in a few places are indistinct remnants of follicles present. There are present a few irregular areas of necrosis in which the substance is homogeneous or finely granular. Blood vessels are sparse and their walls are often diffusely infiltrated. There are no miliary tubercles at the periphery of the mass. Under high power the nuclei of the cells are seen to be oval, spindle-shaped and stained but lightly; or smaller, round and deeply colored. Irregular shaped nuclei are also present. The giant cells show the protoplasm to be red (eosin), finely granular or homogeneous, the nuclei being heaped up mostly at the periphery. Large, distinctly epithelioid cells are not present. The ground substance is homogeneous or freely granular with but slight filtration. In the distinctly necrotic districts are nuclear fragments of all shapes and sizes. Eight slides were examined carefully and repeatedly for tubercle bacilli (carbol-fuchsin) but with negative results.

The liver shows marked thickening in Glisson's capsule with areas of diffuse cell infiltration in which are giant cells and encapsulated necrotic districts. This is most marked near the surface of the organ. There are no tubercles in the sections. Tubercle bacilli were not found.

From this examination it is believed that the diagnosis of gumma of the hypophysis is justified upon the following grounds:

1. The absence of typical tubercles and of tubercle bacilli, the structure being that of a degenerating granuloma.

2. The presence of a distinctly syphiltic process in the liver.

3. The absence of tuberculosis in all of the organs ordinarily examined in a thorough post-mortem.

In this case the gumma was not large enough to give rise to any symptoms. In Birch-Hirschfeld's case (loc. cit.) the walnut-sized gumma gave rise to pressure symptoms. The present case is the only one associated with evident increase in the thickness of the skull and this association may very likely have been simply accidental or due to the same cause as the gumma, namely, the syphilitic infection. Gumma of the hypophysis is of evident clinical importance because the consecutive pressure effects ought to be removable under appropriate antisyphilitic treatment.

PRIMARY CARCINOMA OF THE URETER.

While it is not unusual for the ureter to become invaded by carcinoma extending from the uterus, the rectum or the urinary bladder, primary carcinoma of the ureter is very uncommon. Recent systematic works on surgery and on tumors contain no mention of carcinoma of the ureter. Indeed, the entire list of primary tumors of the ureter described in the literature is very short.

Lebert[1] describes a polypoid fibroma; Thornton,[2] a

[1] Anat. Path., ii, p. 372.

[2] Trans. Lond. Path. Soc., Vol xxxvi, p. 269.

papillary fibroma, upon which a calculus was situated; Neelsen,[3] a typical papilloma of the upper part of one branch of a partially reduplicated ureter causing a large hydronephrosis of the corresponding half of the kidney. Chian[4] records a so-called cholesteatoma of the ureter, and Ribbert,[5] a myosarcoma. Orth[6] credits Litten[7] and Hartman[8] with having observed carcinoma of the ureter. Wising and Blix[9] describe a case of primary carcinoma of the right ureter with secondary tumors in the mesenteric glands, the rectum and the liver, with hydronephrosis, in a woman 41 years old, whose urine did not contain anything abnormal. There was a hydronephrosis containing 1,000 grams of fluid. The upper 12 cm. of the ureter was spirally twisted, hard and thick, converted into a solid string the size of the little finger. On the cut surface there was no lumen, but in place of it a loose, yellowish gray disintegrating neoplasm. The wall of the rectum was the seat of multiple, submucous nodules due to extension from the metastasis in the retroperitoneal glands. The structure was that of a medullary carcinoma. Hedenuis[10] describes hazel- and walnut-sized carcinomatous nodules in the mucous membrane of the pelvis and the ureter which were situated in the mucous membrane and pronounced by Hedenuis to be a primary carcinoma.

The following case concerns a married woman 50

3 Ziegler's Beiträge, iii, p. 279.
4 Prag. Med. Wochschr., 1886.
5 Virch. Arch., 106, p. 282.
6 Lehrbuch der path. Anat. Bd. ii, 1889.
7 Char. Annalen, iv, p. 188.
8 Soc. Anat. de Paris, 1862.
9 Hygiea, 1878, p. 468.
10 Upsala Läkareföreningens Föhr, Bd. 13, H. 4, quoted by Wissing and Blix, loc. cit.

years old, who had been in fair health until eight months before death, at which time she became aware of some pain about the right hip which was regarded as rheumatic. The pain gradually increased and soon the right lower extremity became swollen, and a swelling appeared in the right inguinal region. There was no history of any injury. Examination about one month before death showed marked emaciation, the heart and lungs apparently normal. Filling the lower right quadrant of the abdomen was a soft mass which seemed connected with the right ilium; the mass had an irregular outline, and in the vagina it could be felt that the uterus was pushed to the left. The urine was normal, sp. gr. 1015. Death from exhaustion about eight months after the first painful symptoms appeared and after being bedridden for three months. The clinical diagnosis was osteosarcoma of the pelvis.

*Anatomic Diagnosis.*—Tumor of the pelvis involving the right ureter; hydronephrosis and atrophy of the right kidney; atrophy of the heart; pulmonary emphysema; chronic adhesive peritonitis; fibromyoma of the uterus.

The body is that of a senile woman, poorly nourished; rigor mortis present. The peritoneal cavity is empty; there is a retroperitoneal mass filling right half of pelvis and presenting on its pelvic aspect small, whitish, firm excrescences; the cecum is adherent to the tumor mass by means of firm, fibrous bands. The pleural cavities are empty and free from adhesions. The pericardial cavity is empty; the pericardial layers are smooth. The heart weighs 210 grams; the endocardium is smooth except that there are some whitish areas in anterior mitral valve. The heart's

flesh is brownish and of uniform, rather firm consistence. The coronaries are normal.

The aorta is quite smooth. The lungs are very spongy and light; they contain but a small amount of blood. The bronchial glands normal. The spleen weighs 110 grams; its capsule is nodular and thickened. The liver weighs 1,200 grams; it is brownish in color. The pancreas and the gastro-intestinal tract are normal. The uterus contains a walnut-sized, submucous fibromyoma attached to the posterior wall of the fundus by a rather slender pedicle.

The tubes and ovaries are normal, the ovaries being small. The vagina is normal. The adrenals are normal.

The left kidney weighs 140 grams; the capsule is free, the surface smooth, the consistence firm; the cortical markings not distinct. The right kidney is not present as such; in its place is a cystic cavity containing about 800 c.cm. of a slightly turbid, grayish, thick fluid; the walls of this cavity, whose inner surface is smooth, are quite thin and directly continuous with the post-peritoneal tumor mass about to be described. The tumor appears to spring from the inner surface of the right ilium. It forms an irregular mass about the size of a child's head. On the cut surface it is whitish-gray in color; its consistence is soft and it contains numerous, small irregularly shaped cavities, filled with creamy semi-solid material. The ureter can not be identified at the upper limit of the tumor. A probe, passed upward from the opening in the bladder, becomes arrested about 2.5 cm. above. Careful dissection shows the ureter to be entirely lost in the tumor tissue. Upon removal of the tumor it is found that the inner sur-

face of the ilium is eroded. The retroperitoneal glands are not enlarged.

Microscopic examination shows the structure of the tumor to be that of a typical medullary carcinoma. Throughout the section are large and small islands and districts of epithelial cells imbedded in a connective tissue stroma, which is composed of loosely arranged fibrillated connective tissue with but very few vessels. Only the smaller masses of epithelial cells are free from degenerative changes. The larger carcinomatous districts show a granular disintegration in their center, which might in some instances be mistaken for epithelial pearls; in many places the degenerative necrosis is very extensive and results in the formation of small cavities surrounded by a narrow zone of epithelial cells. The epithelial cells in the smaller, recent nests show innumerable, poorly preserved (twenty-four hours, post-mortem) karyomitotic figures. The nuclei are rich in chromatin. The general characters of the cells in these recent districts of proliferation are those of the transitional epithelium of the ureter and the bladder, the cells varying greatly in their form, being oval, spindle- and club-shaped, and their nuclei polymorphous and often lobulated.

The reasons for regarding this carcinoma as originating in the ureter are the following:

1. The location—there being no other archiblastic structure in the vicinity than the ureteral lining—and the direct involvement of the ureter in the tumor, the larger part of the canal being entirely lost in the tumor mass, the hydronephrosis and complete atrophy of the kidney being due to complete destruction and closure of the lumen of the ureter.

2. The marked similarity of the epithelial cells of the tumor to the cells lining the ureter, the transitional character of the latter being well preserved in the tumor.

3. The absence of carcinoma elsewhere and the voluminous size of the primary retroperitoneal growth.

It is important to note that in carcinoma as well as other tumors of the ureter, occlusion of the lumen of the latter and consecutive hydronephrosis with atrophy of the kidney seem to occur quite regularly, as far as can be concluded from the few cases now at hand.

The thorough and systematic study of early carcinoma of the ureter, the earlier the better, would throw needed light upon the more exact origin and development of this rare, but interesting form of malignant epithelial tumor.

DISCUSSION.

DR. LE COUNT—I think there can well be added to the reasons that Dr. Hektoen cites for regarding the carcinoma of the ureter as primary, because of the fact that there is nothing else in that region that could give rise to the peculiar neoplasm the sections of which we see under the microscope.

PRESENTATION OF SPECIMENS.

DR. LUDVIG HEKTOEN presented:

1. *Spindle-celled Sarcoma of the Liver*, in the Form of multiple Nodes and Nodules secondary to a Sarcoma of the Eyelid removed four Years before Death.

The liver was brought to the pathological laboratory of Rush Medical College by Dr. Koon, of Casmonia, Mich. It had been removed from the body of a man 60 years of age. Four years before death Dr. Koon had removed a small tumor of the eyelid which was diagnosed as an epithelioma. The liver weighed eighteen pounds and was the seat of innumerable large and small tumors of a whitish or grayish color. There were tumors found in the kidneys, pancreas and retroperitoneal region.

Microscopically the structure was that of a medium-sized spindle-celled sarcoma.

This specimen illustrates one of the forms of secondary sarcoma of the liver, namely, the form which occurs in the shape of multiple nodes and nodules scattered indiscriminately through the substance of the organs, plainly due to embolism of tumor cells and masses.

2. *Diffuse, infiltrating Melano-sarcoma of the Liver*, secondary to Melano-sarcoma of the Eye; Ascites due to Occlusion of the Capillaries of the Liver by Tumor Cells and consecutive Thrombosis of the intrahepatic Branches of the Portal Vein.

Man, age 50, manufacturer, of dissolute habits, came under the care of Professor Holmes at the Presbyterian Hospital, Sept. 17, 1895, on account of loss of vision in the right eye which dated back about three years. Professor Holmes diagnosed the condition of the right eye, which was protruding and nodular, to be due to a melano-sarcoma of the choroid. Physical examination was otherwise practically negative. On November 15 some ascites had developed, and on the 25th of this month the ascites had become pronounced; there was jaundice and the urine contained bile pigments. The patient was passed into the care of Dr. J. A. Robison, and I have to thank both Professor Holmes and Dr. Robison for their permission to make this very brief extract from the clinical history of the case. The patient died Dec. 7, 1895, apparently from exhaustion. The postmortem examination was made one hour after death. The anatomic diagnosis reads: Melano-sarcoma of the right eye and the orbit; atrophy of the right optic nerve; metastatic tumors in the lungs, pleuræ and left kidney; diffusely infiltrating metastatic melano-sarcoma of the liver; chronic congestion of the spleen; thrombosis of the intrahepatic branches of the portal vein; ascites; general bile pigmentation; chronic nephritis; chronic (left) orchitis; general arterio-sclerosis. The body is much emaciated; the skin and visible mucous membranes yellow; the right eye protruding, the eyeball nodular; the orbit is filled with a hard mass, the cornea turbid. The abdominal cavity contains a large quantity of yellowish fluid, the peritoneal layers are smooth. The pleural and pericardial cavities are empty. The heart weighs 450 grams; endocardium normal.

The lungs are edematous and contain a few small solid nodules that are grayish and in places almost black on the cut surface. Similar smaller masses are found here and there in the pleuræ. The larynx, trachea and peri-bronchial glands are normal. The spleen is firm, very dark red in color, contains much blood and weighs 450 grams. The kidneys weigh 350 grams, the surface is irregular, the cortex thin, the consistence firm. In the left kidney is a small, subcapsular tumor nodule. The left testicle is firm, fibrous. The liver is very much increased in size, the left lobe being almost as large as the right; it weighs 4100 grams. The external surface is rather finely nodular, mottled bluish and gray in color; many small pin-head sized and a little larger gray tumor masses are seen on the surface. In consistence the liver is very dense and firm, like sole-leather or hard rubber. The cut surface is also irregularly nodular or granular, the predominating or ground color being bluish black with small gray districts here and there, so that the general appearance of the surface is best described as granite-like or variegated, like marble. The large vessels in Glisson's capsule and the branches of the portal vein are filled with rather softly coagulated blood. The gastro-intestinal tract is normal, but the mucous membrane is slaty in color. The pancreas is normal. The aorta and the splenic artery show a rough and irregular intima. The skull and the brain are normal, the vessels at the base being sclerotic. The interior of the right eye is partly filled with a firm tumor that seems to spring from the choroid, is quite black on the cut surface, and largely replaces the vitreous humor; at the entrance of the optic nerve the tumor extends for a short distance backward in the substance of the nerve and at the corneo-scleral junction of the internal aspect of the globe the tumor tissue perforates all the coats of the eye and spreads out into a walnut-sized retro-bulbar tumor mass which is grayish white in color with only here and there blackish or brownish dots and areas. The right optic nerve is smaller than its fellow and gray in color. Blood serum tubes inoculated from the heart's blood and the ascitic fluid remained sterile. The microscopic examination of the tumor of the eye and the nodules in the lungs and the left kidney shows the same stricture, namely, that of a small spindle-celled sarcoma, which in the eye, is melanotic, the cells here

containing very much, dark brown, granular pigment, which also occurs free, between the cells. In the other places the majority of the tumor cells are not pigmented. The liver shows but extraordinary little true liver structure; it consists almost entirely of tumor tissue which is very much pigmented. Wherever the hepatic structure still remains the capillaries are found filled with small spindle-shaped, pigmented cells and in the large vessels, veins as well as arteries, are hyaline thrombi, in which are imbedded isolated melanotic cells. In some districts the tumor tissue is not uniformly pigmented. The connective tissue of the liver is not much increased and distinct bands of fibrous tissue are not present. From this examination it can be concluded that an almost continuous, capillary embolism, or immigration, of melanotic sarcoma cells took place from the primary choroidal melano-sarcoma, that these cells passed almost unhindered through the pulmonary capillary network —only a few small tumor nodules are present in the lungs— and became lodged in the capillaries of the liver which the cells reached by way of the portal vein as well as by way of the hepatic artery. Only a very few cells were diverted from this course as shown by the presence of but one metastatic tumor outside of the lungs, pleuræ and liver, namely in the left kidney. In the liver this continuous capillary embolism resulted in the development of a diffuse tumor growth which replaces the liver tissue proper while it largely retains the normal external conformation of the liver. Larger nodules are not found in the liver. Finally the capillaries and smaller vessels become so packed with tumor cells that the portal circulation is obstructed, ascites develops, and thrombosis of the intrahepatic branches of the portal vein is induced. The development of ascites upon this basis—obstruction of the portal capillaries by melanotic sarcoma cells—is exceedingly interesting and has not been mentioned in the current descriptions of this remarkable form of secondary sarcoma of the liver, the diffuse infiltrating variety. This form of secondary sarcoma of the liver—it practically always concerns melano-sarcoma, may also develop years after the removal of the primary tumor. Thus in an instance referred to by Birch-Hirshfeld seven years intervened between the operation and the demonstration of a diffuse pigment sarcoma of the liver.

3. *Primary Large, Round-Celled Sarcoma* of the Left Lobe of the Liver; Sinus Thrombosis and Thrombosis of the Pial Veins of the Convexity.

Paul P., harness maker; was admitted to the Cook County Hospital (Service of Dr. Leahy, Dr. Ryan in charge) Sept. 24, 1895, and died Oct. 2, 1895. Extract from the clinical history: Well nourished; delirious; pupils equal and active; paralysis of right internal rectus; mouth drawn to the right; neck muscles rigid; double optic neuritis; right arm and leg are paralysed. Lungs and heart normal, pulse slow and regular. The liver dullness reaches from fifth rib to costal arch. In the left hypochondriac region is a hard mass that reaches beyond median line and seems continuous with splenic dullness; it moves with respirations and is covered by a tympanitic area. Gonorrhea; urine normal. The delirium gradually gives way to stupor that deepens into coma. There is conjugate deviation of the eyes to the left. Shortly before death the temperature rises to 100.8-102, and the breathing becomes rapid.

Clinical diagnosis: Tumor of the pancreas; multiple cerebral tumors? Meningitis?

Anatomic diagnosis: Tumor of the left lobe of the liver, tumor nodules in the mesentery, omentum, spleen and at the tail of the pancreas; thrombosis of the dural sinuses and of the veins of the lepto-meninx of the convexity; multiple capillary hemorrhages into the cortex about the left calcarine fissure; fibrinous pneumonia; thrombosis of inferior vena cava.

Extract from the protocol: General nourishment good, peritoneal cavity empty. Pleural cavities obliterated by firm adhesions. Pericardium smooth and shining.

Heart weighs 310 grams, endocardium normal. The lower lobe of the right lung consolidated, gray and granulated on the cut surface. Thyroid gland normal. Bronchial glands anthracotic. The omentum is adherent to the liver and contains two small, firm, reddish-gray tumor nodules. The left lobe of the liver is occupied by a large nodular mass about 10 cm. in diameter, which seems to have replaced all the liver substance proper. The right lobe is normal so that the liver may be said to consist of a normal right lobe which merges into an irregular tumor of almost the size of a child's head. Externally the

tumor is nodular, firm; on the cut surface it is grayish-red in color; in the center are calcareous masses, and from the center appear to run radiating cicatricial bands that gradually disappear toward the periphery of the growth. But little liver tissue can be recognized around the tumor which merges gradually with the right lobe. The pancreas is normal. Situated above the tail of the pancreas and distinct from the latter is a firm, reddish-gray mass about as large as a hen's egg. The spleen is normal, but there is a small tumor mass underneath the capsule. The kidneys and adrenals normal; bladder, testicles and seminal vesicles also appear normal; the mucous membrane of the urethra is covered with a small amount of pus. The gastro-intestinal tract is normal. The vena cava contains a grayish, granular thrombotic mass adherent to the intima just below the entrance of the hepatic vein. The skull is normal; all the dural sinuses are filled with adherent, reddish-gray, rather soft blood clots, which extend into the veins of the lepto-meninx of the convexity, which stand out prominently like whip cords and contain red thrombi. The ventricles are empty and not dilated. There is some increase in the cerebro-spinal fluid, but no inflammatory exudate. The brain substance seems quite normal but the gray matter bordering upon the left calcarine fissure contains innumerable minute hemorrhagic extravasations, the puncta vasculosa are everywhere large and apparently very numerous, and the color of the white matter is quite pinkish. The jugular veins are empty, the intima smooth, and there is no thrombosis. The cavities and sinuses of the cranium are normal.

The microscopic examination of the tumor of the liver and the smaller nodules show that all present the same structure, namely, large, roundish cells with deeply staining, rather small nuclei. The cells are imbedded in a fibrillated vascular stroma which separates the individual cells one from the other at the same time as it is collected into broader bands that divide the tumor into smaller and larger cell groups. The large round cells seem to bear a very close relation to the vessels, which are very numerous and present thick walls and at times a proliferating intima. Any direct relation between the endothelium and the tumor cells could not be demonstrated. From the adventitia of the vessels pass the strands of fibrillated connec-

tive tissue forming the stroma. In the liver, hepatic cells or bile ducts can not be found in the central part of the tumor. Nearer the periphery the tumor cells compress the liver cells and seem to cause atrophy of the latter.

From these appearances the diagnosis of a primary large, round-celled sarcoma of the liver with metastasis at the tail of the pancreas, in the mesentery, omentum and the spleen, seems warranted because of the great size and evident age of the liver tumor, the comparatively insignificant size of the other tumors, and the absence of any larger tumor in any part of the body to which all the above growths might be secondary. Evidently the sarcoma originated in the perivascular connective tissue of Glisson's capsule in the liver.

The occurrence of such extensive thrombosis of the cerebral sinuses and lepto-meningeal veins, to which the marked cerebral symptoms are referable, is very interesting from a diagnostic as well as a pathogenetic standpoint, but the further consideration of this question must be left to some future time. While the liver is the most frequent seat of secondary sarcoma next to the lungs, primary sarcoma of this organ is very rare. Hence the demonstration of this specimen. Arnold,[1] in 1890, reported two cases because he had thought up to that time that primary sarcoma of the liver did not occur. He was able to collect twenty-six cases from the literature which were reported as primary. Histologically these cases represent the principal varieties of sarcoma; the pigmented form, however, is almost always secondary. Thus Hanot et Gilbert[2] exclude all the instances reported as primary pigment sarcoma but one.

DISCUSSION.

Dr. Edwards—The third case of sarcoma of the liver that Dr. Hektoen has presented, might have some clinical interest in that the tumor in that case was diagnosed as a carcinoma in the region of the left lobe, or the region of the fundus of the stomach; the exact source of origin of the tumor could not be determined because of the obvious broad attachment of the tumor. The main point of interest in the case is that the patient developed many months before death, very marked cerebral symptoms. He had symptoms some six or eight

[1] Ziegler's Beitraege, viii, 1890.
[2] Etudes sur les maladies du foie, Paris, 1888.

months when he was in the hospital for the first time, and at that time particularly his symptoms were vague; they were by no means focal. He received anti-syphilitic treatment, and there was, after a number of months, a distinct remission in the cerebral symptoms. He came back to the hospital; had been in the hospital for some time with this tumor and he began gradually to evince more pronounced cerebral changes. He had at first a distinct choked disc, the veins stood out very prominently, and besides the venous changes, secondary change in the disc itself. The optic inflammation and passive congestion, together with the mental symptoms, made it highly probable, arguing from the facts, that he had neoplasm of the abdomen, with a metastatic deposit in the brain. The cerebral symptoms were mainly diffuse, though it was said one convulsion was localized in one side of the body. He had a delirium, he had a strabismus, one internal rectus being affected. Our surprise at the postmortem was great, that, instead of having a neoplasm, which we might reasonably have expected from the abdominal neoplasm, there was a thrombosis in some, if not all, the cerebral sinuses.

Dr. Holbrook presented a specimen of *Myosarcoma of Cerebellum.*

This specimen is of interest, not alone from its rather unusual pathologic condition, but from the long observed clinical history which it produced. The patient had been examined and treated and watched by a large number of physicians and specialists, and although the diagnosis of brain tumor had been indefinitely settled upon, there was great variance of opinion as to the variety, the location and complication. The specimen is taken from a case which was admitted to the Presbyterian hospital in January, 1895, and was put under the service of Dr. Robison, who has kindly consented to let me give the clinical details. The clinical history is briefly as follows: A year before admission severe gastric disturbances appeared which were called bilious attacks, with persistent vomiting and constipation of bowels. Cerebral symptoms developed a short time later; especially diffused headache, the headache localizing at times in the occipital region and in the posterior cervical region. Shortly after these symptoms developed, the patient noticed interference and impairment of vision. The tumor,

you will notice, is located on the left side. The first impairment of vision was naturally in the right eye. This continued until the eye was completely blind, the left eye being involved shortly after and upon admission to the hospital after the space of a year, the patient was able to distinguish light from darkness and marked outlines with the left eye. Upon admission the examination of the eye showed the pupillary reflex to be prompt and normal and the pupils to be dilated equally upon both sides. Other symptoms: General weakness on the right side of the patient's body although he was a right-handed man; there was no paralysis or anesthesia noticed at that time, and the reflexes were as were to be expected, all normal excepting for the right knee jerk, which was exaggerated.

About four or five weeks before his death the patient developed convulsions; these would occur at intervals of days at first, and finally occurred two or three times daily. The first convulsion consisted of muscular spasms on the left side of the body, but after this the convulsions were started on the left side, but also involved the right side. During this time the patient's eyeballs were noticed to be anesthetic, but these were the only signs of anesthesia found, even the cornea could be touched with no action on the part of the patient. The night before the patient died he was in constant convulsions; in the morning he was comatose and died very suddenly. The autopsy was held about twenty-four hours after death by Dr. Hektoen. The patient was well nourished; no metastatic tumor was found in any portion of the body; there was a congested condition of the organs of the thorax and abdomen. On cutting open the skull cap, the calvaria was found to be very thin, especially so in some rough and reddened spaces; the dura was seen to be flattened over the area, the convolutions under the dura were seen to be flat, showing a diffused and general pressure which seemed to be equable; the fissures were obliterated. On removing the skull, the lower part of the base of the skull was found normal, and the brain was cut open; the ventricles were found to contain a fluid which passed freely from one ventricle to the other, and distended the ventricles very markedly. The growth to which I would particularly call your attention was on the left cerebellar lobe. I have located it upon diagrams.

The growth as here represented is 6 centimeters long, 4 wide and 3 deep. It impinges upon the medulla so as to compress the left half, and has displaced the right half, as can be seen on the specimen. The pia mater over the growth was free; it is attached firmly to the cerebellar substance, from which it evidently arises. It impinges upon the last six nerves. The substance of the cerebellum around the tumor is considerably softened; the tumor was of a medium consistency. On making microscopic examination, the tumor was found to be a myxosarcoma; the blood vessels are numerous; there are some hemorrhagic areas which you will notice in the section, which, however, are not numerous nor characteristic. The history of twenty-seven months is rather long for a sarcoma with the symptoms as given; perhaps the myxomatous degeneration had much to do with modifying the malignancy. I think the symptoms which are given and one which I omitted, that of the complete loss of hearing in the left ear, are easily made compatible with the anatomic findings.

## Regular Monthly Meeting, May 11, 1896.

The President, Dr. Weller Van Hook in the Chair.

Dr. Louis J. Pritzker read a paper entitled

### THE SURGICAL TREATMENT OF TUBAL PREGNANCY WITH REPORT OF A CASE.

The case was that of a woman aged 28, married, who gave birth to a child two years before coming under the author's observation. Her previous history was otherwise unimportant. She menstruated last, July 10, 1895. About six weeks later she began feeling pain in the left iliac region; on August 23 she suddenly went into collapse. Dr. T. A. Davis made a diagnosis of ruptured tubal pregnancy and sent her to the Cook County Hospital, where the author operated on August 24, at 5 P.M. There was found an interperitoneal hemorrhage which seemed to come from the left tube and which was controlled by ligation of the tube close to the uterus. The left adnexa were removed, the right were healthy and were not disturbed. The rent in the tube was situated in superior wall at the middle third, and here there was a small placental mass. No corpus luteum was found in the ovary. There was a small ovum found in the tube, appearing from four to six weeks in age. An uninterrupted recovery occurred.

Dr. Jas. Dorland presented a specimen of extra-uterine pregnancy which he had removed from a woman 20 years old, by laparotomy. Six weeks after her last menstruation she began to flow very much, and a small swelling the size of an orange was found on the right side of the uterus. The uterus was curetted and an expectant treatment was pursued and the swelling grew smaller, but suddenly she collapsed, the swelling became boggy and increased in size. Laparotomy was made, intraperitoneal hemorrhage found, and a sac containing a fetus removed. The patient is progressing nicely six days after the operation.

Dr. Byron Robinson—The thing of interest to me is that I have never seen nor heard of a case of extra-uterine pregnancy in the lower animals. I notice that Bland Sutton mentions the same fact.

## Regular Monthly Meeting, June 8, 1896.

In the absence of the President, Dr. Herrick, Dr. A. J. Burgess was elected Chairman *pro tem.*

Dr. Eliza H. Root read a paper entitled

# REPORT OF A CASE OF COMPOSITE MONSTER—MONOMPHALIC ISCHIOPAGUS.

M. J., Swede, blonde, age 26; domestic; primipara; entered the Chicago Hospital for Women and Children, March 18, 1893. Last menstrual period July 7, 1892. Patient was delivered May 4, 1893, 301 days from the beginning of last menstruation.

On entering the clinic the patient was pale and passing albuminous urine with low specific gravity, in excess of the normal quantity in the twenty-four hours. Under treatment the albumin disappeared, to again return for two weeks preceding labor. The patient complained of the weight of the tumor and of pain along the line of Poupart's ligaments.

*Examination.* — Inspection found the abdominal tumor very large and prominent, abdominal muscles tense and the skin greatly stretched; size of pelvis normal.

Palpation discovered two heads in fundal zone of the uterus and to right of median line. The head of the posterior fetus lay deeply in relation to the anterior uterine wall. Back of anterior fetus easily followed to breech into the iliac fossa (left). Fetal heart sounds were heard above umbilicus, a little to left of median line. Second heart sounds not heard.

Although polyhydramnios was present, the uterine contents were not freely movable, except the head of the anterior fetus and at no time could the extremities be determined. Internal examination found anterior vaginal fornix empty.

FIG. 1.—Anterior view, with foot of posterior fetus in front.

*Diagnosis.*—Twins; first, breech sacro-anterior; and second, breech sacro-posterior; both oblique (the vertical axis of the uterus in median line), with a provisional diagnosis of "something unusual, perhaps a double-headed baby." This last was made only half in earnest, for the idea of a composite monster had

not taken serious hold upon my mind. On April 18, albumin reappeared in the urine; urine excessive in quantity, frequently amounting to 90 or more ounces in the twenty-four hours. The patient complained of feeling dull and weary. The tumor was very large and hanging well forward. The bowels were kept free with small daily doses of Epsom salts. Blaud's iron pill was given for the anemia. April 29, patient restless and does not sleep well; excessive amounts of albuminous urine continues to pass. May 3, patient began to have slight uterine contraction-pains. During the night labor was established. As there was no progress made of the presenting parts, the pains being strong, the house physician called me to the hospital on the morning of May 4. I found the os well dilated, the membranes ruptured, and a presenting mass only partly engaged in the inlet. The examining finger found no feet, no namable part and slipped into a rather large orifice guarded by a border of loose folds. It was very evident my provisional diagnosis was more than true, and that I was confronted with a difficult and dangerous labor. Dr. John Bartlett kindly responded to my call for assistance. The patient was put to sleep with chloroform and the pelvis explored, which confirmed the diagnosis of double breech presenting. Pains continued strong and we proceeded to deliver. The obstetrics of the case is of considerable interest. Given a square mass presenting, the feet not being found, it was fair to assume that the legs were extended, giving in each a breech presentation of the incomplete variety. The application of forceps proved useless, and further examination found the right limb of the second sacro-poste-

rior fetus resting transversely upon the anterior ramus of the pubis (see photo. Fig. 1), the hip caught above the brim and preventing descent. All efforts to push the limb out of the way were fruitless as it had become firmly impacted between the fetus and pelvic brim.

FIG. 2 —Left lateral posterior view, approximating true position in utero. 1, first sacro-anterior; 2, foot of posterior fetus; 3, second sacro-posterior.

The posterior limb of the first sacro-anterior fetus was seized and brought down giving some increase of space and a handle for traction. Descent was still unsatisfactory, and another limb, the posterior limb of the sec-

ond sacro-posterior fetus was with difficulty brought down, but securing more space, partially breaking the wedge and giving an added means for traction. To and fro movements with strong traction upon the disengaged limbs brought the double breech well into the pelvic cavity.

Advancement was now progressive though slow and difficult. The finger could now be hooked into the groin of the transversely lying limb of the second sacro-posterior fetus. This limb was now gradually pushed upward by the descent of the mass and became extended parallel to the trunk of fetus, which with the remaining anterior limb of the opposite fetus acted as a splint, making the crossing of the pelvis and advancement into the axis of the outlet extremely difficult.

At the expiration of two hours our combined efforts brought the double breech, partially rotated into the vaginal opening. The two unborn limbs were disengaged and the true nature of the deformity became evident.

As advancement of the two trunks together would further complicate labor by bringing the two heads face to face into the inlet the two bodies were separated at the pelves. The now second sacro-anterior fetus was brought down and passed the now first sacro-posterior fetus until the nape of the neck could be reached for decapitation. Delivery was soon completed without hemorrhage. Traumatism of cervix and vaginal walls was considerable; the perineum was ruptured and repaired with sutures of silkworm gut. The placenta came without difficulty and weighed 3½ pounds. Aseptic occlusion pad was applied to

vulva and the patient put to rest greatly exhausted; pulse 150; temperature 100.6 F.

Morning of May 5, temperature 98.6, pulse 126. Evening of same day, temperature 99.6, pulse 90. Patient could not move her lower extremities and the urine escaped without the patient's knowlege. Albumin in the urine abundant.

Recovery was uneventful though slow, the temperature rising on May 7 to 100.4 with slight headache, pulse 100. May 23, urine normal in amount for the twenty-four hours with only a trace of albumin, patient anemic. June 24, the patient left the hospital in fair health. Traumatisms healed by granulations. The fetus, female, combined weight 11½ pounds, of nearly equal size and perfectly developed to the umbilicus. Celosomic; the liver of the second sacro-posterior fetus small and deformed, protruded into a sac formed of part of the transparent membrane enclosing and common to both abdomens.

Umbilical cord eighteen inches in length; "fat," was attached to the abdomen of the second sacro-posterior fetus at or near the outer angle of the abdominal junction, which formed a sharp groove similar to that formed in a dress shield, and on the margin of the incompleted abdominal wall. At the umbilical site of first sacro-anterior fetus was an anus-like opening guarded by a few scattering stiff and short hairs resembling the rictus bristles of a bird. This proved to be the opening of the urachus, developed and serving the purpose of a urethra, there being no urethral opening in the natural or normal situation, the bladder ending in a blind pouch, the bladder receiving two ureters in a normal manner, one from a

kidney of each fetus. There was only a vaginal orifice unsphinctered and guarded by a loose fold of tissue bearing little or no resemblance to normal structures. Vaginal canal large and received the single cervix of a two-horned uterus; ovaries and tubes normal; kidneys two in number, right kidney normal in size and location, left lobulated and situated in the hollow of the sacrum; second sacro-posterior fetus possessed three kidneys, the left situated lower than normal, while a second rested upon the promontory of the sacrum to the right of its median line, its convex outer border looking to the left as if a left kidney had slipped down from its place. The third and right kidney was undeveloped, with a helix that received blood vessels but gave off no ureter. The bladder received two ureters, one from a kidney of each fetus as in the preceding case. The meatus urinarius opened normally into a fairly developed vestibule that is guarded by two folds. Nymphæ minoræ that hooded a well developed clitoris. The labia majora are loose rudimentary folds bearing some resemblance to the normal structures. The vaginal canal is large, and receives a double cervix of a two-horned uterus, but one cervical os. Ovaries and tubes are normal. In both cases the ovaries of each uterus rested, one in the pelvic cavity of one fetus; its fellow in pelvic cavity of the opposite fetus. Both uteri were two-horned. The bladders are located in front of the uteri and the rectum descended between them in relation to the posterior surface of each.

Intestinal canal: Small intestines in two sets, one for each fetus. Until near the cecum they united

forming a large intestine or colon; sigmoid flexure and rectum common to both.

The appearance of the external parts are peculiar. The coccyx of each protrudes, forming a process about the size of a filbert. In normal relation to each is an anal depression or pit, directly between which is located a perfect anus common to both children. To the right and left of the perfect anus are the rudimentary pudenda. The extremities, upper and lower, are well developed and the heads well shaped.

DISCUSSION.

Dr. JOSEPH B. DELEE—This is a very interesting and unusual monster, the termination being favorable to the patient. When we consider the immense amount of dystocia monsters like this can cause, and the difficulties attending diagnosis and treatment, we can not but congratulate the Doctor. It is a peculiar fact that double monsters are said to cause much less dystocia than single ones. Professor Hohl in 1850 collated the statistics on the subject and found that 55 per cent. of single monsters caused dystocia, while only 38 per cent. of double monsters caused it. One reason is that single monsters are so likely to have displacements, such as transverse and other positions, and a large number of this class of monsters is due to hydrocephalus and enlargement of the abdomen or other cavities. Whereas double monsters will abort frequently, single monsters go to term. I remember in Berlin to have seen an abortion of three months in which there was a perfect miniature representation of the Siamese twins. The two fetuses were united together at the xyphoid appendix. In regard to the diagnosis of the double monster, there is hardly a case in which a diagnosis of it is positively made before labor. The majority of cases have gone to labor, and only when there has been obstruction has a diagnosis been made. Even then, a number of cases are difficult to diagnose, particularly where there are twins, one across another, or the two heads entering the pelvis at once or two breeches. In a single monster the diagnosis is easier. I have seen a diagnosis made of anence-

phalus through the abdomen by determining the breech in the fundus and no head over the inlet.

The Doctor has dealt with the division of monsters largely from a pathologic aspect. What has interested me in studying double monsters is the clinic aspect, because it is more important to the practitioner. G. Veit has written a monograph on the subject. He divides monsters into three forms. First, those where fission begins on top. The top of the monster is divided into two parts, either two heads or two faces stuck together, or the division proceeding further down, so that there are two complete heads with either one or two arms on each side. The second division is monsters united by fusion: Craniopagus, either front or back, vertex or face, ischiopagus. I think the Doctor's case was an ischiopagus in which there was dystocia of a double monster. Being united end to end, the children should have been delivered one after the other but for some reason they became doubled up like an U and thus offered almost insuperable obstruction to labor. The third division comprises monsters with a point of union near the middle of the trunk. The fission is both from below upward and above downward. Example, the Siamese twins.

In the treatment of this form of dystocia the plan works nicely also. First group, fission at either end, for example, a diprosopus (two faces). Here you would do a version or craniotomy, it being simply the size of the part causing a mechanical disturbance. In general, breech presentation is more favorable in labor with monsters, because there is something to pull on. The second division of the first class, where the fission is from below, the dipygus, there being two to four legs. In general, traction on one or two legs will not bring the others down; you must get all there are and make traction on them.

The second class of monsters, where the bodies are joined end to end, seldom give trouble, as they slip through as a long cylindrical mass. This was the case of the ischiopagus monster exhibited in the museums here about six years ago.

The third division, the thoracopagi, the xiphopagi, give the most trouble. Since the band of union is often very movable it is possible to deliver one child by version and extraction and then the other likewise. Or in certain cases, bring down all four extremities, now deliver the rear child, then the other.

Generally, it is a bad plan to amputate the parts which are born; true you get more room, but it disturbs the relations of the parts and you lose a good handle on which to make traction.

DR. FRED. J. E. EHRMANN read a paper entitled

## PRIMARY SARCOMA OF THE TAIL OF THE PANCREAS.

Sarcoma has been found in almost all parts of the human body where mesoblastic tissue occurs. The frequency of its place of origin, however, varies greatly so that sarcomata in some locations are common, in others almost unknown. Thus primary sarcomata of the bones, eye, kidney, glands, brain, etc., occur with relative frequency, but primary sarcoma of the pancreas, for instance, is very rare. This statement is substantiated by our best known writers, some of whom emphasize their rarity; others make no reference to primary pancreatic sarcomata at all. Thus Ziegler[1] writes that such growths are extraordinarily rare and Orth[2] says that primary sarcoma of the pancreas is almost unheard of.

To show the relative frequency of tumors of different varieties occuring in the pancreas, I may refer to Segrè's[3] table of 11,492 autopsies with 132 pancreatic tumors, of which 127 were carcinomata, 2 were cysts, 2 were sarcomata, and 1 a syphilitic growth. Segrè fails to state, however, whether the sarcomata were primary or secondary.

Some of the reports leave doubt as to the real nature of the tumor. Thus E. H. Bartley[4] reported a case in 1880 of a patient who had vomited after meals,

1 Ziegler: Lehrb. d. sp. Path. Anat. 1892, 619.
2 Orth: Lehrb. d. sp. Path. Anat. 1887, i, 904.
3 Segrè: Schmitts Jahrb., Nov. 15, 1889.
4 Bartley: Annals Anat. and Surg. Soc. 1880, ii, 495.

complained of pain in the epigastrium and emaciated rapidly. The tumor was "a spindle-celled growth, probably a carcinoma of slow growth, a scirrhus cancer, or possibly a spindle-celled sarcoma." Bruen[5] in 1883 and C. Workman[6] in 1892 described tumors of the pancreas, leaving doubt as to their real pathologic nature.

In 1883 Chiari[7] reported a fair-sized sarcoma of the pancreas, but considered it secondary. The patient was 43 years old, and the tumor is described as "a globular tumor in the head of the pancreas, soft, fragile, brownish-black, within a 2 mm. thick capsule through which the tumor-mass protruded here and there. There was also a brownish tumor in the omentum, in the fossa iliaca sinistra, and in the left eye, which probably was the primary tumor." Microscopically the tumor consisted of spindle cells with brown pigment.

Litten[8], however, is the first one to report a primary sarcoma of the pancreas. This occurred in a boy 4 years of age, who complained of tenderness over the abdomen and occasional diarrhea. On examination a tumor, which filled the entire abdomen, was visible through the abdominal wall. Nothing is said of the exact location in the pancreas of this tumor. Microscopically he found a small, round-celled sarcoma.

In the following year Briggs[9] reported a case where bloody vomit, fatty stools, emaciation, ascites and a fixed epigastric tumor existed. The ascitic fluid was alkalin, turbid dark brown, of 1012 sp. gr. The pan-

---

5 Bos. Med. and Surg. J., 1883, cviii, 110.
6 Glasgow M. J., 1892, xxxvii, 385.
7 Virchow: Hirsch Archiv, 83, ii, 211.
8 Deutsche Medizin. Zeit. Oct. 22, 1889.
9 St. Louis M. and S. J., 1890, lviii, 154.

creas, which was removed by operation, was examined with the following result: "A sarcoma, although there is evidence of a preëxisting hydatid shown by the hooklets of the affection, with the cells of a spindle-celled sarcoma." In 1892 Garda y Mansilla[10] also reported a sarcoma of the pancreas.

Of these seven cases the diagnosis is exceedingly doubtful in three; in the remaining four sarcomata existed and of these two were primary, one possibly primary and one secondary.

It will have been noticed that where the location of tumors has been specified the head of the pancreas was their seat. The case of which I make a report is a round-celled sarcoma of the tail of the pancreas. The history is as follows:

A. G., a German widow, 56 years of age, a washerwoman, resident of the United States for thirty-two years; had had a sense of weight in her epigastrium, frequent attacks of anorexia and occasional dyspnea for two years. Weakness gradually progressed so that she had been almost completely incapacitated for work some months before her admission to the hospital, on Sept. 15, 1895. Three weeks before admission a dull, continuous pain began in the epigastrium accompanied by a slight cough with frothy expectoration, a dull pain over the anterior surface of the chest, aggravated on deep inspiration, constipation, pollakiuria and dysuria.

The family history was negative. She had had typhoid fever twice. She had given birth to three healthy children; never had a miscarriage nor any puerperal fever.

The examination made the day following the day of admission, showed the following: Mind clear; skin dry and subicteric; nourishment fair; eyes sunken, pupils equal and reacting to light and accommodation; tongue heavily coated with somewhat dry margins.

Heart: Apex beat plainly visible in the fourth interspace, somewhat to the right of the left mammary line; the beat

[10] Garda y Mansilla: Progresso med. e farm., Madrid, 1892, i, 77.

fairly strong on palpation. The right border of the heart was at the middle of the sternum, the upper border in the second interspace, the left border at the mammary line. The sounds were muffled, but no murmur could be heard.

Lungs were resonant and the breath sounds audible all over, except below the ninth rib posteriorly on the right side. There were few crepitant râles in the axillary region of the left lower lobe. The epigastrium was more prominent than normal and quite tender.

Liver extended from fifth rib to a point four finger breadths below the costal arch in the right mammary line, and reached beyond the left mammary line to the left. Palpation revealed a hard, nodular border near the right iliac crest, whence it could be followed to a point about an inch above the umbilicus, where a large notch was present. From this point the border descended to the left to a level with the umbilicus and continued on this level beyond the left mammary line. The entire margin moved with inspiration. Beneath this edge to the left of the umbilicus there was a distinct, firm, tender mass, about the size of a chicken's egg, which did not descend on inspiration and could not be displaced upward.

The bones of the body were negative. The glands of the lymphatic system were not enlarged and no edema existed.

On admission the temperature was 100.6 degrees F. and four hours later reached the highest point recorded, 102.8 degrees. The respirations varied from 30 to 36 and the pulse from 96 to 120. Preceding her death, which took place on Sept. 25, 1895, the temperature became subnormal. No sugar was found in the urine and the feces were never examined.

The postmortem examination was made sixteen hours after death. The body was fairly well nourished; skin subicteric; there was the usual posterior lividity in moderate degree.

The heart was larger than its owner's fist and flabby; subepicardial fat was abundant on the anterior surface and along the course of the vessels petechiæ were to be seen. The mitral orifice admitted three finger tips, the tricuspid four. Both semilunar valves were found competent to the water test. The free margins of the aortic valves were thickened. The left ventricle was 7 cm. deep and its wall measured 1.5 cm. in thickness on the average. The right ventricle

was 8 cm. deep and its wall averaged a thickness of 3 mm. The myocardium was pale. The aorta was slightly dilated, the intima thickened in areas.

The pleural cavities were free from adhesions. The right contained about 6 ounces of clear, straw-colored fluid. On the visceral pleuræ of both lungs there were quite firm, whitish areas of about 2 mm. diameter. The lungs had pale, translucent margins and contained a quantity of frothy fluid. The right lung was adherent to the pericardium.

The peritoneal cavity contained a considerable quantity of straw-colored fluid. The peritoneum was smooth and shiny.

The liver reached almost to the right iliac crest and almost to the umbilicus in the midian line. It weighed 5590 gms. It measured 35 cm. from right to left; the right lobe measured 32 cm. from above downward, while the left measured 22 cm. The liver was 13½ cm. thick. A deep and wide furrow extending transversely over the anterior surface of the right lobe permitted of great mobility of the lower one-half on the upper. The surface of the liver was grayish and was studded with slightly raised, firm areas, varying from the size of a pea to that of a walnut. Similar areas were found throughout the parenchyma of the liver; some were pale and hard, others had a dark periphery and a softened, pale center and all could readily be peeled out.

The stomach was completely covered by the liver. At the cardiac end it was adherent to a tumor-mass behind and below it. Its wall was not infiltrated as far as could be seen with the naked eye, and its mucous membrane was normal. The intestines were normal.

The tail of the pancreas merged into a tumor-mass situated in the region of the left suprarenal capsule. After the organs of this region were taken out *en masse* it was found that the kidney, suprarenal and spleen could be readily and completely removed. The tumor was nodular, measured 7 x 7 cm. and was quite firm. The cut surface showed a pale lower half which was distinctly continuous with the pancreas; the upper one-half was of a pinkish color. The spleen was negative.

Both kidneys were of about normal size; the capsules were adherent; the cut surfaces were pale and the cortical markings

were indistinct. The renal pelves, ureters, bladder and suprarenal capsules were normal.

The uterus had a pedunculated, pea-sized body protruding from the os, which was connected with the cervix. The ovaries were hard and almost cartilaginous. The nervous system was not examined. Enlarged glands were found at the celiac axis.

The anatomic diagnosis was: Pulmonary emphysema and edema; fatty heart; atheroma of the aorta; adhesive pleuritis; chronic nephritis; uterine polypus; atrophic ovaries; primary tumor of the tail of the pancreas; secondary tumors of the liver and pleuræ; secondarily enlarged celiac lymphatic glands.

The microscopic examination showed the tumor in the tail of the pancreas to consist of small round cells without any definite arrangement, imbedded in a stroma which in places was very finely fibrillated, in others more coarse and fibrous. There were large vascular channels and areas of hemorrhage throughout the tumor. The nodules in the liver and the pleuræ showed the same structure.

*Conclusion:* In the foregoing has been described a small round-celled sarcoma of the tail of the pancreas with secondary tumors in the liver. It is believed that the primary tumor originated in the substance of the pancreas, because of the intimate connection between the pancreatic tissue and the tumor, which appears to be continuous with and to replace the structure of the pancreas. The tumors in the liver and pleuræ were manifestly metastatic and the logical conclusion would be that in the absence of any other primary tumor-focus this case will have to be interpreted as one of primary sarcoma of the pancreas.

On account of this very unusual location of the sarcoma, it was concluded that the case merited the forgoing brief report.

DR. GEORGE H. WEAVER read a paper entitled

## LIPOMA DEVELOPED IN THE UPPER END OF THE SEMITENDINOSUS MUSCLE.

This specimen is presented, not because of its being a lipoma, but since it is interesting from its location and considerable size. There is no clinic history of the case and the tumor was discovered accidentally in a subject in the dissecting room of Rush Medical College during the winter of 1893. A student called my attention to a swelling in the upper and posterior part of the thigh of a male subject, which he had not noticed until after the removal of the integument. As it appeared with the covering of fasciæ an abscess was suspected. There was a sensation on palpation suggesting fluctuation, which was felt transversely through the tumor, but not in the vertical direction. On dissecting down to the tumor it was found to be located in the semitendinous muscle at its upper end, extending from the insertion of the tendon to the tuberosity of the ischium downward. The muscle separated easily and naturally from the surrounding structures. The tumor was oblong, five inches long and three inches in diameter transversely at the center. Its surface was smooth and even, and covered everywhere by the fibers of the tendon and muscle, which had been uniformly spread out over the surface. On section it was found to be a lobulated lipoma. A small calcareous nodule was located in the upper part at some distance from the bone. Ziegler (Lehrbuch der Speciellen Pathologischen Anatomie, Jena, 1890) places lipoma of muscles among the uncommon tumors. Sutton (Tumors, Innocent and Malignant, 1893, Philadelphia) says that many exam-

ples of fatty tumors occurring in the midst of muscles have been reported and are of interest from the trouble they cause in diagnosis. He says they have been found in the deltoid, biceps, humerus, complexus and rectus abdominalis, in the muscular tissue of the heart and in the middle of a submucous myoma of the uterus. Senn (The Pathology and Surgical Treatment of Tumors, 1895, Philadelphia) says that lipoma inside the tendon sheath springs from the adipose tissue of the mesotendon, and that it usually develops as a multiple tumor which presents an arborescent appearance and is easily mistaken for tuberculosis of the tendon sheath and for flexiform neuroma. The present instance does not correspond to the variety described by Senn, and does not differ in its appearance from a lobulated lipoma in the subcutaneous tissues. From its deep location and the sensation of fluctuation imparted to the fingers on palpation, it might readily have been mistaken during life for an abscess.

## Regular Monthly Meeting, October 12, 1896.

The President, Dr. James B. Herrick in the Chair.

Dr. Geo. H. Weaver read a paper entitled

# THE BACTERIOLOGIC CONTAMINATION AND THE PRESERVATION OF VACCINE LYMPH—GLYCERIN AS A BACTERICIDE.

The present communication is the outcome of observations made during the past two years, at the request of vaccine propagators, regarding the best methods of preserving vaccine lymph. It is our purpose to refer briefly to the contaminations by bacteria occurring in bovine vaccine lymph with their effects and to the measures which have been found useful in preserving the virus. No reference will be made to humanized lymph, as the danger of syphilitic infection through its use has practically stopped its employment.

The bacterial contaminations may be divided into two classes: The saprophytes or non-pathogenic, and the parasites or disease-producing. The former are of moment, because by their presence and growth the virus is decomposed and by some at least is robbed of its specific property. The pathogenic variety may cause various disease processes in the human subject when virus containing them is employed for vaccination.

Abundant observations have shown both of these varieties to be present almost constantly in the lymph dried upon ivory points, as well as in fluid

lymph to which no preservative has been added. The cloudiness of such vaccine lymph after keeping a short time has been found to be due to the growth of saprophytic bacteria. Fütterer examined seventy-five ivory points from different sources and found the staphylococcus aureus in about fifty-five, the staphylococcus albus in about the same number, and the streptococcus of erysipelas and phlegmonous inflammations in ten. The pyogenic staphylococci have been found frequently by other observers (Woitlow, Grigoriew, Straus, Copeman and Crookshank). The streptococcus has been found less frequently (Copeman, Woitlow). Reed examined vaccine points from six vaccine farms and found the staphylococcus albus and aureus in all the plates. We have made cultures from four different makes of ivory points which are sold in largest numbers in the Chicago market. They were obtained as fresh as possible in the original packages. In every instance they proved to contain large numbers of bacteria, and in those from each source the pyogenic staphylococci were found. Fluid lymph from a prominent firm was cloudy and contained innumerable bacteria.

The culture you see here was made from an ivory point purchased in the Chicago market recently. It was removed from the original package with sterile forceps, dropped into the liquefied nutrient agar-agar at 45 degrees C., and after standing a few moments the agar was poured into a sterile Petri dish. You see the large numbers of colonies of bacteria present.

The almost universal presence of pyogenic bacteria in virus furnishes a reasonable explanation of the common suppurative, phlegmonous and erysipelatous

inflammations following vaccination. Whether other varieties of pathogenic bacteria are at times present in vaccine lymph is not certainly known. Abundant cases of tetanus following vaccination have been reported in medical literature. It is not difficult to imagine that the tetanus bacillus may gain entrance to the lymph where proper precautions are not taken in its collection, as it is so commonly found in the dust and refuse about stables. It is not known whether the tubercle bacillus can enter the lymph from a tubercular animal. E. Peiper refers to the report of Toussaine, in which he claims to have produced tuberculosis in a rabbit by inoculation with virus from a tubercular cow. Peiper vaccinated sixteen phthisical persons and could not find tubercle baccilli in the lymph after most careful search. Josef Acker concludes that no tubercle bacilli are found in the vaccine vesicles of tubercular individuals before or after the seventh day. It is hardly fair to conclude from these observations on human subjects that the same would hold good in the cow. However this may be, the danger from tubercle bacilli can be eliminated by using animals only after the absence of tuberculosis has been demonstrated by the use of tuberculin. We have not been able to find any cases recorded of infection with anthrax or glanders by vaccine lymph.

Knowing of the frequent presence of certain pathogenic bacteria in vaccine lymph, we naturally demand a preparation in which they are not found if we expect to have typical vaccinations and to avoid severe if not fatal sequelæ. Evidently it would be desirable to obtain sterile lymph, unmixed with any preservative or foreign material. To learn whether this was prac-

tical, we made inoculations on 5 per cent. glycerin-agar-agar from the surface of vaccine sores of six cows on the fifth day, after they had been thoroughly cleansed by washing with soap and water, followed by solution of $HgCl_2$ and sterilized water. The inoculations were made by scraping the surface with a heavy platinum needle. From two cows, cultures of the staphylococcus aureus were obtained with an unidentified bacillus, from two a streptococcus corresponding in all its cultural properties to the streptococcus pyogenes, from one an unidentified bacillus, and one was sterile. All the sores were typical. These observations convinced us that it was useless to hope to obtain primarily sterile lymph, especially as the operators are not usually well skilled in antiseptic technique. Surgical wounds when managed according to the most careful antiseptic and aseptic principles have been found at the end of operations to contain a few bacteria. In a healthy wound these are destroyed by the wound secretion or tissue cells. In vaccine lymph, however, this is not the case, but a good nutrient material is furnished for their growth.

Various measures have been employed, at first empirically and later for scientific reasons, to preserve the activity of vaccine lymph. It was found by Carsten and Coert, in 1875, that sufficient heat to destroy the bacteria in lymph was also enough to destroy the vaccinal principle.

The method of Reissner was to obtain lymph, dry it over sulphuric acid and reduce it to a powder. The dry powder was found to preserve its properties up to twenty-nine days, and in later observations for a much longer time. The drying effectually prevented

the growth of saprophytic bacteria, but did not injure the specific agent of vaccinia. This method became very popular and yielded good results.

Pissin pulverized the crusts and made a mixture with glycerin and salicylic acid water, which he stored in capillary tubes. This remained virulent as late as three weeks, as long as tested. Other observers have found it active for much longer periods.

Attempts have been made to preserve the lymph by adding various chemicals. R. Pott experimented with salicylic, boric and carbolic acids, and thymol. He concluded that after a time they injured the virus and did not in any way conserve the lymph.

The use of glycerin was placed upon a rational basis by the observations of Copeman, Chambon and Ménard and Straus. They found that the lymph diluted with glycerin at first contained more or less numerous bacteria of various kinds, but that the glycerin prevented their multiplication and in a few days lead to the death of most of them. Lymph from the same source to which no glycerin was added and which contained only the same proportion of bacteria primarily, in a few days was swarming with bacteria. With the growth of the bacteria the vaccinal properties of the lymph was destroyed. The addition of glycerin did not in any way lessen, but rather enhanced the activity of the virus. Chambon and Ménard found that while fresh lymph might produce bad results, if kept two weeks and later typical pustules were produced.

King obtained with lanolin similar results to those with glycerin.

We have repeated these examinations in a series of

twelve samples of lymph. In each case lymph was obtained as soon as possible after being taken from the animal, with all precautions to prevent contamination. It was placed in capillary tubes, part in the pure state, part after being mixed with pure glycerin or equal parts of glycerin and distilled water. The pure lymph always contained a few bacteria in a few hours (three to six in a tube) and in from three to five days became cloudy and contained innumerable bacteria. In the lymph diluted with glycerin a few bacteria were also found at first, but as it was kept they became gradually fewer and disappeared in from eight to thirteen days. An exception occurred in one lot of lymph in which the bacillus subtilis was obtained in cultures after twenty-four days, but it did not increase in numbers. The glycerin lymph always remained perfectly clear and transparent as long as kept. Whether pure glycerin or equal parts of glycerin and water were used did not appear to alter the results. Virus from several of the lots was tested as to its vaccinal properties after it had become sterile up to as late as one month, with the result that it produced typical pustules. The percentage of glycerin did not appear to modify its effect.

There are here a series of cultures made from lymph taken Sept. 18, 1896. The lymph was placed in capillary tubes, part in a pure state and part after diluting with glycerin. We have made cultures from each at intervals, and you see the results. Those from the pure lymph show a few colonies in the culture made thirty-six hours after the lymph was taken from the animal, and the colonies rapidly increase until on the seventh day they are innumerable. The earlier cul-

tures from the glycerin lymph also show a few colonies, but these become less in number in the later cultures, until on the fifth day none are found. You will also note the difference in the appearance of the lymph in the two capillary tubes; the pure lymph has become cloudy; the glycerin lymph remains perfectly transparent.

A series of experiments was also undertaken to determine the action of glycerin upon pure cultures of various bacteria. The forty-eight hour growth upon agar-agar of the bacteria in question was introduced into test tubes containing sterile glycerin and equal parts of glycerin and water. Control tubes containing a sterile solution of sodium chlorid were employed, the same cultures being introduced at the same time. All the cultures of pathogenic bacteria were virulent. At intervals inoculations were made from these upon nutrient agar-agar. The effects of the pure glycerin and glycerin and water did not differ. The staphylococcus aureus was dead in from five to twenty days. Where the longer time was required a very large amount of culture was introduced into the glycerin. The streptococcus pyogenes was dead in five days, even if introduced in considerable quantity. The bacillus mallei was dead in two days. There was little or no effect upon spores. The subtalis bacillus grew for a month (as long as tested), and the anthrax bacillus was viable and virulent after five months.

From these experiments we may conclude that glycerin has a distinct germicidal action upon many free bacteria, destroying most of those of a pathogenic nature likely to be found in vaccine lymph inside of two weeks, but having little or no effect upon spores.

Copeman, in 1893, states that he found that while some pathogenic organisms remain active in admixture of broth and glycerin, or even pure glycerin, for longer or shorter periods, other pathogenic and, so far as his experiments go, all saprophytic organisms, are killed out in from three or four days to as many weeks. The practical application of these facts and observations are easy. Until we know what the active agent of vaccinia is, and can obtain it in pure cultures, we must depend upon the cow for propagation of our virus. If we can procure a virus which is free from bacteria, it is our duty to use it. Such a virus is found in the glycerin lymph, and is being offered to the profession by many vaccine propagators. One objection urged against it is that it is slow to dry, but the element of time is of no vital moment. How much time is lost by persons going about with an arm in a sling for days? It would be as consistent to object to aseptic surgery from the same standpoint. With a sterilized field of operation and a proper protective dressing, secondary infection in the vaccine-wounds would be extremely rare.

The ivory point, as at present prepared, should be discarded. They can not be obtained free from bacteria. The practice of supplying vaccine points to druggists to retail and handle with septic hands is especially pernicious.

It is not our purpose to discuss the technique followed in vaccinating cows and in obtaining the serum. It is sufficient to state that the lymph used to inoculate the cows should be preserved as if to be used for human vaccination ; that the operating room should be cared for in the same way as one used for surgical

purposes; and that the seat of inoculation, the hands of the operator, and all instruments and vessels used should be carefully rendered aseptic. The vaccine sore should be made as nearly free from bacteria as possible before the lymph is collected, and the vessels in which the serum is received and the capillary tubes in which it is stored should be rendered sterile by heat. We may briefly summarize as follows:

1. Vaccine lymph in a fresh pure state almost always contains bacteria, and often pathogenic forms.

2. Pure vaccine lymph after keeping in a fluid state, or dried upon ivory points as now prepared, is unfit for use and often dangerous.

3. Vaccine lymph diluted with pure glycerin or equal parts of glycerin and distilled water, becomes sterile in about two weeks, and should not be used sooner.

4. All animals used for propagating vaccine lymph should be tested with tuberculin before being used.

5. All vaccine establishments should be regularly inspected by properly qualified officials, and samples of virus from each lot of vaccine examined bacteriologically by a competent person and the result certified before it is placed upon the market.

6. Each package of vaccine lymph should be so marked that the date on which it is taken, and, if fluid, what has been added to it, shall be shown.

In conclusion, I desire to express my thanks to Prof. Walter S. Haines for valuable suggestions and to Dr. E. M. Wood for kindly furnishing material for carrying out part of these experiments.

LITERATURE.

Abbott, S. W.: "Radical Difference in the Methods of Production and Cultivation of Vaccine Lymph." The Sanitarian, 1894, xxxiii, p. 414.

Acker, Josef: "Die Uebertragbarkeit der Tuberculose durch die Vaccination." Centralblatt für Allgemeine Gesundheitspflege, 1884, iii, p. 421.

Börner, P.: "Die Versuche im Kaiserlich Deutschen Gesundheitsamte über die Conservirbarkeit der Animalen Lymphe." Deut. Med. Woch., 1882, viii, p. 357.

Carsten and Coert: Ref. Handbook of Med. Sci., p. 548.

Carmichael: "Microbes of Vaccine." Lancet, Jan., 1888.

Chambon, Ménard and Straus: "Epuration de la Pulpe Vaccinale Glycérinie." Bulletin de l'Acad. de Médecine, Dec. 6, 1892, and Bulletin de la Société Centrale de Médecine Vétér., xlvi, p. 748.

Copeman, S. M.: "The Bacteriology of Vaccine Lymph with Special Reference to an Improved Method for its Storage and Preservation." Brit. Med. Jour., 1893, Vol. i, p. 1256.—"The Bacteriology of Vaccine Lymph." Trans. of the Seventh International Congress of Hygiene and Demography, 1892, Vol. ii, p. 319.—"Variola and Vaccinia, their Manifestations and Inter-relations in the Lower Animals." Jour. Path. and Bact., 1894, Vol. ii, p. 407.—"Pathology of Vaccinia and Variola." Brit. Med. Jour., Jan. 4, 1896, p. 7.

Crookshank: "On the Bacteriology of Vaccine Lymph." Trans. of the Seventh International Congress of Hygiene and Demography, 1892, Vol. ii, p. 326.

Doebner: "Ueber Impfung mit Reissner'schem Impfpulver." Aerztliches Intelligenzblatt, 1884, xxxii, p. 360.

Edson, Cyrus: "The Propagation and Preservation of Vaccine Virus." N. Y. Med. Record, 1892, Vol. xlii, p. 391.

Fickert: Deutsche Vierteljahrschr. f. öffentl. Gesundheitspflege, Bd. 61, p. 425.

Fischer: "Worin liegt die Schwierigkeit der Fortzüchtung der rein Animalen Lymphe von Thier zu Thier, und wie lässt sich die selbe beseitigen?" Münchener Med. Woch., 1891, p. 661.

Fütterer, Gustav: "Our Vaccine Points." Chicago Med. Recorder, 1895, Vol. viii, p. 399.

Gilbert, D. D.: "The Production of Vaccine Virus." Boston Med. and Surg. Jour., 1894, cxxx. p. 434.

Grigoriew, A. W.: "Ueber Mikroorganismen bei Vaccine und Variola." Baumgarten's Jahresbericht, 1889, p. 361.

Hirschberg: "Versuche mit Conservirter Animaler Lymphe nach Pissin und Reissner." Deut. Med. Woch., 1882, viii, p. 455.

King: "Notes on Lanolin Vaccine." Indian Med. Rec., Calcutta, 1891, ii, pp. 147, 528.

Martin, S. C.: "The Inoculation, Propagation and Preservation of the Virus of Animal Vaccine." Jour. Amer. Med. Assn., 1885, v, p. 663.

Meinel: "Die Mailänder Methode der Animalen Vaccination, etc." Deutsche Vierteljahrsschr. f. öffentl. Gesundheitspflege, Bd. 16, p. 276.

Meyer: Vierteljahrsschr. f. ges. Med., 1888.

Pécsi: "Eine Neue Methode der Conservirung des Thierschen Vaccineimpstoffer." Ref. Archiv f. Kinderheilkunde, 1888, Bd. ix, p. 70.

Peiper, E: "Zur Frage der Uebertragung der Tuberculose durch die Vaccination." Internat. Klin. Rundschau, 1889, 8, 8.

Pfeiffer, L.: "Die Rückimpfung auf Kühe als Mittel zur Allgemeinen Einführung der Animalen Impfung ohne Besondere Staatliche Lymphe-Erzeugungsamstalten." Separat abdruck aus der Deutschen Vierteljahrsschrift f. öffentliche Gesundheitspflege, Bd. xi, Heft. 4,—"Die Impfung, die Conservirung der Lymph." Gerhardt's Handbuch der Kinderkrankheiten, Tübingen, 1877, p. 614.—"Die Bisherigen Versuche zur Reinzüchtung des Vaccinecontagium und die Antiseptik der Kuhpockenimpfung." Zeit. f. Hygiene, 1887.

Pitfield, Robt. L.: "Report on the Vaccine Farms and Antitoxine Propagating Establishments of the United States, and their Products, and on Certain Imported Antitoxins." Public Health, Vol. i, No. 8.

Pissin: "Zur Conservirung der Animalen Vaccine." Berl. Klin. Woch., 1881, No. 44, p. 651.—"Ueber einige Controversen in Bezug auf die Animale Vaccination." Berl. Klin. Woch., 1884, xxi, p. 544.

Pott, R.: "Impfversuche mit Aseptischer Vaccinalymphe." Jahrbuch f. Kinderh., 1881-2, xvii, pp. 172, 177.—"Ueber die Einwirkung verschiedener Antiseptica auf die Schutzpockenlymphe." Arch. f. Kinderheilkunde, 1883, iv., p. 407.

Protze, Hermann: "Ein Beitrag zu dem Erfolg Flüssiger Animaler Vaccine." Deut. Med. Woch., 1885, xi, p. 257.

Reed, Walter: "What Credence Should be Given to the Statements of Those who Claim to Furnish Vaccine Lymph Free of Bacteria." Read before the Medical Society of the District of Columbia, May 29, 1895.

Reissner: "Ueber eine einfache Methode zur Aufbewahrung Thierschen Impfstoffs, als Grundlage einer Allgemeinen Einführung den Animalen Impfung." Deut. Med. Woch., 1881, vii, p. 409.

Schenk: "Zur Conservirung der Animalen Lymphe." Berl. Klin. Woch., 1885, xxii, p. 267.

Sternberg, Geo. M.: "Scientific Researches Relating to the Specific Infectious Agent of Smallpox and the Production of Artificial Immunity for the Disease." Jour. Amer. Med. Assn., 1896, xxvi, p. 919.

Tenholt: "Die Bacterien der Kälberlymphe." Correspondenzblatt d. ärztl. Vereins in Thüringen, 1887, ix, p. 471.

Swarts: "Report of Committee of Conference of State Boards of Health on Vaccine Farms." Proceedings at the Tenth and Eleventh Meetings of the National Conference of State Boards of Health, 1896.

Uffelmann, J.: "Das belgische Landesimpfinstitut und die von demselben befolgte methods der Gewinnung Conservirung und Versendung der aninalen Lymphe." Berl. klin. Woch., 1885, xxii, p. 367.

Voigt, L.: "Beitrag zur Abschaffung der humanisirten und zur alleinigen Verwendung der Animalen Impflymphe." Deut. Med. Woch., 1885, No. 12.

Warlomont, E.: "Remarks on the Different Methods of Collecting, Preserving and Employing Animal Vaccine." Brit. Med. Jour., 1880, ii, p. 499.—"Animal Vaccination in its General Relations with Vaccination and Revaccination." Brit. Med. Jour., 1881, ii, p. 767.

Wesche: "Die Animale Impfung in Herzogthum Anhalt." Deut. Med. Woch., 1887, viii, p. 67.

Woitlow, A. J.: "Ueber das wirksame Princip der Vaccine." Inaug. Diss., St. Petersburg, 1890; Abs. in Baumgarten's Jahresbericht, 1890, p. 42.

Wolffberg u. Schmidt: "Eine Modifikation der Reissner'schen Methode zur Gewinnung animalen Impfstoffe, etc." Berl. klin. Woch., 1886, xxiii, p. 835.

Dr. Hugh T. Patrick made some remarks on

ARTEFACTS IN THE EXAMINATION OF THE NERVOUS SYSTEM,

with demonstrations.

I wish to call attention this evening to a few things that might lead us to false conclusions in making a microscopic examination of the nervous system, and which might allow us to accept the false conclusions of others as found in their writings. As my time is restricted, I shall limit the subject entirely to the examination of the spinal cord, and shall touch upon only a few of the principal artefacts found in such examinations. By an artefact I mean an accidental artificial product. Of course, the red carmin stain is strictly speaking, an artefact, but we understand what the red means, we cause it on purpose and do not class it as an artefact. Some of these accidental productions are, I think, not entirely understood by some men who do microscopic work, but do not do a great deal of work on the nervous system, and I think attention ought to be called to this. In justification of this assertion, I might mention a recent article which appears in what is perhaps, the best neurologic journal that we have, namely, the *Deutsche Zeitschrift für Nervenheilkunde*, in which the author describes the microscopic appearances of the cord in a case of pernicious anemia. From his findings the author attempts to overturn all pre-established pathology of the changes which take place in the cord in pernicious anemia. Judging from the description of the histologic changes, and from the one cut or illustration of the entire cord section, the lesions on which the author bases his difference of opinion from previous investigators are as palpable artefacts as can be produced. Anyone acquainted with the subject would recognize the greater part of the pathologic findings as artificial products having no connection with disease. There is a peculiarity in this unaccounable scientific blindness. The author even alludes to a fissure which runs into the cavity, which he describes as a pathologic product, and says that this fissure may be due to injury of the cord in removing it. He does not seem to think of the possibility that the entire pathologic finding in the gray matter might also be due to postmortem injury.

One of the first things in the examination of the cord is artificial heterotopia, which means the malplacing of the various histologic elements. A number of cases have been described as being due to congenital defect. Great credit must be given to an American pathologist, Van Gieson of New York, who was the man to show that nearly all, if not all, of these cases are due to postmortem injury. His conclusions and findings have never been disputed. In these cases there are a number of deformities, several varieties of which I have set up under the microscope. You will observe one section in which the posterior horn is missing; another section in which most of the anterior horn is missing, and two or three other cases in which there is marked deformity of the gray matter. I would say that these artefacts are apt to affect particularly the gray matter, because it is less resistant, whereas the white matter may not show any results of injury at all. While you may find marked microscopic changes, there may be nothing abnormal to be seen by the naked eye. How are we to tell that a certain deformity is an artefact, that is not due to disease or to congenital malformation? In the first place, evidences of acute disease, or of acute inflammation, of proliferation of cells, of nuclei, certain vascular infiltrations, are absent. In the second place, evidences of chronic disease, proliferation of neuroglia, the symmetrical disappearance of nerve fibers and a thickening of vessel walls are absent. Next as to positive evidence of postmortem injury of the white matter of the cord. When we make a cross section of the diseased or normal spinal cord we cut the fibers of the white matter transversely. We have for each fiber the axis cylinder surrounded by the myeline sheath, and a cross section of the white matter means a collection of these, close together in normal cords, separated by neuroglia in sclerosis. Of course, there are all sizes of fibers in the spinal cord. In the case of an artefact, instead of having a symmetrical, nicely cut cross section, the fibers may be strung out in strands, or they have a peculiar slanting appearance. Instead of being round they are oval, showing that they have been cut in a slanting way. In many instances a number of fibers loop around a vessel. It is evidence that in the postmortem violence to the cord the vessel has been drawn athwart the less resistant nerve fibers, which have looped about it, like sea-

weed about a taut fish-line. Within the loop and, so to speak, behind the vessel is an area in which there is very apt to be a homogeneous substance, the nature of which I do not know. It takes all stains poorly. I have seen it repeatedly described as an exudate, or as a transudate, the result of various changes which never existed.

Another thing is the so-called rarefaction of white tissue in the cord, which practically does not exist antemortem. There is scarcely such a thing as rarefaction due to disease. I have set up a couple of slides illustrating this. If you take a section in a case of postmortem deformity you are pretty sure to find so-called rarefaction, and it means, in the first place, that the fibers do not stain well when torn. Then the fibers instead of being close together are separated by large intervals which are not filled with neuroglia tissue or infiltrated cells. This can scarcely be anything but an artefact. These interspaces are irregular and the fibers themselves are irregular, but you can judge better what they are like by looking at the specimens.

Another thing that is frequent as an artefact, and which is easily understood, is pulling out of the posterior root fibers in the cord, which make an apparent degeneration of the zone of Lissauer. This zone has peculiar fibers, is important pathologically, and I have seen it described in various reports as degenerated, when there was no apparent reason for it. The posterior root has been given a pull, say in removing the cord, and as many of the root fibers enter close to and through Lissauer's zone, the fibers of the latter are disarranged and lacerated and consequently do not stain well.

Another thing that is frequently described as degenerated is the subpial layer around the cord, the periphery of the antero-lateral tract. In the absence of meningitis, this is nearly always an artefact. If the cord be exposed for a long time before putting it into the hardening fluid, this outer layer will suffer. If the hardening fluid has not been good and the cord become partly decomposed, or if the sections are not properly handled, this area often changes; therefore it is called degenerated when the true evidences of degeneration do not exist.

Speaking of poor staining; the sections do not always stain uniformly. It may be impossible to say why. One section lies upon another in some cases, or the sections are folded over, and

consequently stain irregularly. The resulting pale patches or streaks have been described as pathologic, when the only trouble was that the stain did not take well. This is especially true of the carmin stain which is perhaps most generally used. The Weigert stain, also much used, may give a black patch, which does not differentiate well, and may hence be called degenerated. When the material has not been hardened well it is apt to stain irregularly and poorly, and hence false conclusions may be drawn.

Again, rarefaction and vacuolation of nerve cells hardly ever exist. Groups of pigment in ganglion cells, which are quite normal, do not take stains well and are called vacuoles and granules and various other pathologic things. It takes a very successful stain of any kind to get the processes of ganglion cells well, and the disappearance of the processes is often attributed to some disease, when it is due to nothing but a poor stain. I have set up but one example of this. You will notice four or five cells in the field in which there is scarcely a process or a nucleus to be seen, and the cells also look granular. It is simply a poor carmin stain, the result of imperfect hardening or the age of the specimen.

In the article I have previously referred to there were cavities described in the anterior horns, as well as a peculiar condition of the gray substance. Cavities in the gray matter, as a result of postmortem staining, are not very rare. I have set up three slides showing this. One of them is from a rabbit the cord of which I took out myself. The cord shows all the marks of an artefact, a cavity in the gray matter, some twisted strands of fiber and artificial "rarefaction."

I have set up a section showing the loss of one of the posterior horns, and another similar Weigert stained section, showing the fibers occupying the position that the gray matter ought to occupy. Looking at this, you see that instead of being cut transversely as they should be, if the posterior horns were congenitally deficient, the fibers are all twisted into waving, irregular strands, which stamps the condition at once as an artefact.

DISCUSSION.

Dr. Ludvig Hektoen—Dr. Patrick's remarks call our attention to the importance of fully understanding the artefacts of the nervous system. Although I think some of the statements

are rather broad, yet we must acknowledge that these words of caution are timely and valuable. While artefacts of the nervous system are frequently mistaken for morbid changes, yet it may not be entirely amiss to say that care must be taken not to interpret obscure pathologic conditions as artefacts. One frequent method of producing very serious artefacts in the spinal cord occurs from the careless removal, either by reckless use of the chisel and hammer, which should be entirely avoided, or by twisting or bending, and it is particularly this class of artefacts and the resulting so-called heterotopia which Van Gieson has studied thoroughly.

In studying the spinal cord microscopically, it would always be well to so cut the cord as to have serial sections. This is the only way in which we can obtain an exact idea as regards the cells as well as a complete idea of the various cavities which may be encountered.

I have noticed the section upon which there is an absence of one horn. The question would be, What has become of the horn? It does not seem crowded into the other part of the gray matter, but it is completely absent from this section. Serial sections might throw some light on the subject.

Dr. Patrick makes the statement that the carmin stain is the one most generally used in doing microscopic work on the nervous system. I would take exception to that statement. The carmin stain is not used as frequently as some other stains, such as the Weigert stain, and I can see no good reason why it should be used as much as it is even at the present time.

Dr. E. R. Le Count—I would like Dr. Patrick to give us some directions concerning the removal of the cord so as to prevent the production of artefacts.

Dr. Patrick—In answer to the last question the method is simply to remove the cord with extreme care, avoid using chisel and hammer and never pull on a nerve root before it is completely cut. Never hang the cord up with a string, never lay it down to harden on a hard surface; lay it on cotton and have cotton between it; never bend or twist it; never put anything on top of it. Be careful in cutting and opening the membranes; in other words, treat it with the greatest possible delicacy. These are simple general directions. One of the most important directions of all is not to trust the removal of the

cord to an incompetent assistant, especially to some supernumerary about a hospital, who does not care whether he gets the cord out in one piece or two. As regards Dr. Hektoen's remark, not to take a true pathologic condition for an artefact, the caution goes without saying.

With reference to what I said concerning the carmin stain being the most frequently used, he may be entirely right about that, as I have no statistics on the subject. I think I corrected myself by saying that the Weigert stain was used, perhaps, as much as the carmin for all purposes. I think the carmin stain is most frequently used for nerve tissue, taking all examiners together. The best men do not rely upon it, and I suppose Dr. Hektoen does not. It is one of the oldest stains and if the doctor will think he will remember that in scarcely any report is the carmin stain omitted. Some other stain is left out, but the carmin is always used.

To the question as to where the missing posterior horn in the section went, I should answer from the work of Van Gieson that it went either up or down. It is not in this section.

The longitudinal fibers of the cord within the white substance run parallel up and down, and it is not a difficult matter, as Van Gieson showed by experiments, to compress the cord without destroying the white fibers and thus squeeze the putty-like gray matter up and down. The white fibers reassume their original arrangement with the gray matter missing at a certain point. Serial selections, if carefully made, ought to reveal a decided difference. The point I wish to make is, that where there is such a deformity in the gray matter the white matter will show it to a knowing examiner. In illustration I have set up another section with the fibers stained, showing the abnormal arrangement of the fibers in the space where the gray horn ought to be.

Dr. James B. Herrick read a paper on

TRICUSPID STENOSIS.

Reporting two cases and exhibiting a specimen from the second case.

*Case 1*—A woman, 26 years of age, with no symptoms indicating heart disease during infancy or childhood, first noticed swelling of the feet, shortness of breath, palpitation, cough,

two months after giving birth to a healthy child, and seven months before admission to the Cook County Hospital. The physical examination revealed an enlarged right and left heart, a presystolic thrill over the apex, accentuated pulmonic tone, systolic apical murmur, systolic murmur over xiphoid, small, weak pulse. Died in one week.

Clinical diagnosis: Mitral stenosis and regurgitation, relative tricuspid insufficiency. Autopsy showed a heart hypertrophied and dilated in all its cavities. Mitral stenosis, the opening admitting one finger tip. Tricuspid stenosis, opening admitting two finger tips. No defect of the ventricular or auricular septa.

*Case 2*—Female, aged 24, bookbinder, rheumatism at 18; two years later a diagnosis of heart disease by physician. Four days before admission to County Hospital gave up work on account of weakness and shortness of breath. Death in one week.

Clinical diagnosis: Difficult on account of feeble action of heart. Autopsy revealed greatly hypertrophied heart, all the chambers enlarged. Muscular structure of the right auricle in particular shows extreme hypertrophy. No defects in the septa. Mitral valve admits one finger tip, tricuspid admits one and one-half finger tips.

In commenting upon these cases the essayist referred to the extreme rarity of tricuspid stenosis. Following Leudet, he made two classes, the congenital and the acquired. The two cases reported evidently fell into the latter class because of 1, the absence in infancy and childhood of symptoms of cyanosis; 2, the history in the one case of childbirth, in the other of rheumatism with subsequent development of cardiac symptoms; 3, the complete closure of the inter-ventricular and inter-auricular septa. The cases resembled the majority of cases of tricuspid stenosis in being found in women and in being associated with diseases of the valves of the left heart. In Leudet's series of 114 cases, with autopsy, only 11 showed tricuspid disease alone. The symtomatology and diagnosis of the affection were also discussed. The study of Case 2, where there was the enormous hypertrophy of the muscular tissue of the right auricle, showed that even the auricle could in a measure compensate for the obstruction at the auriculo-ventricular valve. This helps to explain why the prognosis is not so

uniformly bad as one would think, and how it is possible for patients to live even to old age, one of Leudet's cases reaching the age of 64.

DISCUSSION.

Dr. JOSEPH M. PATTON—The interesting case reported by Dr. Herrick is certainly of sufficient moment not to be passed by in silence. The rarity of the lesion itself makes it of great interest. The difficulty of diagnosis adds to the interest as does the uniformity with which tricuspid stenosis is associated with mitral stenosis, and this is admitted by nearly every author. A great many authors say, among them Hayden, that tricuspid stenosis rarely or never occurs except in association with mitral stenosis. Today this is not regarded as a fact, because in the last few years a number of cases have been observed where the postmortem proved that tricuspid stenosis does occur alone. A good many of the text-book authors tell us that the murmur of tricuspid stenosis will be a presystolic murmur. I think that is based in part on theory, simply because of the presystolic mitral stenotic sound. The fact is that the murmur of tricuspid stenosis is at times not presystolic, it may be, but it is at times a diastolic murmur. It is very difficult to place the time exactly of a tricuspid stenotic sound. I have only heard one such murmur where a postmortem of the patient was obtained and that murmur was diastolic, or, at least, that portion of it which might be called presystolic was so covered by the associated sounds that it was impossible to demonstrate it clinically as a presystolic murmur. Hayden points out that, on account of the association of tricuspid stenosis with mitral stenosis, a strong diagnostic point may be made of two presystolic murmurs that are heard, one being heard in the mitral area, and the other in the region of the xiphoid, and between these two an open area in which no sound can be heard. That appears to be also largely theoretical, because the area of transmission is usually not so definitely limited as to give us such an open area. It seems to me, that from the history of the first case recited the clinical diagnosis might have been modified, from the fact of there being so much dullness transmitted far to the left, and so high, in connection with an apex beat within the fifth space. Such an area of dullness would tend to exclude aortic disease as a fac-

tor in the production of the cardiac condition. The specimen is a particularly beautiful one in that it shows well marked and uniform stenosis of tricuspid and mitral openings, and also in the unusual degree of hypertrophy of auricular wall and of the musculi pectinati.

Dr. R. H. Babcock—Dr. Herrick has covered the field so fully and admirably in his discussion of this subject, that it seems difficult to say anything which would not be a mere repetition of what has already been said; yet it seems to me, that something more might be added with reference to the prognosis in these cases. It is a matter of very great interest and astonishment that a case of tricuspid stenosis could live to the age of 64 years, and it would be instructive if we could know some of the attendant circumstances pertaining to that patient's life, as well as of some of the associated conditions within the heart. I would ask Dr. Herrick to tell us in that particular instance what other lesions, if any, were associated with the tricuspid stenosis.

Dr. Herrick—I could not tell without referring to Leudet's thesis.

Dr. Babcock—I am interested in this because Bacelli gave an elaborate paper in 1894 on "The Prognosis of Cardiac Lesions," which were of a similar nature. He made the statement that where stenosis of two separate orifices existed, or where insufficiency of two separate sets of valves existed, as, for instance, insufficiency of the aortic valves and insufficiency of the mitral valves, the prognosis, other things being equal, was better than where there was a combination of stenosis and insufficiency, as, stenosis of the aortic orifice and insufficiency of the mitral valves. It would be interesting to know whether in this case there was such a condition as stenosis of the pulmonary orifice and stenosis of the tricuspid orifice. Furthermore, the conditions of the patient's life must intimately affect the prognosis. Under normal conditions the right ventricle is relatively as adequate to its work as the left, yet in any disease which affects the right side of the heart it is much more likely to break down in its compensation than the left. If tricuspid stenosis exists in a congenital case, or if tricuspid stenosis and pulmonary stenosis should concur, the prognosis would be affected not only by these respective con-

ditions but by the circumstances of the patient's life as to daily exercise, physical exertion, etc. If the patient led a particularly quiet life, one not calculated to send the venous blood too rapidly to the heart, the heart might adjust itself to the condition of stenosis and the backward stasis in the other viscera, as the abdominal, would not be so great as to materially affect life. Yet even under the most favorable circumstances it would seem as if the condition were one likely to render long life impossible through the general nutrition, brought about by the condition of the chylopoietic viscera.

The diagnosis is so difficult that, it seems to me, anyone would be exonerated from all reproach who was unable to make a diagnosis. When, however, such is made the practical interest consists in the prognosis and treatment. Let us take, for instance, the case which the doctor has reported and exhibited the specimen from tonight. The patient was a bookbinder, an occupation which if not laborious and not very difficult, yet required the very kind of exercise (arm movement) which would favor a too rapid flow of venous blood to the right auricle and produce disastrous results in the way I have pointed out.

Dr. John A. Robison—Personally, I desire to thank Dr. Herrick for calling our attention to the fact that cases of disease of the right side of the heart are perhaps more frequent than we have been led formerly to believe. I think statistics will show that there have been placed on record about one hundred and thirty cases of tricuspid insufficiency. Dr. Herrick's records, I believe, include cases in which there have been found about one hundred and nineteen or one hundred and twenty cases of tricuspid stenosis, would it not?

Dr. Herrick—Yes. There are about one hundred and thirty cases of this class now on record.

Dr. Robison—The recital of one of Dr. Herrick's cases brings to my mind a case which I had a few years ago in which the result was appalling, and in which I was somewhat at a loss to account for the rapid onset of the symptoms. An Englishwoman, 30 years of age, became pregnant. At about the sixth month of her pregnancy she developed alarming symptoms of valvular disease of the heart. There was a loud systolic murmur heard at the apex. The heart was considerably enlarged on both sides; then dropsy came on suddenly,

disappeared, and she then had all the signs of rapid failure of the heart. Fortunately a miscarriage took place and she lived through it. As time went on a second pregnancy occurred. At about nearly the same period of pregnancy the same symptoms again manifested themselves, and the result this time was not the same as on the previous occasion. The symptoms became rapidly worse and the woman died. If we had been positive in regard to our diagnosis that it was not simply a case of mitral regurgitation, but perhaps one of tricuspid regurgitation as well, it is possible we might have advised that woman to avoid, if possible, the possibility of a second pregnancy, and her life might have been prolonged a considerable number of years. If we made diagnosis of disease of the right side of the heart more frequently than we do, we could prolong the lives of the unhappy victims.

Dr. A. M. Corwin—In regard to the diagnosis of these cases, at first sight it seems strange that we have not more certain data; yet, as Dr. Herrick has said, cases of tricuspid stenosis are usually complicated with other lesions. We have several murmurs, not infrequently an aortic regurgitant murmur, diastolic in time, and this is often heard most distinctly in the area in which we would expect to hear the presystolic murmur of tricuspid stenosis. This may be one of the reasons why an accurate diagnosis has seldom been made in these cases of tricuspid stenosis. We know from experience that where the heart beats over 90, and two murmurs occur, both diastolic, one in the first part of diastole, as is the case with the murmur of aortic regurgitation, and the other in the latter part of diastole—presystolic, it is not always an easy matter to make out their specific character.

With regard to the area of intensity of this murmur of tricuspid stenosis, over the lower part of the sternum, it suggests the question why we hear so frequently the murmur of aortic regurgitation loudest in this same area. Some authors, like Loomis, say that it is due to transmission down the sternum. The sternum undoubtedly transmits to its lower end loud sounds produced at its upper extremity. I think, however, those who have had much experience in examining the heart, know that while in many of these cases the diastolic murmur of aortic regurgitation is heard loudest at the lower part of the

sternum, it may be in such instances heard with very little intensity at the upper or middle part of the sternum. In not a few instances, I have noticed that it is not only heard at the root of the appendix sterni, but along the costal arch for an inch and a half to the left. This I have explained with most satisfaction by the theory of its propagation along the diaphragm. As the murmur is produced in diastole the left ventricle is in close contact with the diaphragm at that time, and the murmur is therefore transmitted down to and along this to its attachment at the end of the sternum. The left heart being also enlarged in such cases, we can readily see why the transmission should take place in this manner. I have dwelt upon this point tonight because the murmur of tricuspid stenosis in question occurs in diastole and has its seat in the same region over the lower end of the sternum.

Dr. JAMES B. HERRICK—I will merely say a word or two in closing with regard to the prognosis. Leudet, whose name I have used frequently tonight, makes the statement that it is only by the complexus of symptoms and by the careful study of the entire condition of the patient that one can make the prognosis in these cases. And it seems to me also, that a study of this specimen, where we observe great hypertrophy of the auricle, will show how it is possible for some of these patients to live as long as they do. The statement is made by some writer with regard to this lesion, that auricular compensation is practically *nil*. But if we look at this postmortem specimen with the greatly hypertrophied auricular structure we can realize how there can be good auricular compensation.

With regard to the length of life in cardiac disease, particularly with the two lesions of insufficiency, or the two of stenosis, I recall that a few years ago I was called to see a patient, the father of a physician, and his history leading me to suspect cardiac disease, I started to place my ear to his chest, when he said, "Doctor, I have heart disease. Skoda told me so in Vienna thirty-five years ago." At the time I made the examination he was about 67 years old, and had been told thirty-five years previously by Skoda that his heart was diseased. The lesion, as I remember, was mitral regurgitation with aortic regurgitation, bearing out the statement of Bacelli which was referred to by Dr. Babcock.

PRESENTATION OF SPECIMEN.

*Anencephalus et Acrania*, by Dr. JOSEPH B. DE LEE—This specimen is a fresh one, and as I thought it would be of interest to the members of the Society I brought it with me. It represents an anomaly which is not so uncommon. It comes from a woman, 30 years of age, who, twelve years ago, after three days' labor, bore a small child. She has a contracted pelvis of the justo-minor type, and is to a certain extent rachitic. Labor commenced Saturday night at 8 o'clock and by Sunday night at the same time no progress had been made. At 11 o'clock Sunday night the pains were strong and expulsive, but still no progress in labor. In making an examination I could determine the back, and heart tones to the left side, and introducing my hand into the vagina I came upon something which I thought to be the vulva of a female child. I found two lips between which was a depression and on each side of which were two hard lumps which I judged to be the tuberosities of the ischii. Further examination revealed an ear alongside of this, and my previous diagnosis had to be retracted. Continuing the examination my finger ran around the head of this monster, the head of which I succeeded in delivering. The shoulders, however, refused to come in spite of traction which was kept up for twenty minutes, aided by Kristeller expression. Examination also showed the cervix tightly contracted around the neck of the fetus. The larger part of the resistance came from the narrow pelvis. I performed the operation of section of the clavicles, known as cleidotomy, and introduced by Phenomenoff last year. Under the guidance of four fingers, with a strong pair of scissors the clavicles were divided, the chest fell together, and came through without any difficulty.

The nature of the anomaly is apparent. It is a monster in which both the cranial vault and the brain are missing. This little pad which you see consists of hemorrhages, some brain tissue and vessels. The technical term for this monster is anencephalus and acrania.

As to the cause, there are three theories. One is that the medullary canal does not close properly and therefore the cerebral vesicles are not well developed. Another is that acute hydrocephalus in the first two months of pregnancy causes

dilatation of the cerebral vesicles and subsequent atrophy. A third theory is that the head fold of the amnion becomes united to the thin membranous covering of the brain, the primordial cranial vault at some period in the early weeks of pregnancy, and the inflammatory adhesions produce this deformity by inhibiting the growth of the brain.

PRESENTATION OF CASE.

*Tricuspid Regurgitation*, by Dr. JOHN A. ROBISON—The case I wish to show you illustrates the difficulties which we sometimes encounter in making a diagnosis of valvular disease of the heart. I thought the case would come in nicely with the discussion on Dr. Herrick's paper.

The patient has been examined by a great many doctors from time to time, but I will not say as many different diagnoses have been made, but quite a number of them have been made. The stumbling block seems to be whether this patient has disease of the right side of the heart or not; in other words, whether he presents a lesion connected with the tricuspid valve, and there have been more physicians who have said that there is no disease of the tricuspid valve than there have been those who have taken the opposite view. We find present in this case undoubted evidence of disease of both the aortic and mitral valves. In the first place, you will notice the character of the pulsations in the neck—the carotid pulsation. Secondly, if you feel the pulse you will get the Corrigan water-hammer pulse, which is greatly accentuated when you put the patient's hands up in this manner. Furthermore, a sphygmographic tracing gives evidence of aortic regurgitation. Listening at the base of the heart over the region of the aortic valves we hear a very soft, almost indefinable murmur with the first heart sound, which is carried slightly upward. We also hear a murmur during the first part of diastole carried slightly downward. Passing to the apex of the heart we heart a murmur at the apex, if my ear does not deceive me. This murmur does not increase in intensity as we go toward the axilla or to the left of the chest, nor do we hear it with the same intensity to the left of the spine as we do in front. Again, you hear a systolic murmur over the whole precordia, but as we travel from the apex of the heart toward the right, we reach a point here near the ensiform cartilage where the intensity of the

murmur is greatest. I think if you had time to examine this man I could prove that to you very easily by using the stethoscope I have in my pocket. I have taken a piece of thin glass and glued it in the stethoscope, by means of which I eliminate the muscular sounds of the heart, and I hear simply the murmur. Placing this stethoscope over the apex we hear the murmur during the systole with distinctness, it not being carried upward toward the axilla or around the chest wall. In carrying it to the right toward the ensiform cartilage it becomes more intense until we reach a point below the left border of the sternum, where we hear a loud murmur with each systolic contraction of the heart.

Another point I wish to call attention to is the fact that we have what I would call the venous pulsation in the neck, the pulsation being presystolic; and not only that, by placing the fingers at the junction of the jugular with the subclavian veins we get a pronounced thrill. My diagnosis in this case would be, judging simply from the primary signs of valvular disease, that this man has undoubtedly a tricuspid regurgitant murmur.

The patient, as I have previously said, has been examined by quite a number of physicians; some of them I see here tonight. They dispute that diagnosis. Of course, a case like this presents many difficulties. In the first place, we have an aortic regurgitation which has caused great increase in the size of the heart, so that the apex beat is below the sixth rib and to the left of the nipple to the extent of two fingers in breadth, and there is no doubt but what he has mitral regurgitation; but if this murmur were simply due to mitral regurgitation, why would not the sign of the propagation of the murmur which generally corroborates the diagnosis of mitral regurgitation be present? Furthermore, it is perfectly consistent with our present knowledge of pathology, as illustrated here tonight, that we can have coexisting disease of the tricuspid as well as of the mitral valves, and there is no reason why we may not have tricuspid insufficiency as well, and account for the fact that we hear this murmur in the region where tricuspid insufficiency murmurs are heard.

## Regular Monthly Meeting, November 9, 1896.

The President, Dr. James B. Herrick in the Chair.

Dr. Arthur Dean Bevan read a paper on

### CAUSES OF OBSTRUCTION OF THE COMMON BILE DUCT.

The following is a synopsis: The subject of gall bladder and gall duct surgery is of recent development. In 1867 Bobbs of Indiana first performed cholecystotomy; in 1882 Langenbuch made the first cholecystectomy; in the same year Gaston suggested cholecystenterostomy and demonstrated its feasibility by experimental operations on dogs, and in 1889 Terrier performed the first anastomosis between the gall bladder and the small intestine. In 1890 Courvoisier added the last of our present list of operations on the bile tracts, choledochotomy. In the last six years the pathology and surgery of the gall tracts have been carefully studied and worked up, and we are now in a position to draw conclusions approximating the truth.

In the development of this work many men have taken part. Among those who have done much for this new field of surgery should be mentioned Lawson Tait, Courvoisier, Riedel, Czerny, Murphy, Fenger, Merrmann, Terrier, Heddaeus, Kehr, Sendler, McGraw and Mayo Robson. The work of these men has gained for the surgery of the bile tract a recognition among standard surgical procedures. As in any line of surgical work, this work rests upon a careful study of the anatomy, the physiology and pathology of the structures involved, and of a careful analysis of the clinical histories of cases. It is not my intention to weary you with a review of the anatomy and physiology of the bile tracts, but I would desire to emphasize the fact that in no field of surgery is this elementary knowledge of more value to the diagnostician and the operator than here; a knowledge of the pathology of the conditions which demand surgical interference is no less necessary; this knowledge has grown with the development of the surgery of the bile tracts; a thorough knowledge of the anatomy, physiology and pathol-

ogy is requisite, therefore, to the correct interpretation of the clinical evidences submitted by an individual case; the pathologic conditions which may interfere with the normal functions of the bile tract are many, and it is to this point, and especially to the causes of obstruction of the common duct, that I desire to call your attention in this paper, and it is in this line that I would ask that your discussion be directed.

To no one does the practical surgeon turn more frequently for instruction than to the pathologist; the findings of the postmortem room are the proofs of the correctness or error of his diagnosis and practical work. It is usually an easy matter to make the sweeping diagnosis of obstruction of the common duct. It is, however, often difficult or impossible antemortem to diagnose correctly its exact cause. For instance, in one list of reported operations for cases diagnosed as obstruction of the common duct, more than one-half were shown by laparotomy to be due to other conditions. My own limited work has curiously emphasized this point, and has led me to search rather carefully the literature with the hope that a careful study of the pathologic conditions found postmortem and by laparotomy, together with the clinical histories of the cases, might lead to a better understanding of the subject, to more accurate diagnoses and to fewer unnecessary operations.

As a basis upon which to discuss the broad question of the causes of obstruction of the common duct, let me report briefly some cases of common duct obstruction, each one illustrating a different type, which have come under my own observation. These cases show the difficulty of making an accurate diagnosis of the cause of the obstruction.

*Case 1.*—An Italian of 65, referred to me by Dr. Coolidge. Intense jaundice of six months' standing, frequent attacks of colic, intermittent chills and fever, pain over epigastric region; on pressure some sense of resistance, but no distinct tumor. Diagnosis: Probable obstruction of common duct by stone. Operation at P resbyterian Hospital, assisted by Dr. Coolidge Found carcinoma of head of pancreas, atrophied gall bladder, no stone. Abdomen closed, patient recovered from operation; died some months later from carcinoma.

*Case 2.*—A woman of 35. Intense jaundice of four months' duration; previous history of frequent attacks of colic, no

history of having passed stone. Intermittent rigors and fever. Enlarged and easily palpated gall bladder. Operation at St. Elizabeth's Hospital; abdominal incision, exposed gall bladder, distended, aspirated it; contents clear, glycerin-like fluid, about half a pint; as the last of this fluid was drawn out a sudden rush of pure bile came out of the needle with some small fragments looking like ground coffee; bile tracts examined, no stone found. Several very large lymphatic glands in front of common duct larger than the end of my thumb; these were tightly bound down between the folds of the gastro-hepatic omentum and produced direct pressure of common duct. Gall bladder was stitched to abdominal wound and drained; bile flowed very freely from fistula, jaundice disappeared, temperature became normal and patient improved greatly; later a cholecystenterostomy with Murphy's button was made by my colleague successfully. The pathology of this case is uncertain, but I introduce it here to show the possibility of obstruction of the common duct by pressure of enlarged lymphatic nodes in the gastro-hepatic omentum.

*Case 3.*—A case at St. Luke's Hospital in which I was associated with Dr. L. L. McArthur. A woman of 35; repeated attacks of jaundice, no clear history of colic, last attack of jaundice has persisted for three months, slight temperature, general condition fair; physical examination negative. Operation by Dr. McArthur revealed no stone, normal gall bladder; a firm smooth mass in head of pancreas, which we believed to be carcinoma, although it did not feel like one. Cholecystenterostomy with Murphy button, recovery and improvement, disappearance of jaundice, subsequent history makes diagnosis of carcinoma improbable. Dr. McArthur and I now both believe the case to be one of obstruction of the common duct by pancreatitis.

*Case 4*—A woman of 23, referred to me by Dr. Frankenthal; history of repeated attacks of colic and jaundice; intermittent temperature, pain over epigastrium. Diagnosis: Obstruction of common duct probably due to stone. Physical examination negative. Operation at St. Luke's Hospital. Gall bladder normal; in front of common duct an atheromatous cyst three and a half inches long and one inch in diameter, between the layers of the gastro-hepatic omentum and winding over the

right edge of same into the foramen of Winslow. With great difficulty the cyst wall was dissected out entire; wound packed with gauze and tube. Recovery normal; left hospital at end of four weeks; jaundice and pain disappeared. This is a most interesting and rare case; I find the only one on record of an atheromatous cyst producing obstruction of the common duct, although Wiedel reports a case of an atheromatous cyst in the gall bladder. There is some question as to the pathology of the condition, for the section of the cyst wall shows no epithelium, but the gross appearance of the cyst and its contents were typical of atheromatous cyst, and a careful examination excludes echinococcus and does not furnish positive proof of tuberculosis.

*Case 5* is a postmortem made at Leipsig by Birch Hirschfeld, which I had the opportunity to examine; the patient had died of cholemia. The examination revealed obstruction of common duct due to syphilitic gumma.

*Case 6.*—A man of 60; repeated attacks of jaundice and colic, remittent slight elevations of temperature, pain over epigastrium; referred to me by Dr. Herrick, who made the diagnosis of obstructive jaundice, probably stone. Operation at Presbyterian Hospital. Gall bladder very small; stone in common duct, freely movable; common duct incised, stone removed, no other stones found; could not close duct with suture, so drained with rubber tube and gauze; recovery uninterrupted; bile flowed through tube for nine days, then ceased and evidently now flows into duodenum. Jaundice has disappeared. Pain has ceased and patient has apparently made a complete recovery.

Here we have in these six cases six different and distinct pathologic conditions of obstruction of the common duct. In reviewing the literature I find many others. Grouped together I find that obstruction of the common duct may be due to:

1, catarrhal jaundice; 2, gallstones in common duct; 3, carcinoma of the duct; 4, stricture; 5, sclerotic pancreatitis; 6, gumma; 7, hydatids in duct; 8, ascaris, seven cases reported; 9, pressure from stone in cystic duct; 10, enlarged lymphatic glands by pressure; 11, pressure from extramural tumors: benignant; atheroma, papilloma, papillomyxoma; and malignant; sarcoma and carcinoma; 12, pressure from inflammatory

exudates; 13, adhesions producing flexures of the duct; 14-tuberculosis, one case reported.

I have grouped together all the causes of obstruction of the common duct reported in the literature to which I have access. Many of these causes are extremely rare, but the very number of possible causes shows how difficult it is to make a positive diagnosis before operating. The common causes of course are catarrhal obstruction, stone and carcinoma. In many cases it is not difficult to distinguish between these conditions and yet it has been impossible to make an absolute diagnosis in the majority even of the cases submitted to operation, as shown by the cases collected by Greig Smith, in which thirty-five laparotomies for suspected stone showed in eighteen cases obstruction due to other causes.

DISCUSSION.

Dr. D. W. Graham—There is one cause of obstruction of the common duct mentioned by Dr. Bevan which has lost much of its importance, as we shall see if we compare the literature of today with that of twenty or thirty years ago. I refer to gastro-duodenitis. While no doubt a few of the milder cases of jaundice are still properly attributable to this cause, gastric disturbance accompanied with jaundice even though mild and transient, which were formerly ascribed to gastro-duodenitis, are today properly counted as due to the passing of gall-stones through the common duct into the intestine.

Dr. Hektoen—Attention may be briefly directed to chronic biliary obstruction due to chronic cholangitis following acute cholangitis developing in close connection with typhoid fever. The gall bladder has been shown by Fütterer and Chiari to become a reservoir for typhoid bacilli in typhoid fever. The bacilli may remain in the bile long after subsidence of the fever. The routine bacteriologic examinations during postmortems made the last two years or so of typhoid fever patients have confirmed these statements. Cases of suppurative cholangitis and cholecystitis have also been described after typhoid fever. Not long ago I made a postmortem examination of a woman for Professor Henry M. Lyman. Some years previous to death she had an illness diagnosed by Professor Lyman as typhoid fever; toward the end of the attack there developed jaundice and pain in the region of the gall bladder. Since then she

suffered from chronic jaundice, dying from hemorrhage from a gastric ulcer, after having presented for a time the bone symptoms of osteomalacia, which was verified by the autopsy. In this case there was a dense fibrous peri-cholangitis and -cystitis, the bile ducts being greatly narrowed and practically occluded. The liver contained biliary retention cysts and was quite green in color. General jaundice was present.

Dr. SAMUEL H. FRIEND read a paper on "Investigations upon an Umbilical Origin of Peritonitis."

Dr. LEMKE presented a paper for Dr. Dysart on

THE ACTION OF HUMAN SERUM UPON TYPHOID BACILLI; A CLINICAL STUDY.

Dr. Lewis R. Dysart, late resident physician of the Cook County Hospital, has made a clinical study of the action of human serum upon typhoid bacilli, the more important results of which I have the honor of communicating to the Society, in the absence of Dr. Dysart, who has gone to Mexico.

The majority of the tests were made by making an emulsion of typhoid bacilli in a drop of water upon a glass slide; three or four drops of blood were then obtained upon a glass slide, and by touching the blood with a loop of platinum wire the serum which collects on the outside of the drops was transferred to the emulsion of typhoid bacilli, with which it was thoroughly mixed. Care was taken that the bacilli were thoroughly emulsified, so that no clumps were present before the addition of the serum.

A cover glass was then placed over the emulsion and this examined with an oil immersion; hanging drops were also made in a like manner. Other tests were made according to the methods of Professor Pfeiffer, which consists in adding blood serum to an emulsion of typhoid bacilli in a test tube and noticing the formation of clumps, as seen by the microscope, and the precipitation of the bacteria to the bottom of the tube, as shown by the clearing up of the fluid and the appearance of a flocculent precipitate.

In eighty-nine cases of typhoid fever, where the clinical diagnosis seemed positive, and in some few of which the postmortem findings were those of typhoid, the bacilli rapidly gathered into the characteristic clumps; some of these were large and others of medium size, the bacilli becoming immotile.

The clumping in many of the cases was marked as soon as the specimen could be gotten under the microscope, and in all at the end of from three to five minutes.

In fifty nine cases in which the clinical diagnosis was not typhoid fever, and in many instances verified by the postmortem, the reaction was not obtained. This list includes a great variety of different diseases, such as cirrhosis of the liver, chronic valvular heart disease, tertiary syphilis, pulmonary, intestinal and bone tuberculosis, malarial fever, lobar pneumonia, acute rheumatism, carcinoma of the stomach, tetanus, gonorrheal rheumatism, multiple neuritis, nephritis, hysteria, insanity, etc.

The reaction was obtained in three cases of diseases not typhoid fever; namely, in one case of acute articular rheumatism, in one of malaria (controlled by demonstration of the organisms in the blood) and in one of chronic rheumatism. In the last case only was there a history of typhoid fever previously, namely, thirty years ago. The reaction in these cases was prompt and the clumps were large. In two cases in which the diagnosis of typhoid fever seemed positive, clumping did not occur in five minutes, but when the Pfeiffer method was used marked clumping occurred within a short time, with considerable precipitation in the bottom of the tube. One of these patients has since died and the postmortem examination showed lobar pneumonia and the characteristic typhoid lesions.

In two cases in which the diagnosis of typhoid is not positive (patients still living) the reaction was not obtained by the simpler method but the Pfeiffer method gave a positive result. In one of these cases the diagnosis lies between an acute exacerbation of a chronic endocarditis and typhoid fever, in the second between typhoid and malaria, but the plasmodia were not found. In two other cases the reaction was also obtained but the diagnosis of typhoid did not seem absolutely positive but no other definite diagnosis could be made. In two cases in which the diagnosis lay between typhoid fever and miliary tuberculosis in one case and acute exacerbation of a chronic endocarditis in the other, the reactions were all negative. No opportunity has presented itself to verify the indications thus obtained by autopsies.

From a study of the cases, positive as well as negative, and also from a careful consideration of the doubtful cases referred to, Dr. Dysart reaches the following conclusions:

1. This reaction can be obtained from the great majority of, if not from all, patients suffering from typhoid fever.

2. That the reaction can not be obtained from the great majority of other diseases.

3. That in three cases, clearly not typhoid fever, a marked reaction was obtained repeatedly in the hanging drop.

4. That in some cases of typhoid fever, in which the reaction is not obtained within five minutes in the hanging drop preparation, the Pfeiffer test tube method may give positive results.

5. The absence of the reaction in typhoid fever has not yet been demonstrated to occur in cases verified by postmortem examination.

6. The presence of lobar pneumonia, and probably other complications and sequelæ of typhoid fever, does not prevent the occurrence of the reaction, as shown by two cases verified by postmortem examination.

7. In doubtful cases the serum should be diluted in accordance with the methods of Durham, Greenbaum and others, and in this manner the results might be found to be more definitely conclusive.

DISCUSSION.

Dr. PREBLE—I have followed Dr. Dysart's studies in the wards with a great deal of interest, because the subject is of far greater importance than the subjects which we ordinarily meet. Every one knows the extreme difficulty at times of making a positive diagnosis of typhoid fever. It is to be regretted that Dr. Dysart had so few opportunities to apply this test to cases in which the differential of typhoid fever from diagnosis of other diseases such as acute miliary tuberculosis is difficult. It is in these cases that we wish such aids as this. The method appeals to one as possibly being a rational one; I suppose the rationale of the test being, that the serum of typhoid patients contains antitoxins, which in some way impair the vitality of the typhoid bacilli, thus causing the motion to cease. It would be interesting to know in what way the serum of typhoid patients affects the bacterium coli commune, which resembles the typhoid bacillus in so many respects. Perhaps

Dr. Lemke will be able to enlighten us upon this point. The test has not been used to any great extent as yet. Dieulafoy reported one hundred cases of typhoid fever, each time with the same result, the serum causing agglutination of the typhoid bacilli. It is as important to know the negative side of a test as to know the positive side. We can know this only by further observation of cases of endocarditis, miliary tuberculosis, and cryptogenetic sepsis and the like, in which there is later opportunities of confirming the diagnosis by postmortem.

Dr. Babcock—I would like to ask at how early stages in typhoid fever the serum works on this culture.

Dr. Weaver—There was a question raised in regard to the action of the serum in the case of the bacillus coli communis. It has been shown that the bacillus coli communis thrives in typhoid serum and that there is no clumping or death produced. This work which Dr. Dysart has done has added considerably to our knowledge of a subject which we know comparatively little about so far. The work of Dr. Dysart seems to me to be one of the most valuable things in a scientific line that has been carried out by any of the house men in the County Hospital, so far as I know anything of their work, for a number of years. It seems to me he deserves particular credit for this work which he has accomplished.

Dr. Hektoen—It will be remembered that when Pfeiffer and Kolle published their first article concerning the action of serum of immune animals on typhoid bacilli they asked particularly that the profession repeat these experiments and verify them, and it seems to me that in Dr. Dysart's work this request has been carried out well. The practical importance of this reaction, the apparent rationale of which we all understand, is being appreciated everywhere, and this is shown by the fact that already the boards of health have arranged for carrying out this reaction quite generally.

Dr. Herrick—Dr. Hektoen has called attention to the fact that boards of health have already offered to make examinations in the same way that examinations are made for the profession in suspected diphtheria. That has been rendered possible by the fact that this same reaction has been found to occur when a drop of dried blood, even though it be several days old, is moistened with water and added to the emulsion

of typhoid bacilli. The reaction with the dried blood has been proven by Widal, and independently, I believe, by Wyatt Johnston of Montreal, who, about a week ago, reported that fact and made the announcement that the Montreal Board of Health would make examinations for the profession.

Still, we must not be premature in our conclusions. If Dr. Dysart's results are true, it shows that perhaps 3 per cent. of failures will be met with. He found in three cases, one of acute articular rheumatism, one of chronic rheumatism and one of malaria, a distinct reaction, and found it repeatedly, so that the test may be, after all, rather of negative than of posi-

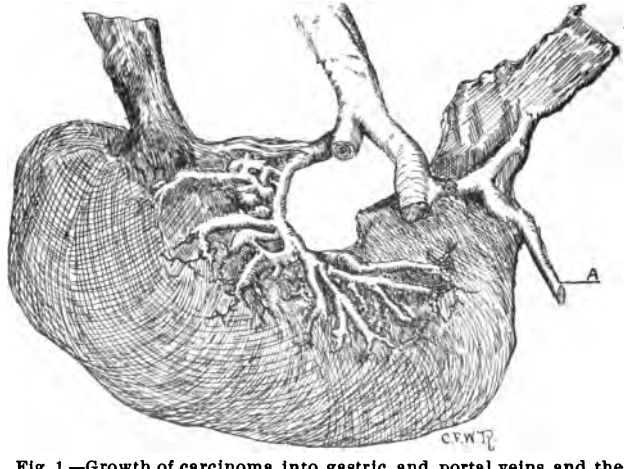


Fig. 1.—Growth of carcinoma into gastric and portal veins and the radicles of the latter, secondary to carcinoma of the pylorus. The posterior surface of the stomach, which is turned so that the pylorus is to the left, is exposed. A, cut end of gastro-duodenal vein, from which the microscopic section drawn in figure 2 was taken.

tive value, that is to say, the failure to get the reaction may be all that we can rely upon and it may tend to exclude typhoid fever.

Dr. Hektoen—That is a very proper objection taken by Dr. Herrick just now; it may be said, however, that the test as carried out by Dr. Dysart is not altogether correct, because the serum must be diluted to a certain percentage, and in his last conclusion Dr. Dysart referred to that fact and says, that

in continuing such tests, if the serum be properly diluted according to the recommendation of certain authors, the reaction may become more conclusive; and herein lies opportunity for still more work in the future.

Dr. LEMKE—With reference to Dr. Babcock's question, I can only say that Dr. Dysart was able to get positive reaction in all cases entered at the hospital; in many cases it was at the end of the first week.

EXHIBITION OF SPECIMENS.

Dr. L. HEKTOEN showed a *carcinoma* of the *pylorus* with extensive growth of tumor into the veins about the stomach removed from a greatly emaciated colored man, 56 years of age, upon whom, as a last resort, an operation for gastro-enterostomy had been made by Prof. John B. Hamilton, shortly before death. The tumor is situated around the pylorus, which is practically occluded, and it presents a large ulcerated surface with raised margins. The particular feature to which attention is called is the extensive growth of tumor tissue into the wall of the stomach and behind it (Fig. 1). The gastric veins are all distended and nodular, as though they were the seat of an extensive thrombosis. This tumor-thrombosis, so-called, extends into the portal vein and fills the entire main trunk, and from this vein the thrombosis extends backward against the blood current into the veins that go to make up the portal vein, the splenic vein and the superior mesenteric vein for some distance, but just how far can not be said, because in the removal of the growth these veins were cut off while still containing tumor masses in the gastro-duodenal vein. There is also extensive secondary carcinoma of the lymphatic glands in the gastrohepatic omentum and the pressure of these upon the bile ducts produced biliary obstruction and some jaundice, and this is still shown in the specimen by the greatly extended gall bladder.

In order to explain the intravenous extension of the tumor it is assumed that in some way the carcinoma grew into the venous or capillary network of the wall of the stomach and from there rapidly extended in many directions, finding but little obstruction to its growth in the blood channels. It is quite remarkable that the growth should continue against the current instead of into the liver, as would be expected. There were no metastases in the liver. Contrary to expectations there

was no ascites. The absence of ascites is hard to explain. The extreme emaciation and the consequent small amount of blood in the body may have allowed collateral circulation to be established without any evident changes in the caliber of the collateral channels.

The microscopic examination (Fig. 2) shows the lumen of the gastro-duodenal vein, at a point about three inches from its end, to be filled with a typical carcinomatous growth, the islands of epithelial cells being enclosed in distinct and often broad bands of connective tissue which seem to be more an integral part of the tumor than a new production from the vein wall. Here and there are spaces filled with blood, and it may

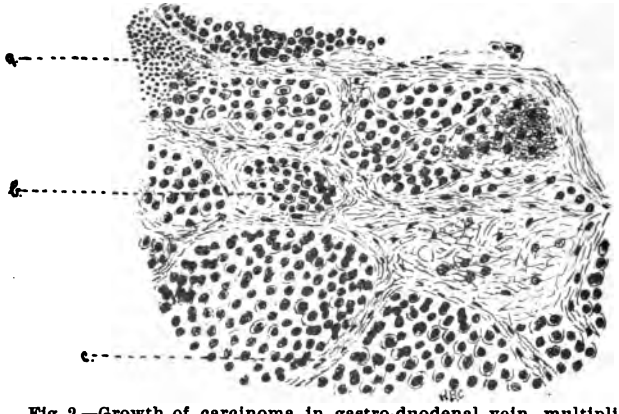


Fig. 2.—Growth of carcinoma in gastro-duodenal vein, multiplied 175 times; a, blood; b, cell nest; c, connective tissue trabeculæ.

be that the portal circulation was maintained in sufficient degree to obviate passive congestion through such spaces in the "carcinomatous thrombus."

Dr. King presented some specimens of *tuberculosis testis* and related the history of the case from which they were obtained.

Dr. Herrick presented specimens of heart, showing *mitral and tricuspid stenosis.*

He said: I will take a few minutes to show a heart that shows mitral and tricuspid stenosis, the third case that has come to the autopsy at the County Hospital recently. It con-

cerns a middle-aged woman with a previous history of rheumatism, subjective symptoms of heart disease and physical findings that indicated pericarditis. Tricuspid stenosis was not recognized during life. The heart shows a mildly enlarged left ventricle, the walls thickened, the mitral valve with the cusps thickened and drawn together, the orifice admitting perhaps one and one-half finger tips; the left auricle is also enlarged, as it is in any case of mitral stenosis. In the left heart I should also say the aortic valves are slightly thickened and it was thought at the autopsy, which was made by Dr. Hektoen, there was possibly a slight incompetency. The right heart shows a dilated and hypertrophied right ventricle, the tricuspid orifice admitting three finger tips, the free margins of the valve being thickened and deformed. The right auricle is hypertrophied and dilated. At the last meeting I reported two cases of tricuspid stenosis and it is certainly very strange that a third case should have come to autopsy within so short a time. This case corresponds to the common findings in cases of tricuspid stenosis. The patient was a woman; the tricuspid obstruction is combined with lesions of the left heart and most commonly with an obstruction at the mitral valve. This is further a case of acquired tricuspid stenosis, not congenital, that being proved by the absence of symptoms of cyanosis in earlier life, proven also by the absenee of defects in the ventricular and auricular septum and of a history of rheumatism.

## Regular Monthly Meeting, December 14, 1896.

The Vice-President, Dr. Arthur R. Edwards, in the Chair.

Dr. Henry F. Lewis read a paper on

# INIENCEPHALUS.

St. Hilaire defines a monstrosity as a serious deviation from the specific type, complex, apparent on external view and congenital. His classification of anomalies and monstrosities has generally been followed by teratologists since his time. A large family of monsters is characterized by a defective closure of the cranial vault or the vertebral laminæ. There are many varieties according as the defect is in the cranial bones, the spine, both cranium and spine, or parts of each or both. In a large number the brain is entirely wanting or rudimentary. Such are the anencephali or derencephali, the commonest of all, the so-called frog or owl fetuses. In another class the brain is present, although the mal-development of the bones has caused all or part of it to lie outside the cranial cavity. Sometimes the posterior defect is confined entirely or mostly to the vertebral laminæ and we have spina bifida, through the defect in which meningocele usually protrudes. The class in which the brain is wholly or in part outside the cranium is the exencephalian. This is subdivided into those with and those without spinal fissure.

Without spina bifida:

1. Notencephalus; brain largely outside the skull through occipital defect with posterior encephalocele

2. Proencephalus; anterior encephalocele.

3. Hyperencephalus; podencephalus; cranial defect in vault.

With spina bifida:

1. Exencephalus proper; cranial bones rudimentary and brain lies mostly or entirely outside on the back. The spinal defect may involve a few or all vertebræ.

2. Iniencephalus; considerable or all of the brain is covered by the cranial bones, but the tilting backward of the head makes the margins of the occipital defect come closely in contact with the margins of the spina bifida so that some of the brain lies upon the spinal cord and in the spinal gutter, although covered wholly or in part by the bones of the cranial vault, which act as vertebral laminæ. There may be an encephalocele or not. Ballantyne states three cardinal characteristics of iniencephalus: occipital defect, spina bifida and fetal retroflexion. The dividing line between iniencephalus and exencephalus proper is not absolute and some few cases might be classified differently by different authorities. Taruffi groups iniencephalus, notencephalus and exencephalus proper into one species which he calls "mero-acrania posterio-spinale."

Iniencephalus is a rare form of monster. Isidore Geoffrey St. Hilaire, writing in 1836, says that only three cases had been thus far reported. Taruffi, writing in 1889, says that only about twenty cases had been reported of mero-acrania posterio-spinale. I have collected every case reported in accessible literature, including an exhaustion of the Catalogue of the Surgeon-General's Office, U. S. A., and the Index Medicus, omitting one case undoubted and one doubt-

ful which I can not find in original or abstract. To these I add one case delivered by myself and two from the museum of Rush Medical College, dissected by me with the assistance of Dr. L. J. Mitchell and with the permission of Prof. Ludvig Hektoen.

The cases recorded below divide themselves into three general classes. The first includes those without protrusion of the brain beyond the box formed by the cranial bones and the open vertebræ. This class may be called *iniencephalus clausus*. The second includes those having a small encephalocele and, with the first, comprises the typical iniencephalic class. The third includes those cases where the occipital opening is large enough to allow the escape of a large portion of the brain. The last two might be called *iniencephalus apertus*. Of the iniencephali clausi I have collected nine cases, viz.: By Fleck[45], Royal College of Surgeons of England[6], Coffin[8], Yocum[9], Landucci[10], Ballantyne[11 2] (two cases), my own case and one from Rush College Museum.

My case is as follows: Primipara, 25 years old, in sixth month of gestation, abdomen enlarged correspondingly, twins, male. One was normal and appeared to be five and one-half months along. This one lived for twenty hours in an incubator. It is 10 inches long, weighs 590 g., has finger nails half out to ends of digits and undescended testes. The second was dead and somewhat macerated, 6½ inches long, weighed 190 g. There was a common placenta and chorion, two amnia and two cords. The smaller twin presented the appearance of great shortening of the back. From back of head to anus is only ¾ inch, while from chin to pubes in front is 4¼ inches. The face looks for-

ward and upward, while the cranium is turned sharply barkward, covering most of the dorsum. The neck is edematous and has no furrow between chin and sternum. The abdomen is very protuberant. Dissection shows the parietals overlying the upper two-thirds of the spinal column. Cutting the fibrinous attachments of the cranial bones to the spine and turning the head forward reveals an extensive spina bifida as far as the second lumbar vertebra. All the cranial bones are normal except the occiput. The basilar portion articulates with the atlas, but the bone broadens out so as to leave a large foramen magnum, which opening is continuous with a large defect in the squamous portion and makes a figure eight with the latter opening. The squamous plates of the occiput are represented only by an acute triangle on either side of the opening articulating anteriorly with the parietal. The margins of the bony defect in the occiput are closely attached to the ends of the widely divergent transverse processes of the cervical, dorsal and first lumbar vertebræ. Thus it will be seen that the spinal canal is covered above by the remnants of the occiput and the parietals which form a sort of roof along the dorsum. At the bottom of the spinal canal lies the cord and over it, contained in the cranium, lies the brain. Thus we have an *exencephalus*, for while the brain does not escape into the outer world, yet it does lie partly outside of the cranium and in the spinal canal. The defect is in the occiput or "inion" and therefore the variety is "iniencephalus."

The cervical spinal column curves downward and forward, making a concavity with the dorsal portion which turns backward under the cranium. The

cerebral hemispheres are apparently of normal size.

The first Rush College case is an unmarked specimen without history. Female, Beclard's center in the femur present, nails to ends of digits and otherwise apparently of full term. The length is only 12¼ inches, but the shortness is explained by the marked foreshortening of the back due to the tilting backward of the head. The face looks forward and upward, leaving very little furrow below the chin. There is an opening in the abdomen near the navel, allowing some of the viscera to be outside the body.

Dissection reveals a complete spina bifida to the tip of the coccyx. The cranium extends as far as the lumbar region, attached ligamentously to the transverse processes as in the former case and forming a roof over the spinal canal. There is no encephalocele. There is much lordosis of the cervical spine and right scoliosis of the whole column, so that the ribs are so irregular as to deform the chest. The opening in the occiput consists of a large foramen magnum 1⅝ x 1⅛ inches. The width of the spinal cleft is at its maximum 1½ inches. There is slight talipes varus of both feet.

Of *iniencephalus apertus* first come those with small encephalocele. Of this class I have collected eight cases, viz.: By Dugés[12 1], Potthoff[54], Cruveihier,[13 14] Drew and Jackson[15], Lawther[16], Vernier[17], Remfrey[18] and the second case found by me in Rush College.

This last is marked 140 and is without history. Female, toe nails less than half and finger nails two-thirds out to tips of digits; apparently about seventh month.

Beside the usual tilting back of the head and shortening of the dorsum there are two soft tumors upon the back. One protrudes from a bony defect in the skull to the right of the median line and hangs over the right shoulder, measures $2\frac{3}{8}$ x $2\frac{1}{4}$ inches and is shown by dissection to be an encephalocele. In the median line, and occupying the lower two-thirds of the dorsal region, is another tumor covered by membrane and allowing the cleft spine to be felt beneath. It measures one and one-fourth by fifteen-sixteenth inch and is shown by dissection to be a meningocele. The opening in the cranium through which the lateral tumor escapes is between the rudimentary plates of the squamous occiput which, in the form of acute triangles, are articulated with the parietals at the lambdoid suture. The bony defect here is continuous with the enlarged foramen magnum below and forming a figure eight with it. The margins of the foramen lie flat upon the spinal column and are ligamentously attached to the bony margins of the spina bifida. Thus the occiput covers the spinal canal, causing the shortening of the back of the fetus. There is complete spina bifida to the tip of the coccyx, widest under the cranium. There is lordosis of the cervical and kyphosis of the lumbar vertebræ. The axis of the spinal column is also turned to the right in the cervical and dorsal regions (right scoliosis).

Of the third class, namely, iniencephalus apertus with large encephalocele, I have collected five cases, namely: By Hull[20], Gros[21], Budin[22], Rogers[23] and Bonnaire[24]. As in most classifications, the distinction between iniencephali and exencephali proper becomes indefinite at the boundaries. A few cases

might, by different authorities, be classed in either category. One such case is reported by Poelman[25], but this seems to be an exencephalus proper with cyclops. Taruffi[3], in the section on mero-acrania posterior-spinale, mentions ten cases collected by him where the cranial defect was in the occiput. This class he considers synonymous with the iniencephalus of St. Hilaire. Only one of these do I think a true iniencephalus and that is one reported by Hull and already referred to by me. Beside these of Taruffi, I find reference to two whose original reports I am unable to find. One is a specimen depicted in Ahlfeld's Atlas[5] and shows a skull with enlarged foramen magnum, therefore may be iniencephalus or notencephalus. Vrolik[32] also depicts a skull with similar defect, but further particulars are wanting. St. Hilaire states that one of the three cases of iniencephalus reported up to his time was by Burkhardt[36] but I can nowhere find original or abstract of the latter's article.

A résumé of the twenty-two cases collected by me shows a few interesting facts. In all cases there was a marked tilting back of the head and extension of the cranium on to the dorsum. The rhachischisis extends to the sacrum or farther in ten cases, to the last dorsal in two, to the middle dorsal region in four, through the cervical region in three and not stated in the rest. Anterior spina bifida in two, diaphragmatic hernia in four, hydramnios in six, club foot in three, hydrocephalus in one, umbilical hernia in one, celosomia in two, deformities or displacements of the alimentary tract in eight, myelocele in one. In one the external oblique took an origin from the clavicle and

in another the gluteus maximus from the occiput. Four were born living, seven dead and the rest not stated; two were male, seven were born of primiparæ, four of multiparæ and the rest not stated. Only twice is it stated that there was twin pregnancy, in seven not stated and in the rest the language would imply single births.

The group of monsters exhibiting cranio-rhachischisis is a numerous one. Anencephalus occurs once in 7,143 births[37] and about two-thirds are female[39]. Of the exencephalians the least rare is notencephalus; the proencephali are rather more rare and the podencephali rarest in the human species but common among animals. The exencephali proper and iniencephali are both very rare, the latter the most.

There are two important sets of views as to the etiology of such monstrosities. The pathologic theory explains the anomaly by disease of the fetus itself acting early in its history and depending for the different forms of anomaly upon the date of beginning.

The embryologic theory now held by the majority of authorities, explains malformations by arrest of development, usually from pressure at an early embryonic period. Dareste[44] considers the cause to be pressure and adhesion of the amnion to the tissues developing beneath it. He experimented with the eggs of birds, chiefly by unequal heating of different parts of the egg during artificial incubation, and was even able to a certain extent, by varying the point of greatest warmth, to produce different forms of monster at will. The arrest of development of the amnion, consequent on his treatment of the egg, modified the evolution of the different parts of the embryo by the compression

it exercised upon them. The cranio-rhachischisic monsters he took to arise from compression and adhesion of the cephalic hood of the amnion which tended to shorten and flatten the cerebral vesicles.

Curious and interesting tales are told by ancient and medieval writers about all sorts of possible and fabulous monsters, but teratology practically begins with St. Hilaire in the first half of the nineteenth century. His classification of monsters and anomalies remains satisfactory to almost all the wants of teratologists today. Later teratologists have devoted themselves to the etiology of the subject, as is evidenced especially in the experimental work of Dareste and his followers. The fields for experiment as well as for observation are relatively so small that the advance has been also small, still much has been and is being done. Teratology is pathologic embryology and the advance of the former must depend largely upon that of the latter. Although experiment will in the future, as in the past, do much to clear up these obscure problems, yet we will continue to be largely dependent upon careful descriptions of carefully made dissections.

BIBLIOGRAPHY.

1. Isidore Geoffroy St. Hiliare: Histoire des Anomalies, etc., Paris, 1836.
2. J. W. Ballantyne: Teratologia, October, 1895, p. 287.
3. Cesare Taruffi: Storia della Teratologia, Bologna, 1889.
4. Fleck: In spinam bifidam ejusque genesin, etc. In. Diss. Breslau, 856.
5. Ahlfed; Die Missbildungen des Menschen. and Atlas, Leipzig, 1880.
6. R. Thompson Lowne: Des. Cat. of the Teratol. Series in Museum R. S. C. of England, London, 1872, p. 68.
7. Camille Dareste: Recherches sur Production artificielle des Monstr. Paris.
8. Coffin: Trans. Obstet. Soc. Lond., 1882, p. 98.
9. C. A. Yocum: Hahn. M., November, 1890, p. 773.
10. Francesco Landucci: Annali di Ostet. e Ginec., Milano, 1893, p. 251.
11. J. W. Ballantyne: Teratologia, April, 1895, p. 87.

12. Duges: Mem. sur les alterations intra-uterines de l'encephale et de ses enveloppes.
13. Jean Cruveilhier: Anat. Path. du Corps Humain, Vol. I, liv. xix, 1886,
14. F. A. von Ammon: Die angebornene chir. Krankh., Berlin, 1842. B. iv.
15. J. B. S. Jackson: Desc. Cat. of Mons. in Cabinet of Boston Soc. for Medical Improvement, 1847, p. 30.
16. George Lawther: Obst. J. Grt. Brit. and Ire., 1880, p. 335.
17. Vernier: Gaz. med. de Picardy, 1885, p. 167.
18. L. Remfrey: Trans. Lond. Obstet. Soc, 1894, p. 227.
19. J. Z. Lawrence: Tabular Analysis of Seventy-five Cases of Encephalocele, Med. Chir. Trans., 1856, p. 307.
20. Hull: Mem. of the Lit. and Phil. Soc. of Manchester, V. pt. ii, 1802, p. 495.
21. Gros: Comptes rend. du Soc. med. de Lyon, 1878, p. 151.
22. P. Budin: Obstet. and Gynec., c. xii, 1886, p. 237.
23. Fred. T. Rogers: Trans. Rhode Is. Med. Soc., 1888, p. 448.
24. E. Bonnaire: Arch. de Tocol. et Gynec, Paris, 1892, p. 275.
25. C. Poelman: Bull. Soc. de Med. de Gand., 1862.
26. Solomon Reisel: De cerebello extra cranium post terrorem gravidæ a fele imposito, Miscellanea Curiosa, etc., Annus ii, Norimbergæ, 1688.
27. G. G. Detharding: Nova Acta Physico-Med. Acad. Leopold. Carol. Nat. Curios., Tom. x, Bonnæ. 1821, p. 705.
28. Marye: Arch. gen. de Med., Paris, Tom. iv, 1827, p. 379.
30. Francesco Scavone: Atti della Accad. Gicenia, Vol. ii, 1827.
31. Luigi Calori: Nove Comment. Acad. Scient., Tom. vii, Bononiæ, 1844.
32. W. Vrolik: Tabulæ ad illustrandam embryogenesin, Amsterdam 1849.
33. V. Castellani: Un Monstro Umano, Bull. delle Soc. Med., Bologna, 1856.
34. Gallez: Bull. de l'Acad. R. de Med. de Belg., 1868.
35. Carl E. Stein: Ein Fall von Hæmicephalie, etc., Thesis, Marburg, 1879.
36. Burkhardt: De Monstro Humano Notabile, Diss. Freiburg, 1825.
37. Puech: Des anomalies de l'homme, etc.
38. Lallemand: These de Paris, 1818.
39. Adolph W. Otto: Monstrorum sexcent. Descriptio Anat., 1841.
40. L. H. Bentkowski: Etude sur une monstre exenceph., These de Montpellier.
41. Foerster: Die Missbildungen des Menschen, p. 4.
42. E. Lancereau: Traite d'Anat. Path., Paris, 1875.
43. Princeton: Progres de Teratol. depuis St. Hiliare, These, Paris, 1886.
44. Camille Dareste: Comptes rend. de Acad. des Sciences, 1882.
45. Camille Dareste: Comptes rend de Soc. de Biol., Paris, 1 894, p. 757.
46. John Cleland: Memoirs and Memoranda in Anat., Vol. 1, p. 127.
47. Ambrose Pare: Deux Livres de Chirurgie, 1578.
48. C. Wallreich: De Monstris, 1655.
49. Joh. Kalinkius: De Monstris, 1647.
50. Georg. Stengelius: De Monstris et Monstrosis, 1647.

51. Jean Palfyn and Mauriceau: Traite de Monstres, 1708.
52. Schlemm: Ref. by Buettner: Diss. sistens Hydroencephaloceles casum singularem, Berlin, 1832.
53. David L. Booth: Kansas City Med. Recorder, 1892.
54. Potthoff: Descriptio casus rarissimi spinam bifidam totalem sistens, In. Diss., Berlin, 1827.

DISCUSSION.

Dr. EDWIN KLEBS—In reference to the very interesting subject discussed by Dr. Lewis I have only a few remarks to make, as I have not specially studied the subject.

1. I would say that I do not like the name of iniencephalus, as the foremost alteration is in the spine, showing the highest degree of spina bifida or rachiochysis. As the whole fetus with well-formed head and extremities shows a high degree of retardation of growth, it may deserve the name of a dwarf-growth. The head is retracted by the shortness of the spine; the upper and lower extremities approach one another. In comparison with the well known cases of microcephalia and micromelia (diminished growth of head and limbs) one would give to this monster the name of microrhachia.

2. As to the development of the spina bifida, I have shown in a case of dwarf fetus, no longer than 16 m. in the fourth month of development, that the alteration begins at the time of the formation of the chorda dorsalis, probably by adhesion of the flat embryo to the egg membranes, hindering the occlusion of the opened spinal canal and the development of the spinal marrow.

3. In this case it seems to be remarkable that notwithstanding the general arrest of development the formation of head and limbs shows normal forms. As the intervertebral ganglia in such cases are developed the normal formation of the extremities is regular. Other cases of rachiochysis and amelia can not depend upon the destruction of the spinal marrow. It seems that in micromelia the development of the limbs is retarded by mechanical obstacles, probably the shortness of the amnion. In this case the amnion was normally developed, and no obstacle formed to prevent the development of the limbs. That the place of the first adhesion of the fetus to the egg membrane can not be detected is explained by the high power of regeneration in the egg and fetus.

4. It may be remarked that the abnormal conditions in this

case of iniencephalus, as in so many other cases of malformation, are caused by the presence of another well-developed fetus.

EXHIBITION OF SPECIMENS.

Dr. E. R. Le Count showed a *cyst of the urachus.* The patient from whom this specimen was obtained was admitted to the Cook County Hospital Feb. 27, 1895. He was a man 52 years of age, white and single. He was admitted for an illness which began four weeks previously with frequent micturition and pain in the region of the kidneys. Examination revealed an enlarged prostate. Symptoms of cystitis with retention of urine, hydronephrosis and uremia prevailed, and death occurred April 9.

Bladder and cyst of the urachus, greatly reduced in size.

Autopsy abstract: The bladder is large with markedly thickened walls. Each lateral lobe of the prostate is the size of an English walnut. At the summit of the bladder and separated from the bladder cavity by a thin membrane, is a cyst the size of an average orange, which contains a thick, turbid, viscid, brownish fluid. The lining of this cyst presents an irregular surface, but there are no distinct rugæ. The irregularities of the cyst lining are present upon the upper surface of the intervening septum between it and the bladder cavity, and the rugæ of the bladder are continued upon its inferior surface.

The ureters are dilated, as are also the pelves of both kidneys. Careful dissection failed to reveal further urachus remains in the abdominal wall or about the navel. Microscopic examination of the septum between cyst and bladder cavities disclosed the fact that the muscular coats of the bladder wall were not continued into the septum. This fact, taken in conjunction with the position of the cyst and the fact that the peritoneum of the abdominal wall was reflected upon the back of the cyst and from thence upon the back of the bladder, leaves no doubt but that the cyst represents the unobliterated and dilated lower end of the urachus.

Dr. F. E. WALLACE presented a case of *suppurative pancreatitis.*

Mrs. F., aged 26 years, Irish nationality; mother of two children. She was admitted to St. Elizabeth Hospital Oct. 26, 1896. Family history negative.

In the past two years she has had four or five attacks of pain in the region of the gall bladder with slight icterus. She has also had one miscarriage. Her present illness dates back five weeks, when she had attacks of pain in the epigastric region with nausea, vomiting and thirst. These symptoms persisted for three weeks and then abated under treatment. Five days ago vomiting began and persisted up to the day of her entrance into the hospital. She was admitted for an operation, a probable diagnosis of gallstones having been made.

On admission her condition was as follows: Temperature 100.4 degrees, pulse 114, strong and wiry, hurried respirations; face highly flushed; nausea and vomiting; pain in epigastric region; great thirst; bowels confined, and passing small quantities of urine.

Urinalysis showed one-fifth by bulk of albumin and large quantities of biliary coloring matter. The operation was postponed. Sp. gr. 1,015 and an acid reaction.

Alcohol sweats were given and following the use of this treatment the albumin diminished one-half.

Oct. 27—Thirty-two ounces of urine passed in the previous twenty-four hours. The symptoms of nausea, vomiting and thirst continue.

Oct. 28—Patient passed but 16 ounces of urine in the last twenty-four hours.

Oct. 29—Heart seems growing weaker and is passing but little urine; the feces and urine being voided at the same time. During the last three days the temperature has been one to three degrees above normal and the pulse above 100.

In the evening of October 29 she passed into a deep coma and died at 11 P. M., the treatment having been symptomatic.

The autopsy was made by Dr. E. R. LeCount. A synopsis of the postmortem findings follows:

Body and tail of pancreas consisted of shreds of necrotic tissue extending across and lying free in a cavity formed by the stomach, the retro-peritoneal and perirenal adipose tissue, the transverse mesentery, the duodenum and the tissue of the lesser omental cavity, as well as some loops of the small intestines and colon. The walls of this cavity were necrotic, dark gray and slaty in color. The cavity contained fecal matter from perforations of the colon and stomach. The head of the pancreas was the least involved.

There were many small gallstones and the gall bladder was contracted and small from connective tissue bands in the walls.

Disseminated in the omentum, mesentery and abdominal fatty tissue generally were small grayish areas such as are seen in fat necrosis. Acute parenchymatous nephritis was present. The spleen was small. The heart and lungs appeared normal.

Dr. Arthur R. Edwards presented:

1. *Urethral stricture with extravasation of urine.*

These specimens are from a case of urethral stricture in which the patient had been treated on a previous occasion for stricture and retention of urine (as a sequence of the stricture) successfully by dilatation of the urethra with sounds. The patient left the hospital after this dilatation had been effected. The history of the interval between his discharge and return to the hospital is somewhat meager, except that he stated he suffered again from retention of urine and was unsuccessfully treated by sounds by a physician. The sounds were passed many times, consisted of various calibers and shapes, and the patient had had a considerable quantity of blood escape from the urethra, but the passage into the bladder was not reached. The patient entered the hospital in a delirious condition, and the true state of affairs was not appreciated, as the history was obtained only

after his death. He had been in the hospital some little time with retention of urine when periurethral abscess pointing in the perineum, which was incised and which shows in the specimen. There was afterward infiltration of urine, not so much into the perineum, the scrotum and the soft tissues of the external genitalia as upward into the abdominal muscles, especially into the recti.

At the necropsy the findings in the rest of the body were practically negative, except there were in the lungs, which are unfortunately not here, one or two small metastatic abscesses in the right lower lobe. In some of the larger veins outside and back of the bladder there was a suppurative thrombo-phlebitic process. The specimen itself distinctly shows the stricture, and proximal dilatation of the urethra, the stricture being about two inches from the external meatus. Further up is the point where the incision had been made from the back of the urethral abscess into the urethra itself. Just above the point of division of the urethra where the tissues are disorganized we found a peri-urethral abscess. The cut which you notice about the neck of the bladder was made at the opposite direction to see if there was a deeper process in the prostate. There was very intense cystitis, para- and peri-cystitis. The recti muscles on each side of the pubes were greatly disintegrated, and the foul decomposition had extended to a lesser degree over quite a distance in the abdominal walls.

The pathologic process did not extend to the ureters or to the kidney.

2. *Carcinoma of the cervix uteri.*

The second specimen is an ordinary carcinoma of the cervix uteri in which a history was given of the disease lasting for about twelve months before the patient entered the hospital. She was in the hospital only a comparatively short time before she died. Three or four months prior to her admission there was a very offensive discharge, which was present when the patient was admitted.

An examination showed the pelvis to be extensively infiltrated with the neoplastic masses. The abdomen was somewhat rigid and contained palpable masses.

The subphrenic organs are shown here, although they are of little interest beyond the invasion of the liver by the tumor and,

what is more interesting, the invasion of the diaphragm, which shows distinctly. In the hilus of each lung the secondary deposits were lacking; yet on the upper surface of the diaphram the lungs were adherent to it and the subpleural lymphatics are involved.

# SOME REMARKS ON MALIGNANT GROWTHS.

BY EDWIN KLEBS, M.D.
CHICAGO.

The expression "malignancy" is now reserved for such pathologic new formations that will often return after removal and form metastases, if not entirely removed. As the first depends upon incomplete removal, mostly depending on dissemination of tumor-germs in the various forms of the primary growth, the latter property only is the true feature of malignant tumors.

To clear up the nature of this property is a task of the highest scientific and practical importance, and it seems always convenient to review our notions on these points, even though they are not wholly conclusive. At least, such an examination of facts will show the way for further investigation and secure the practitioner and pathologic investigator from mistakes, by removing misunderstandings.

Separating the infectious tumors from the organoid growths, in the second part of my "General Pathology" (1889) I think I have placed the question somewhat clearer. The organoid tumors spread by dissemination of tumor-cells; the infectious tumors by dissemination of microbes.

Now, in this decennium, attempts were renewed to subject the organoid growths also to the action of

microbes. Sudakewicz, Ruffer and others regarded the long-known hyaloid masses, intracellular and extracellular, found in carcinomas, to be plasmodia or coccidia, and the various forms of those things, namely, the concentric or radial striping of globular masses, induced observers of high standing, as Metschnikoff, to accept this suggestion. I have shown ("General Pathology," ii, p. 126, fig. 11, and p. 152, table 17) the formation of such bodies in blood vessels of the brain, in chorea hereditaria, in the lymphatics of the lungs, in chronic bronchial croup, and in an acute atrophic liver, processes in which the inoculation of blood and lymph seems to be impaired.

Further, if there were microbes in malignant tumors they must grow and develop under well adapted conditions of life. As all attempts of cultivation outside of the body had failed, I implanted living carcinomatous tissue from man into the livers of a number of rats, that showed very often spontaneous development of carcinoma and seemed therefore to be highly predisposed to this disease. These particles contained human epithelial cells and the hyalin bodies. The cells showed in these experiments the first signs of farther development in the formation of microbes, but were involved later; the latter disappeared in a short time without a tendency of development.

I can not accept the objection of Metschnikoff that coccidia of one animal would not grow in another, for these suggested coccidia were included in living and to a certain degree developing human cells. That they would not develop under these conditions shows quite clearly that they are not living bodies at all.

After the coccidium theory had slumbered for years,

came the blastomycete- or yeast-theory of the Italians. The extracellular disposition of these bodies shows clearly that they can not be the cause of tumor-propagation by cell-dissemination. As one of the observers contended that these bodies were only found in certain parts of the tumors, I encouraged a good microscopist working in my laboratory, Dr. Döpfner, of Chicago, to undertake the difficult task of staining hundreds of microscopic preparations of a recurring and spreading lymphosarcoma, operated by Dr. C. Beck, in the Post-Graduate Medical School. It seemed more probable that we should have positive results in that case, as I had cultivated some yeast or blastomycetes from this tumor, coming into my hands immediately after the operation. The bodies, on fluid meat-peptone, found in cultures were somewhat smaller than human red blood corpuscles, round, quite circular, with a distinct membrane, forming internal spores and also external buds. (Knospung.)

From all these circumstances I do not think that it was a fortuitous incident, but that these growths came from out the tumor. Indeed, there were found by Dr. Döpfner in some of the preparations round bodies stained deep black with aqueous anilin gentian violet, and discolored with oxalic acid, 1 per cent. But they were smaller than the yeast corpuscles, some very small, and showed no signs of vegetation, either as buds or internal spores. Moreover, they seemed to be in connection with red blood corpuscles, which retain also other anilin dyes, namely, after using corrosive substances, mordants, as after the use of iron-ammonia-sulphate (Heidenhain).

The last prove what I have proposed long before R.

Koch, in such cases to ascertain the etiologic connection of an organism with a certain disease; the synthesis of the same disease by the organism I have not yet shown, but it will be made later, notwithstanding that it may fail by not having suitable animals, positive results alone being conclusive.

The lympho-sarcoma having a place on the limits of infectious and organoid tumors, the result of such experiments would not invalidate our notions of true organoid tumors, which disseminate alone by tumor cells; a form of generalization that is not infection, but must be called decidedly *implantation.*

It is one of the best confirmed pathologic facts that every true carcinoma spreads by the transportation of its own cells through lymphatic spaces and blood vessels. The same is demonstrated in a very great number of malignant tumors; also of such originating from the tissues of the middle germinal plate, the endothelioma, the enchondroma and the sarcoma. It is also true for malignant neuroma.

The demonstration of this fundamental fact naturally is the more sure, as the specific histologic feature of the disseminated cells are more evident, as is the case in epithelial, cartilaginous, nervous or mucous cells. But it is also assured by the identical composition of the youngest metastases exactly showing the same histologic structures as the primary tumor.

Further we can say, that every carcinoma commences with the formation of metastasis spreading; or expressed in another way, the true nature of carcinomatous condition is the dissemination of certain epithelial cells. If we have the opportunity to examine the first stage of carcinomatous development, we can

perceive this fact and will be inclined to assert such a diagnosis if we can demonstrate this epithelial displacement.

In this fact reposes the theory of R. Virchow, declaring the carcinoma as an heterotopic development of epithelial cells. Cohnheim, *vice versa*, thought that epithelial tissue displaced in embryonic tissue may be the origin of cancer, while Ribbert, during the last year proposed the opinion that every cancer commences with epithelial developments near the normal epithelial covering, but originating from embryonic epithelial germs.

The theory of Virchow is no more acceptable, since we know the sharp division between the descendants of the different germinal plates, and the theory of Ribbert reposes on the hypothesis of germinal displacement of single cells, not demonstrated, probably not demonstrable. The broadest pathologic view showed Cohnheim's theory of the highest value for the understanding of tumor formation, but not for malignancy.

If we remember the large number of embryonic implantations, we must positively deny that they show a disposition for malignancy. All dermoids or natural graftings of skin particles in the depth of the organs can grow, and many of them, as the dermoid of the ovaries, will become very dangerous in later life, but only by mechanical influences producing irritation of the peritoneum or perforations into the intestine or the urinary bladder, seldom also of the abdominal wall. But I do not remember one case of carcinomatous degeneration.

The same benign or only locally dangerous course show the fetal implantations, the dermoids containing

whole organs, as I have shown, dispersed parts of a second fetus included in the abdominal cavity of his brother. Here the destruction of the included fetus can be so great that the different tissues seem to have lost all their natural connection, lying pell-mell, and notwithstanding we observe here not the active penetration of connective tissue by epithelial cells, as in the cancer. Where two tissues develop together the relation between them is always the normal in these cases.

But there exists a second kind of tumor, apparently resulting from embryonic influences demonstrable nearly in all organs. In these certain parts of the tissues, composing otherwise normal organs, conserve their embryonic conditions. To this class belong most of the congenital multiple tumors, the multiple neuromas and neurofibromas, the multiple enchondromas and the multiple adenomas.

I will refer here only to the last, as they seem by their epithelial origin to be mostly adapted for cancerous growths. These adenomas are preferably developed in the ovaries, the liver, the kidneys and the mammary glands.

In the ovary they are found under the two forms of so-called compound cystoids and of papillomatous tumors.

The first, the mucus-producing form, is developed, as I have shown a long time ago, from the embryonic tubular structure of the ovarian glands (Valentin, Pflüger), not transformed to Graafian follicles.

Already Spencer Wells remarked that after extirpation of a cystic ovary the other oftentimes developed in the same manner. I could sometimes demonstrate

the stages of this affection in the seemingly normal organ of the other side.

The exceedingly frequent recurrence of the adenoma of the breast after extirpation of the greater knots is well known; also the fact that these recurrences, starting from embryonic remains and finding place for development after removal of the first, are not at all dangerous or give a disposition to cancer. I saw such a breast operated upon more than twenty times and containing many more adenomas of microscopic volume.

The adenomas of the liver are often so numerous, forming small gray nodules, that they may resemble miliary tubercules. But some of them can develop to very large tumors without causing metastases.

In the kidney, where these tumors form also multiple gray spots, composed of proliferating uriniferous tubes (not to be confounded with the disseminated germs of the adrenals), I have seen as the first case that came in my hand here an enormous tumor of this sort, operated by Dr. Ferguson, Sept. 30, 1896. The patient was a young lady from Canada, operated upon some years before for a cyst, opened through the abdominal wall, the origin of which could not be located. The kidney at this time was probably not enlarged and only one of the multiple adenomas was developed to a large cyst. Now, the whole kidney formed a tumor of two feet in length and one in breadth, reaching down into the pelvis and upward into the thoracic cavity, raising the diaphragm and displacing the heart and left lung.

The enormous tumor, enucleated with great skill and with happy result, proved to consist only of the

kidney; the normal kidney-substance formed a small strip at the one pole. The other pole contained a large cyst surrounded by soft gray adenomatous tissue. The median part was composed of grayish-looking, round adenomatous nodules, varying from the size of a chestnut to that of a man's fist, separated by very small tracts of atrophied kidney tissue. The cyst was formed more by necrosis and absorption of the necrotic tumor masses, than by distension of tubules.

As the recovery of the patient was effected in a short time and she gained very much (24 lbs., Jan. 30, 1897), it is not to be considered a carcinomatous development, which is also not at all sustained by microscopic investigation, showing only proliferating tubes.

In other tumors of this class we can observe the highest possible proliferation and dissemination of epithelial tissues without formation of metastases or dangerous development. So, in one case of double-sided papillomatous tumors of the ovaries, combined with a great urachus-cyst, operated by Dr. Franklin H. Martin in the Post-graduate Medical School, there protruded enormous papillomatous masses, covered with thick layers of proliferating epithelial cells, freely in the abdominal cavity without giving rise to secondary development. These masses and also the same formations filling up the distended Graafian follicles exhibited a very interesting production of ovum cells, described first by Ernst Neumann in Königsberg, a true adeno-papilloma oviparum.

All these excessive productions of epithelial cells, limited to physiologic condition in the behavior and relation of tissues are quite different from carcinomatous epithelial productions.

Further, we must say: dissemination of normal epithelium produces no carcinoma. Such disseminations occur in the female body at every menstruation. All attempts made by investigators to produce carcinoma by implantation in lymphatic spaces have totally failed.

The hitherto reported observations lead to the conclusions: 1, that the embryonic condition of any part of the body can be regarded only as one of the causes of tumor formation, but not of the malignancy of tumors; 2, that the malignancy of tumors, the faculty of spreading by its elements, is due to a modification of the tumor cells.

The next question will be to disclose the nature of carcinoma cells and, if possible, the origin of this modification of cell life.

As to the first question, it suffices to indicate the two well known properties of these malignant cells, as we can now say, the faculty to grow and proliferate in a strange tissue and the deficiency of tissue formation. The epithelial cancer cell produces in any organ into which it is transported by their own movements Waldeyer's contractile epithelial pus-cells, or by the currents of lymph or blood, irregular cell masses, resembling somewhat the original tissues, flat or cylindric cells, but very different from the original masses. The relation of the cancer cells to the surrounding stroma is deeply altered; blood vessels and connective tissue grow, as it seems, stimulated by the cancer cells in the same excessive and irregular way as in the primary tumor.

We can express this simple fact without any hypothetic suggestion as the disturbance of the laws of tissue formation or of normal growth.

As to the second question, the causes of this lawless cancerous growth, we must refuse to accept the embryonic theory and, so far as our knowledge now reaches, also the microbic theory. If new investigations should detect an organism promoting this cancerous metamorphosis, and also present in all the other malignant tumors, as endotheliomas, neuromas, myomas, etc., certainly a very intimate symbiosis must be established between such organism and the cancerous cell, the medium of metastasis. Intracellular microbes would only cover this claim.

As every effort to demonstrate such a microbe has failed, we must ask if the clinical features of malignancy suggest such a theory. But as the observations of direct or indirect infection and the formation of endemic or epidemic development of cancer (not regarding the more seldom developing forms of other metastatic growths), are not present or available in any extent, I will not delay this exposition of facts by criticising the opposite assertions, familiar and local differences in the frequency of cancer.

But I must insist on one fact not enough regarded, as it seems to me, that in a higher way as the clinical facts invalidate the idea of infection, that is, the originating of true cancer in other benign or infectious tumors.

With very few restrictions we can point out as a general law, that the origin of cancer is always a secondary metamorphosis of proliferating tissues.

That this is the case in a considerable number of cancerous growths nobody will deny; I remember the development of cancer in lupous or tubercular ulcerations of the skin, in the chronic ulcer of the leg and

the round ulcer of the stomach, also in the chronic hyperplastic affections of mucous membranes. The cervix uteri gives many good examples, by the way, oftentimes affording diagnostic difficulties. Before the ulceration they seldom can be detected to be of a cancerous nature. Therefore the microscopic diagnosis of all the hypertrophic adenomatous, papillomatous and polypous forms of vegetations of the neck of the uterus is of the highest value for the question of radical operation. Once, in the practice of Breisky in Prague, I found a very well developed cancer in a pedicled small polypus of this part.

The highest support for the successive development of malignancy is given by cases in which foreign bodies promote first the development of simple benign tumors, which later on are changed to cancerous growths. The calculi in the gall bladder and foreign bodies (once a cherry stone) in the stomach, I have observed as the causes of papillomatous, later cancerous growths.

Another instructive object is found by the papillomatus growth of the urinary bladder, developing oftentimes in younger years and leading by repeated bleedings to the highest forms of anemia. I have observed a number of these cases for years, the healing after natural expulsion of these tumors and otherwise the carcinomatous metamorphosis, if these long standing tumors are not eliminated in the natural way or by surgical help. In one of my friends in Switzerland I have followed this development for years, in vain insisting on operation.

Now, I have here received from Dr. Kovats in Mil-

waukee, Wis., such an object, operated as I hope at the right time, but showing as I think a partially malignant metamorphosis.

In former times it seemed sufficient to give a bad prognosis, if in the urine of such cases were detected many large and irregular epithelial cells, and indeed, many of these patients died cancerous, as the operation was not undertaken. Others, in which natural elimination occurred, recovered. Hence, the conclusion is secured that the once benign tumor becomes malignant after a time.

I can show you microscopically in this tumor one part in which, at some places the intrusion of the covering and highly vegetating epithelial cells into the stroma has commenced, and in which epithelial cells at one place forming a rounded heap, are present in a wide lymphatic space, included by a fine fibrinous network. Without imbedding in paraffin it would be not possible to obtain from such tumors complete and sufficient thin slices (1-100 millimeter).

In this case the basis of the tumors containing broad arteries was found to be quite free from such development. So I could notwithstanding express a somewhat hopeful prognosis. The future will reveal if this view is correct or not. The radical cure of cancer by total extirpation is no more questionable.

But in such cases there will remain oftentimes a doubt. We must ask if really this penetration of proliferating epithelial cells will always be sufficient for the diagnosis of cancer. If we find irregular growing epithelial masses in great extension in an also granulating stroma, there can not be justified a doubt. But if this process is going on to a very small extent,

this doubt must arise the more, as one is convinced of the harmlessness of normal epithelial cells introduced by only mechanic forces into the lymphatic spaces. I have reminded you of a number of such facts.

Therefore, we must search to point out the true features of cancerous proliferation. If the epithelium cells are the seat of this metamorphosis, the proliferating cells only can give us the explanation for this biologic change. The irregularities in mature age depend upon modified development.

The principal feature of carcinomatous cell proliferations can be denoted as *hypermitosis*, depending upon supernutrition of the cells. In the place of the normal well-known forms of karyokinesis we observe in every carcinoma or other malignant growth irregular and exaggerated forms of mitosis. I have marked out a part of these processes in my "General Pathology"; also Hansemann of Berlin has given valuable observations of the same, but regards more the phases of division as the preparatory stages of the process. Here, let me give a more complete exhibition of the process.

As I have remarked in my first publication, the epithelial cells tending to karyokinesis take up a greater quantity of coloring matter in the protoplasma and in the nuclei; both enlarge, the first staining more intensely with acid anilin dyes, as eosin or methyl orange, the nuclei with hematoxylin. In intensely proliferating objects, in which these very transient processes are fixed by rapidly killing the cell life,[1] one notices after staining the fine sections (1–100 mm.

[1] I use now for fixation a mixture of alcohol, about 4 parts, with ormalin (40 per cent.) 1 part.

thick) with hematoxylin[2] and eosin, that in different parts of the preparation black (methyl orange) or deep blue (eosin) stained nuclear masses are present in abundant quantity, centers of proliferation (Flemming). In the same parts are recognized the different stages of karyokinesis and lastly a greater accumulation of leucocytes with fragmented nuclei. The last are irregularly disposed; some cells are crowded with them, others are free or we find only some leucocytes between the cells.

This seems to be the commencement of the process; the cells with richly staining nuclei contain a somewhat smaller number of fragmented nuclei, the bodies of them are dissolved and the stained leucocytic nuclear masses seem to be taken up by the nuclei of the epithelium cells. The leucocytes feed the epithelium cells. After this supernutrition the nuclei will be swelled up more and more by a colorless fluid, the membrane of the nucleus becomes thinner and thinner, whereas the stained nuclear substances commence to show the different stages of karyokinesis.

The forms of the spirema (Clew, Knänel) are not so clear as in normal mitotic division in consequence of the tight accumulation of the nuclein. In the first time of this stage it makes the impression as if these masses form an homogenous semiliquid fluid, the limits of it being not so clearly defined.

As a consequence, there begins the separation of the

[2] My hematoxylin solution is prepared in the following manner: One gram cryst. hematoxylin is dissolved by warming in 20 c.c. kresol water 2 p.m. There is added for every c.c. of this solution one drop of a concentrated solution of ammonia alum in kresol water and filled up with kresol water to 100 c.c. The solution is ready for use in twenty-four hours, deposits very small quantities that must be taken off by filtration, and stains the thin sections in one or two minutes.

nuclein into different parts, mostly forming manifold compound middle plates, often in connection with one another, often separating in three or four or more plates. But generally not all of the nuclein is transformed at once in this manner; greater or smaller quantities of it are disseminated in loose masses, showing the form of fine threads dispersed through the free parts of the clear nucleinic area, that is no more sharply defined against the red-stained protoplasma.

If the middle plates are separated or only curved a little with the concavity against the periphery of the cell one may notice one or two very small entrosomes or central corpuscles exactly in the center of the circle, a section of which is formed by the middle plate; the whole constitutes one "attraction-sphere." The central corpuscles of the sphere are too small for showing a well-defined color, but they are best seen in preparation afterward stained with safranin. I suppose that these corpuscles are formed of the nucleolus not visible in this stage, but very large in all perfect nuclei of carcinomatous cells.

The formation of asters or stars, I have not observed in these hypermitoses. This stage must be very transient. But I have proofs that this metamorphosis and the formation of new nuclei is going on by repeated changes successively in one and the same cell, a feature quite characteristic of carcinomas. I can show you such cases in which the whole periphery of the highly enlarged cell contains well-formed nuclei, lying one near the other and containing a red-stained nucleolus, whereas in the central part the younger stages of karyokinesis are developed.

As a middle stage between these two phases, the curved middle plates and the perfectly developed nuclei, I have observed a few times large round vacuoles resembling the physalides described by Virchow, limited by a very fine membrane, and containing in a clear interior an indefinite mass stained red with safranin, possibly a nucleolus in formation; also a very few nucleinic threads. That in this case a deficiency of this latter substance resulted in a retarded or insufficient nucleus formation, I can not say with certainty, but it seems not improbable. If the attraction sphere acts by pulling of a part of the nuclein from the middle plate, it could be that this action has been insufficient in some instances. The spindle-shaped fiber of the attraction-spheres I have not been able to stain, but I am trying the methods of Flemming, which, as that observer remarks, are not always efficient. Possibly they will stain better in preparations fixed with osmic acid.

If we look over the whole process we see clearly the following phases of development of tumors, ending in the carcinomatous metamorphosis:

The first stage is that of chronic irritation or inflammation, originated by microbes or by mechanical, or probably also by chemical influences producing a chronic state of hyperplasia, the so-called benign growths composed of all normal tissues constituting the part. This development can lead to diffuse hyperplasia or tumor-formation.

The second stage commences with new emigration of leucocytes and progressive development of certain cells, losing tnrough the hypermitotic production the faculty of normal tissue formation. The excessive

proliferation and the possibility of living in a strange medium promotes the formation of metastasis, the true feature of carcinoma.

I will add the remark that this mode of development seems to exclude the healing of malignant tumors by irritations, the electrical, microbic or chemical treatment. The delimitations of emigration processes would be preferable to the necrotising effects of these treatments. But the surest way will be always the removal in time. Possibly we may prevent or modify the cancerous metamorphosis by inhibiting substances with negative chemiotaxis, repelling the leucocytes, as the by no means sure healing influence of some bacterial toxins seem to show (Coley, Tavel, Emmerich and others).

For the diagnosis the early and repeated microscopic investigation of the diseased part will be the only reliable method. But to make this method effectual the small removed parts must be fixed immediately after removal. Our solution seems to be commendable, as the substances composing the fixative, alcohol and formalin, are in the hands of every surgeon.

DISCUSSION.

Dr. GUSTAV FUETTERER—In connection with Professor Klebs' paper I wish to say that I believe the mechanical influence is the main factor in the cause of carcinoma; that it must be a chronic one and *of a certain degree or quality.* I think the latter is very important. This is especially shown in carcinoma of the gall bladder. If we remember that this disease occurs especially in females, while the character of gallstones is the same in the male as in the female, and gall bladders and livers are also alike, it seems evident there must be some extra cause peculiar to females that contributes to the probabilities of gallstones causing carcinoma of the gall bladder,

and that is the pressure from the corset. The pressure of the liver against gallstones in the gall bladder is not sufficient to cause carcinomatous growth, but when a corset presses the costal arch against the liver, then the necessary degree of friction becomes possible. This I wish to emphasize. I believe with Professor Klebs that there are strong reasons against the micro-parasitic origin of cancer, but notwithstanding this, examinations in this direction should not be entirely discarded. Probably the strongest reason against a micro-parasitic origin lies in the fact, that in carcinomatous metastasis the cells of the organ invaded do not become infected and do not show carcinomatous growth, while the metastasis develops pure and simple from the invading cells.

Dr. E. R. Le Count—One year ago I examined approximately fifty tumors with the object of ascertaining how much irregular karyokinesis occurred. These tumors were fixed in Flemming's solution and stained according to the methods of Flemming and other cytologists. The difficulties of recognizing irregular karyokinesis are not a few. One question that arises at once is whether the tissue shall be microtomized so that more than one section is obtained of the same dividing nucleus or whether an effort shall be made to make the sections each one cell thick. The study of perfect series of sections is necessary if an effort is made to have the sections very thin (1 to 24) or erroneous conclusions may be made concerning atypical or unequal nuclear division. After a trial of saffranin and the iron hematoxylin methods it was learned that the achromatic elements of the nucleus stain very well with Loefflers methylen blue. Whether this latter method would operate favorably in tissues hardened in formalin solutions I am unable to state. Atypical karyokinetic figures were found in all tumors examined, but more frequently in carcinomata. They were also more frequent in sarcomata than in tumors ordinarily considered benign. Hypermitosis was found to take place with greater frequency in carcinomata, but no cells were observed with some nuclei dormant and others in various stages of division, such as Professor Klebs has sketched here. In the section series examined by us it was not rare to find the same nucleus in three different sections, the cells undergoing cell division being large and the sections extremely thin. In one instance

a carcinoma cell showed six perfect spindles, five being grouped around a central one, the chromatin threads had become so arranged that they formed a regular pentagon. It was intended at that time to make a demonstration before this Society, illustrating to some extent the forms of karyokinesis in tumors, but the difficulty of securing artificial light that would answer the purpose has up to this time prevented its execution.

Dr. C. S. Bacon—In connection with the practical remarks of Professor Klebs concerning the influence of streptococcus serum, I would call attention to the fact that a few observations have been made in the clinic of Küstner, in Breslau, in which both the streptococcus serum and also alcohol were injected into the cancerous tissue with the effect of checking the growth. Later the tumor was removed and a microscopic examination showed an increase in the connective tissue, and in that way an apparent inhibition of the further growth of the cancer by the production of a lessened nutrition, which is rather in opposition to the suggestion advanced tonight.

Prof. Edwin Klebs—I am very glad to hear Dr. LeCount say that he has found the same condition that I spoke of in my paper. But what I wish to speak of more fully is the theory of feeding of the epithelial cell by leucocytes and the repeated formations of series of nuclei in one cell. There is undoubtedly the generation of many cells in one and the same cell.

I might say a word or two regarding irritation in its relation to carcinoma. Instead of this futile expression, I wish to put certain influences as the cause of carcinomatous growths, in the first line chemotactic processes. The carcinomatous cells may be denominated as germs. If foreign germs will at once be detected, as Fuetterer seems to accept, I can not say, but certainly they must be very intimately connected with cancer cells, as these alone take part in the dissemination of malignant tumors. But as yet such organisms are not demonstated conclusively. From a clinical standpoint I must accentuate the contrast of cancerous and microbic infection. A cancer of the uterus can exist for a long time and escape detection, and cancerous infection should be expected in the genital sphere, if it occurred anywhere. I have tried for many years to detect such cases and have found none. Otherwise we can observe carcinoma spread from one mucous membrane to the other in

the same person, if there be immediate contact, but we very seldom see it without such contact. I have demonstrated such implantations of epidermoidal cancer of the mouth, the pharynx and the esophagus into the mucous membrane of the stomach, but in these cases also I think that a greater quantity of cancerous cells must come in contact with a probably altered mucous membrane to make efficient this grafting of cancer. I have fed some of my white rats with cancerous disposition with carcinomatous masses from men and rats without any effect; only one of these rats showed a cirrhotic liver, an alteration that I have not seen in any other of these animals. It is not acceptable, that if the suggested cancerous microbes had been introduced for weeks in the body of animals, highly disposed for cancerous growths, they should have not found a good soil in this organ.

If we make this distinction between infection and implantation, we need not for the malignant tumors the suggestion of microbes. And if we will consider this possibility, we must have a different microbe for every different tumor. If we do not need them in benign tumors, as fibromas and papillomas, must we accept an infection of these tumors if they become malignant?

## Regular Monthly Meeting, January 11, 1897.

The President, Dr. James B. Herrick in the Chair.

H. Gideon Wells, Ph.B., read a paper on

# A CASE OF CONGENITAL SYPHILIS COMPLICATED BY A MIXED INFECTION WITH THE STAPHYLOCOCCUS AND STREPTOCOCCUS PYOGENES.

On April 29, the body of a child was brought to the laboratory of Rush Medical College for examination. The autopsy was performed immediately, before postmortem changes could have possibly occurred. The child was born in the practice of Dr. A. B. Strong, who furnishes the following history:

The mother was 20 years of age, a primipara, with a good personal and family history. She had been married one year. The labor was an uneventful one, a vertex presentation. The child was alive when born, but died after gasping a few times. The father was 23 years old and denied any specific history, as did the mother, and presented no suspicious scars. Dr. Strong, his interest in the case having been aroused by the condition of the child, conducted a careful investigation into the history of the parents, but was unable to obtain the slightest evidence of a primary specific infection in either. The mother was troubled after the birth of the child with constant dreaming, a symptom not present before that time, and which was

not relieved by administration of potassium iodid. The father spoke of aches and pains in the lower extremities which he said he had had for years. On examination two subcutaneous swellings were found attached to the crest of the tibia, just below the tubercle, and a third on the inner side of the right femur. Treatment with the iodid of potassium and the biniodid of mercury was followed by some reduction in the size of these swellings and the disappearance of the subjective symptoms. On cross examination the patient stated that these swellings had been present since he was a boy. Asked about his father he stated that he knew little about him beyond that he was a sailor. Beyond this reference to the third generation there was no obtainable evidence as to the source of infection.

The findings at the autopsy were as follows:

The body was that of a child, 50 cm. long, and weighing 2500 gm. The abdomen was rounded and firm, and the umbilical cord, which was moist and fresh, was tied with a silk ligature. The skin was covered over almost the entire body with eruptions, most numerous about the ears, face, forehead, hands, feet and buttocks. Most of these eruptions contained a serous fluid, but many were filled with a purulent fluid, and some with a firm, cheesy substance. The peritoneal and pericardial cavities were normal, as were the pleural except for a thin, white, pellicle, covering the pleural surface of the base of the left lung. The heart muscle showed several white, indurated areas, the largest lying on the ventral surface, and about the size of a dime. The heart was not opened, but on account of this rather unusual condition was preserved

for a more complete special examination by Dr. Le Count. The thymus contained several soft, light colored areas, which on section yielded a gray viscid, fluid. Otherwise the organ appeared normal. Beyond an unusual amount of blood the thyroid and salivary glands showed no changes. The lungs were firm, noncrepitant throughout, and pieces placed in water sank quickly to the bottom. They presented both under the pleura and in the deeper parts of the lungs, white areas, firm and smooth on the cut surface—a typical pneumonia alba. The liver was large and firm, the right lobe reaching nearly to the level of the umbilicus. On section it was found to be very full of blood, but there were no other changes. The biliary system was normal.

In the stomach was found a large amount of jelly-like mucus, and the intestines contained the usual amount of meconium. The cecum was attached to all the adjacent coils of intestine by firm, fibrous adhesions, except the vermiform appendix, which was free. The mesenteric glands were enlarged.

The kidneys and supra-renal capsules appeared normal. The spleen was slightly enlarged and full of blood. No changes could be detected in the central nervous system. At the epiphyses of both the long and short bones the line of ossification was very broad, irregular and hemorrhagic. Ossification had not begun in the lower epiphysis of the femur.

Under the microscope many changes very typical of syphilis in the new-born were observed. The description of the various organs follows:

*Lungs.*—Both lungs were almost completely consolidated, the air vesicles having been dilated in but

a few places. The expanded vesicles contain a granular substance which in most places completely fills the lumen, and contains many poly-morpho-nuclear leucocytes and some flattened epithelial cells. The walls of the vesicles are quite thick, with some infiltration of leucocytes, and with greatly dilated capillaries. In many places the epithelial lining of the alveoli is absent. The formation of the consolidated portion by non-expanded alveoli can be determined only with difficulty, because of the degree of infiltration of the tissues. Everywhere, within and between the alveolar walls are poly-morpho-nuclear leucocytes, for the most part scattered singly but in some places collected in groups of a dozen or more. Occasionally the alveolar walls have been separated by slight hemorrhages, in which the blood contains many leucocytes but is not disorganized. Practically all of the bronchi and bronchioles have been filled with masses of cells, in some of which the nuclei stain deeply, in others scarcely at all. The walls show a diffuse infiltration with leucocytes, many of which are also to be found in the contents of the lumen. All the vessels are dilated with blood, and the walls of the smaller arteries are greatly thickened so that the lumen is practically occluded. The pleura, which is quite thick, is not as much infiltrated as the subadjacent tissues, but in the outer portion many of the nuclei fail to stain, and the tissue elements are much disorganized. The vessels in the pleura are much dilated with blood, and in some places slight hemorrhages have occurred.

*Liver.*—The vessels are greatly engorged, but nowhere can the blood be found outside the regular channels. The connective tissue is everywhere infil-

trated with leucocytes, which are also collected in groups in many of the intra-lobular capillaries. The parenchyma cells in some places seem slightly vacuolated and their nuclei stain faintly. The capsule is not thickened nor infiltrated, although the engorgement is most marked immediately beneath it.

*Kidney.*—The glomeruli completely filled Bowman's capsule, the capillaries being filled with blood. In a few cases the glomerulus is forced to one side by an extravasation of blood. In the convoluted tubules some of the epithelial cells lack nuclei, and a few of the collecting tubules contain blood. Occasionally poly-morpho-nuclear wandering cells can be found in the inter-tubular connective tissue. The blood vessels are generally filled with blood containing an unusual number of leucocytes.

*Spleen.*—This organ is extremely hyperemic, every vascular space being filled with blood. The Malpighian corpuscles appear small in contrast with the superabundant pulp surrounding them, but no changes can be detected in any of the structures.

*Adrenal.*—In the capsule of this gland are a few collections of epithelial cells packed closely into columns, with very little stroma, probably accessory suprarenals. Beyond a large amount of blood no changes are obseved.

*Gastro-intestinal tract.*—Beyond a slight infiltration of the connective tissue of the villi of the small intestine no changes can be detected.

*Thymus.*—The follicles show no change except those located near the walls of the abscesses before described. Here there is a marked increase in the connective tissue between the gland elements, and a

considerable infiltration with poly-morpho-nuclear leucocytes. In some follicles the glandular cells have mostly disappeared and many fragmented and faintly staining nuclei are seen, beside numerous concentric bodies staining with eosin and containing no nuclei, probably degenerated corpuscles of Hassell. Surrounding the abscess is a wall of varying thickness, consisting of an embryonal form of connective tissue with numerous large and deeply staining nuclei. This wall contains very few vessels, and is infiltrated with many poly-morpho-nuclear cells. The contents of the abscess consist chiefly of a granular matrix containing fragments staining with hemotoxylin, cells with a granular protoplasm and faintly staining nuclei, leucocytes and occasional red corpuscles. The leucocytes are the most numerous of these elements and are collected, especially near the walls of the abscess.

*Thyroid.*—Only a small proportion of the alveoli contain colloid material, most of them having their walls in apposition and showing no evidences of secretion. Colloid material is found in some of the lymph spaces of the secreting areas. There is a marked dilatation of the capillaries, especially about those alveoli which contain colloid. No other changes can be observed.

*Skin.*—A section through one of the eruptions shows the stratum corneum separated from the stratum granulosum by a homogeneous substance staining faintly with eosin and containing leucocytes, red blood corpuscles, squamous epithelial cells, epithelioid cells and shreds of necrotic tissue. In the center of the vesicle the stratum granulosum is entirely gone, only a thin membrane separating its contents from the con-

nective tissue below, which contains many round and poly-morpho-nuclear cells, especially just below its floor.

Cultures were made from the heart's blood, liver, kidney, thymus, lung, pleural exudate and the eruptions on the skin.

From the skin, cover slips showed many groups of cocci. The cultures contained but one form of organism, a coccus staining by Gram's method, arranged in groups and agreeing in its growth on culture media with the staphylococcus pyogenes aureus. Cover slips made from the exudate on the pleura showed numerous short chains of cocci. The cultures showed the presence of a streptococcus staining by Gram's method, and agreeing in its culture growths with the streptococcus pyogenes. Inoculations with this streptococcus into guinea pigs showed it to be very virulent, producing death in a short time. Cover slips and cultures made from the abscess in the thymus showed the presence of an organism apparently identical with that obtained from the pleural exudate. All the other organs gave negative results.

It is therefore evident that we have here to deal with a case of congenital syphilis, complicated by a mixed infection with the staphylococcus and streptococcus pyogenes. The diagnosis of syphilis is based upon the typical pneumonia alba and the universal and characteristic osteo-chondritis. The mixed infection is proven by the presence of the microörganisms in smear preparations from the thymus, pleural exudate and skin eruptions, and by the growth of similar organisms in cultures made from these sites.

Such a complication of infections is very unusual,

at least, for a search through the more recent literature has failed to reveal any reference to a similar case. In fact, mixed intra-uterine infections of any kind have been demonstrated but a very few times. One of the most recent of such cases is that reported by Dürck (*Münchener med. Wochenschr.* No. 36. 1896), who obtained from the tissues of a child born of a typhoid-stricken woman, which had lived but a few minutes, the typhoid bacillus and the staphylococcus pyogenes.

Infection with the pus microbes seems also to be a rather rare occurrence, by far the largest part of cases in which intra-uterine infection has been proven being cases of typhoid fever. Of the pyogenic organisms the streptococcus seems to make its way to the fetus much more often than the staphylococcus, as would be expected from its greater tendency to produce a general infection. Gustav Ricker (*Centralbl. für Allgem. Path.*, 1895, p. 49) has reported two cases of intra-uterine infection with the streptococcus, in one of which the mother had a streptococcus diphtheria, in the other a streptococcus infection following an injury. Lebedeff (*Revue Mens. d. Mal. d'Enfance*, March, 1887) has reported the case of a woman with erysipelas of the legs giving birth to a child with an erysipelas, and in whose skin a streptococcus was found. Here, however, the infection was traced from the mother to the child through the lymphatic system.

Chotzen (*Vierteljahrschrift f. Dermat.*, 1886) has observed that a streptococcus can be found in the tissues of a large proportion of the children dying of hereditary syphilis, basing his work on similar results obtained by Kassowitz and Hochsinger (*Wiener med.*

*Blatter*, 1886). However, these results have no bearing on intra-uterine infection, as the cases were all of children who had lived some time, whereas in the body of a six months fetus Chotzen failed to find the organism.

It is to be noticed that in all cases of intra-uterine infection reported there is some evident infection of the mother from which the infection of the fetus has been derived, while in this case there is absolutely nothing in the history that throws any light on either of the infections. It is possible that the mother, being in vigorous health, resisted infection by the organisms that had gained entrance into her system, while the diseased tissues of the fetus offered a favorable site for their localization and multiplication, it having been shown by Lubarsch (*Virchow's Archiv*, Bd. 124, Heft 1) that organisms can and do pass through the intact placenta. It has also been suggested that the infection might have occurred from outside, say from a preëxisting endometritis, through the medium of the fetal membranes. As to the possibility of such a transmission nothing can be said, as, unfortunately, the placenta and membranes were not available for examination. That the infection did not occur either just after or a very short time before birth is shown by the presence in the tissues of a reaction to the infection, as for example the formation of a connective tissue capsule about the abscesses in the thymus, which must have required a considerable period of vital activity after the inception of the infection.

It is interesting to note that in the thymus of this case there existed abscesses produced by pyogenic organisms (as is proven both by the bacteriologic

findings and the microscopic appearance of the lesions) since similar areas have been generally considered as quite typical of congenital syphilis. They were first described by Dubois (*Gaz. Méd. de Paris*, 1850, p. 393), and by many authors named after him Dubois' abscesses. Orth (Pathologische Anat., p. 89) considers them as due simply to the syphilitic virus, and no relation between them and pyogenic processes seems to have been demonstrated. This case suggests, therefore, the possibility that in many of the cases of thymus abscess observed in syphilitic children, careful bacteriologic investigation would have demonstrated the presence of pyogenic organisms, although it is possible that the abscess formation may represent the site of a preëxisting syphilitic lesion.

PRESENTATION OF SPECIMENS.

Dr. JAMES B. HERRICK exhibited a specimen of *Gummata of the Myocardium.* This heart, taken from the museum of Rush Medical College, was obtained at an autopsy made by the coroner's physician, on an adult male of average size who had been found dead. There is, therefore, no clinical history save that of sudden death. Other anatomic evidences of syphilis were present. The heart is a trifle large, the wall of the left ventricle thickened and the cavity somewhat increased in size, the endocardium showing a few grayish areas over the underlying gummata. The pericardium is free and smooth. The valves are unaffected save for some grayish plaques in the mitral close to a gumma. In the upper third of the interventricular septum, close to the aortic valve is a firm nodule the size of an olive bulging into either ventricle. The endocardium over the mass in either ventricle is thickened, grayish, somewhat uneven from slight irregular eminences in the nodule. One of the chordæ tendineæ running from the tip of a papillary muscle in the right heart to the posterior tricuspid leaflet, is firmly adherent about its middle to the thickened endocardium over the gumma. Some interference with the closure of the valve probably resulted. A few smaller nodules are found in

the wall of the left ventricle, and here and there are a few grayish streaks in the myocardium.

Microscopically a section from one of the smaller nodules from the wall of the left ventricle shows the accumulation of round cells between the muscle fibers with consequent atrophy of the latter. In places an encircling wall of fibrous tissue is forming. No marked central necrosis has as yet taken place.

Dr. HERRICK further briefly discussed the subject of acquired syphilis of the heart as it affects the endo- peri- or myocardium, in fibrous or gummatous forms. The difficulties of anatomic and clinical diagnosis save by exclusion of other causes of cardiac disease and definite proof of constitutional syphilis, were also referred to. The therapeutic test of improvement under anti syphilitic treatment was not conclusive. Rosenfeld's asthma syphiliticum and Semmola's twenty-seven clinical cases of syphilitic disease of the heart, must be viewed somewhat skeptically in the light of Mracek's finding of only six anatomic diagnoses of syphilis of the heart in 100,000 autopsies in Vienna.

The effects of gummata of the myocardium were 1, weakening of the wall with perhaps aneurysm or rupture; 2, obstruction of a cardiac orifice by pressure, or 3, interference with the valvular mechanism by involvement of the valves themselves or by deformity of papillary muscle or chorda tendinea (see specimen); 4, the breaking down of the gumma, discharge of contents into the circulation with emboli in distant organs (*cf.* case of Oppolzer); 5, from pressure upon, or involvement of cardiac nerves, vessels or muscle, marked interference with performance of function as shown in palpitation, arythmia, dyspnea, angina. Sudden death, as in this case, was common in gumma of the heart.

Dr. E. R. LECOUNT exhibited a specimen of *Gummata of the Heart in Congenital Syphilis.* The gummata of the heart were found in the body of a child born in the practice of Dr. A. B. Strong of Chicago, to whose kindness we are indebted for the following findings:

Death occurred almost immediately after birth and the autopsy done at the Pathological Laboratory of Rush Medical College resulted in the anatomic diagnosis of: 1, syphilitic interstitial pneumonia (nodular); 2, syphilitic osteo-chondri-

tis; 3, gummata of the heart; 4, pustular syphilides of the skin; 5, multiple foci of suppuration in the thymus; 6, hyperemia of the liver and spleen.

The heart showed a large white area on its anterior surface and three similar smaller areas on its posterior surface. On section these all showed irregular margin, lessened consistency and a disposition to spread out near the pericardium. The columnæ carneæ were involved in the larger area.

Microscopic examination of these areas revealed a proliferation of the connective tissue elements in the shape of oval or partially fibrillated cells. This was most marked around the vessels where proliferative changes in the adventitia were extensive. Widely scattered foci of necrosis of heart muscle fibers were present and these were the seat of infiltration with leucocytes.

The diagnosis of syphilis was confirmed by the microscopic examination of the liver in which a characteristic interstitial hepatitis was found, also by the examination microscopically of the osteo-chondritis and the interstitial pneumonia.

The literature on congenital heart syphilis has been thoroughly summarized by Ludvig Hektoen in a case reported of multiple foci of interstitial myocarditis in hereditary syphilis (*Journal of Pathology and Bacteriology*, Edinburgh and London, January, 1896) and a search through the Index Medicus failed to show any additional cases reported since. The above author was able to find only nine previously reported cases of hereditary heart syphilis, these being collated in the well known treatise by Mracek (Die Syphilis der Herzen bei erworbener und ererbter Lues. *Arch. f. Dermat. u. Syph.*, Wien, Erganzungsheft ii, 1893) and the syphilitic nature of some of these was doubtful.

Dr. Weller Van Hook briefly discussed *Syphilis of Bones*, as illustrated by specimens from the museum of Rush Medical College.

DISCUSSION.

Dr. R. H. Babcock—With reference to the location of the gumma in Dr. Herrick's specimen it is interesting to note that of Grenouiller's nineteen cases, gumma was found nine times in the wall of the left ventricle and but once in the septum, six times in the wall of the right ventricle, twice in the wall of

the right auricle, and once in the wall of the left auricle. The specimen which Dr. Herrick presented illustrates the frequency with which an individual suffering from syphilitic disease of the heart may die suddenly. Mracek says that out of sixty-three cases twenty-one died suddenly without previous symptoms, while if those cases were also counted in which there were some symptoms of cardiac weakness the cases of sudden death amount to 50 per cent. Such figures emphasize the gravity of this disease and the desirability of our being able to diagnosticate it during life; and yet, unfortunately, this is a disease in which the diagnosis is of the greatest difficulty and is to be arrived at oftentimes by exclusion and the history rather than from physical signs or symptoms. However, if the clinical experience of such an eminent man as Semmola counts for anything, it would seem that one of the very earliest symptoms which should direct our attention to the possibility of this disease is irregularity of tht heart's action. This irregularity may be manifested for a considerable time, may appear even during the secondary manifestations of the disease.

So far as symptomatology is of aid in diagnosis, we can only say it is that of heart disease in general. Before coming over to this meeting I stepped into the syphilitic wards of the Cook County Hospital and looked over some half a dozen male cases there. The first man I examined, one with tertiary lesions, has an enlarged area of cardiac dulness. The relative dulness extends an inch and a half to the right of the right sternal border, and four inches to the left of the left sternal border, a total transverse distance of more than six inches. The heart was rapid; the first sound a little valvular. It would be absurd for a physician to claim that this patient, although suffering with syphilitic disease in the third stage, has cardiac syphilis.

Another man, who gives a history of having had syphilitic infection twenty-four years ago, stated that last summer he suffered with irregularity of the heart's action and shortness of breath, but as he is five feet three inches in height and weighs 189 pounds, has great abdominal corpulence, one would meet with considerable difficulty, it seems to me, in saying that his symptoms are due to syphilis of the heart. Another man, a fireman, stated that last summer while at

work he suffered greatly from shortness of breath. Since coming into the ward and being put on antisyphilitic treatment his shortness of breath is much less. The transverse area of cardiac dulness is six and one-quarter inches; the first sound is feeble and when the man is in a recumbent position it is almost absent; the second sound in the aortic area is accentuated; the heart's action is quite rapid, over 100. Would anybody dare say that that man has cardiac syphilis? Would anybody dare say that the diagnosis points to cardiac syphilis because the man has been put on appropriate treatment and his symptoms have been relieved, when rest from work alone would explain his improvement?

This illustrates the difficulties we encounter in making a diagnosis and the extreme caution we should exercise. Nevertheless, it seems to me not unreasonable to assume that very many of these patients have cardiac disease of one kind or another, perhaps a very much larger percentage of them than we assume or have any means of determining, for the changes in the heart do not involve any one particular structure of that organ, but all of them. The development of the disease in the heart is so insidious and the symptoms are so latent that the disease escapes our recognition through the importance and prominence of other symptoms and the fact that the patients complain of nothing with reference to the heart.

The relative frequency with which the various structures of the heart are involved interested me very much in reading Mracek's article; he states that out of 61 cases 10 showed myocarditis gummosa, 9 myocarditis fibrosa, 8 gummosa et fibrosa, 15 myocarditis with endocarditis or pericarditis, 2 endocarditis alone, 1 pericarditis alone, 1 endocarditis with pericarditis, 1 pericarditis and endarteritis, 3 disease of blood vessels, 4 diseases of the ganglia and 6 of all the parts.

The prognosis is exceedingly grave because of the fact that a considerable percentage of these cases die without previous symptoms and because of the difficulty of recognizing the disease during life; the physician, as well as the patient, is thrown off his guard and allows the cardiac disease to run its course without special treatment. It is a well known fact that any treatment addressed to this form of cardiac disease is useless unless it be appropriate and specific; that is, ordinary cardiac

tonics, and so forth, are utterly useless in the absence of specific treatment.

Dr. JOSEPH M. PATTON—I am glad to hear it admitted that the obliquy of failing to apply the pathologic lessons, such as have been given us tonight, to clinical medicine, does not rest upon the internalist alone. There are several reasons why we should not be able to apply these lessons to clinical work. In those cases of cardiac syphilis where there are fibrous changes in the muscle or septum, or where gummata of the heart are developing, the symptomatology would be similar to that pertaining to any other affection of the heart muscle wherein the dynamic integrity of the muscle was directly affected. Again, in those cases where the changes due to syphilis are limited to the vessels of supply, the symptoms are identical with those pertaining to stenosis of the cardiac vessels from obliterating inflammation of any variety.

I would emphasize a point brought out by Dr. Herrick to the effect that it is unfair to accredit to certain lines of therapy curative powers for syphilitic cardiac changes. The fact is that all cases of chronic cardiopathies do quite well under the same medication as would be used in suspected cases of cardiac syphilis.

Dr. LUDVIG HEKTOEN—You have seen the beautiful specimen of so called pneumonia alba in congenital syphilis. I present here a specimen of another form of congenital syphilis of the lung, namely, the gummatous form. You will see scattered throughout the lungs foci of a light grayish color. Under the microscope these foci are seen to be composed of areas of round cell infiltrations with focal necroses. Surrounding these areas are the characteristic desquamative changes of pneumonia alba, showing that the two forms of congenital syphilis of the lung may coalesce.

Dr. VAN HOOK made some very appropriate remarks concerning the difficulties of diagnosis between syphilis and true tumors. He stated that the microscope should be resorted to in order that the question may be definitely decided. I desire to go further and to emphasize the point that even the microscope can not always decide whether the growth is syphilitic or sarcomatous; that instances have come under my own observation in which I was unable to determine from the microscopic

appearance whether a given growth was syphilitic or sarcomatous, so much similarity may there be between the structures of these proliferations. In connection with this, attention may be called to the fact that there is great likelihood that many testicles are being removed for sarcoma and other diseases that are really syphilitic. I am not able to prove this assertion at this time by any concrete example, but I have seen specimens which lead me to suspect that such things may occur.

Finally, a remark with reference to congenital syphilis of the heart, namely, that such changes have a marked practical importance because children so affected may live for a time after they are born and present no external marks of syphilis whatsoever and die suddenly.

Dr. W. L. Baum—Dr. Hektoen called our attention to the removal of testicles for sarcomatous conditions which are really syphilitic. Until within a few months I had a case under antisyphilitic treatment which had done very well, but the patient upon removing to another city had his testicles taken out for tuberculosis.

A second case, a young man, had one of his testicles amputated for what was believed to be sarcoma, but which from the testimony of his family physician was undoubtedly syphilis of the testicles. Another physician in this case made a diagnosis of gumma of the testicle and had advised the patient to place himself upon antisyphilitic treatment.

As regards the heredity of syphilis in the third generation, it reminds me too much of the tendency we all have when attacked by gout to lay great stress on the way our grandfathers lived. I am inclined to think that a large percentage of the so-called cases of syphilis that occur in older individuals are cases of the disease acquired during infancy. When we consider that by far the larger percentage of cases of so-called hereditary syphilitic children die at birth, are born dead or die within three months after birth, it is also strange that we should see so many examples of hereditary syphilis where we find the eruption appears two months after birth with a clear history of acquired syphilis. In the majority of cases, if the attending physician examined his cases thoroughly, he would have no difficulty whatsoever in locating the primary lesion.

The cases of gumma of the heart are interesting from a pathologic point of view, but I doubt very much whether they will have any great clinical significance for the reason that a large per cent. of the cases have died suddenly at a period far remote not only from the date of the initial lesion, but far remote from the time when any active specific lesions were present; so that while the attention of the physician may be called to the fact that the patient has had syphilis, yet in these cases of sudden death it is practically worthless. Discussions upon such cases as reported point out another fact, that we should impress upon the mind of every physician who treats cases of syphilis, that the treatment means not simply the gathering of a fee from the unfortunate patient, as is too often done in large cities; the idea seems to prevail that there is a specific treatment for syphilis which is of value in every case, and which is simply routine, and no attention is paid to the fact that the patient can acquire other diseases during the time he is suffering from syphilis. No attention is paid to the fact that one individual will react violently to small doses of iodids or mercurials, while others with apparently the same conditions present require extraordinarily large doses of these remedies.

Dr. Emil Ries—I wish to say a few words concerning the case of Mr. Wells. The complication of hereditary syphilis with infection with streptococcus and staphylococcus is highly interesting. It is to be regretted that we do not know more about the history of the case and that no examination of the placenta could be made. It is possible that infection with the streptococcus and staphylococcus took place after premature rupture of the membrane. The membranes may have been ruptured two or three weeks or a month before the child was born, as such cases have been observed. A few weeks or even days may be sufficient for infection of the fetus with the germs mentioned. If the placenta had been obtained for examination we might have known something about its condition and the route of infection. I refer here to the white infarcts of the placenta which by some authors have been considered characteristic of syphilis, which they are not by any means, and which by others have been regarded as a product of inflammation, which is not so, at least not in every case. Such infarcts may undoubtedly

have a bearing upon infection, the infection following the paths of the circulatory system through the mother into the fetus. Such an infection may have taken place in this case, but we do not know whether there have been such infarcts. Beside, under confinement, within a few hours, infection of the fetus may have taken place if instruments had been used, or the vagina had been packed for hemorrhage or some such condition and such an infection may have spread rapidly after the death of the fetus. Examinations of fetuses of mothers with typhoid fever, which were made in Strassburg, and some of which I witnessed, showed how difficult it was to differentiate between intrauterine infection, infection during pregnancy or labor, and an infection after death. Fetuses of mothers infected with typhoid fever were found full of bacterium coli commune, and as there was no reason to suppose that during the life of the fetus the infection had gone so far, it had to be assumed that after death the germs had spread rapidly. Such might have been the case in the case reported where there was streptococcus and staphylococcus infection. Of course it is impossible that the streptococcus and staphylococcus could have produced abscesses after death. Wherever there were abscesses and accumulation of round cells, these conditions must have originated and then produced during life.

With regard to the cases of syphilis of the heart that were discussed to-night, they interested me very much because of another organ consisting of muscle tissue, the syphilis of which organ we know so little, and which is so near the usual gate of infection, the uterus. Cases of syphilis of the uterus have been described in literature, but most of these descriptions are of very doubtful character. Gumma of the uterus has been described in extremely few cases.

Mr. H. G. Wells—In regard to my statement of the impossibility of the infection in the case reported by me occurring after death, I will say that it was made because the lesions show a vital process to have taken place at the site of infection. For instance, in the abscess of the thymus shown under the microscope, the abscess is walled off with connective tissue, showing that the lesion must have occurred before death.

Dr. L. Hektoen presented specimens of: *1. Brain Tumors Hardened in Mueller's Fluid 95 Parts and Formalin 5 Parts.*

About a year ago I showed to this Society some gross and microscopic specimens of brains and cords hardened in a mixture of Mueller's fluid 95 parts and formalin 5 parts. Particular attention was then called to the great advantage of this method of hardening on account of, 1, rapidity (one to three weeks); 2, the desirable consistency produced; and 3, the plainness and distinctness of the markings of the cut surfaces, making the specimens very useful for museum and teaching purposes, at the same time the tissue is properly prepared for various kinds of staining procedures. Since then, this method has been adopted in the anatomic department of Rush College as well as elsewhere.

I now desire to present several specimens of brain tumors; these brains were hardened *in toto* in the above mixture, and then divided into transverse sections 1 cm. thick by means of this board, which you see presents a series of grooves 1 cm. apart in which the point of the knife is held as the brain hemisphere is divided from before backward. This board I first saw used in Henschen's laboratory in Upsala, and it is a useful contrivance. Brains divided in this way allow of accurate comparisons between corresponding parts in the two sides.

The above mentioned advantages of this method of hardening and of cutting are well illustrated in the specimens from these cases.

2. *Mixed-celled Sarcoma of the Pons and Left Crus.*—The hemispheres show no changes except dilated ventricles. The upper or dorsal half of the pons presents an enlargement which at the posterior end assumes the form of an oval prominence lifting up the roof of the fourth ventricle, projecting into this cavity and pressing upon the vermis of the cerebellum. This mass is a little more prominent upon the left side. It is quite firm and homogeneous. It is sharply differentiated from the rest of the pons, but its exact upper limit can not be outlined, it being lost in the substance of the left crus.

Microscopic examination shows the tumor to consist of small round and spindle-shaped cells between which are interspersed a few small multinucleated giant cells, all being imbedded in a granular matrix. The tumor is rather vascular, and the vessels and vascular spaces have thin walls. Hemorrhages are not present.

This specimen came from a 30 year old woman in the service of Dr. Davis in the Cook County Hospital. In July, 1896, she complained of headache, dizziness and blind spells. On October 7 she entered the hospital, and it was then observed that the reflexes were exaggerated; that there was ankle clonus, nystagmus and retinal hemorrhages. On November 23 an exploratory trephine opening was made over the left hemisphere, but careful exploration failed to reveal anything abnormal. She died rather suddenly on Dec. 15, 1896.

3. *Glioma of the Left Temporo-Sphenoidal and Occipital Lobes. Anatomical Diagnosis.*—Craniotomy, encephalocele, intracerebral tumor of the left temporo-sphenoidal lobe, optic nerve atrophy, diffuse nephritis and hypertrophy of the heart.

Extract from postmortem record: Circumference of the skull 59 cm. Over the left parietal region is an oval opening in the skull 10 cm. in antero posterior diameter and 6 cm. transversely. Through this opening protrudes a soft, round mass. Over this opening the pericranium is adherent to the dura, but the dura is not adherent to the pia. The protrusion corresponds to a hernia of the brain substance. The skull cap is thin; the antero-posterior diameter is 17½ cm., the transverse 14½ cm. The margins of the opening are beveled from within outward. The dura is tense, the convolutions flattened, the pia mater anemic, the brain firm. The total weight of the brain is 1860 gms.; of the left hemisphere 940 gms.; of the right 740 gms., and the cerebellum, pons and medulla together weigh 180 gms. The optic nerves are hard and white. The basal ganglia of the left side are prominent. The spinal cord is normal. After hardening the brain in the formalin, Mueller's fluid mixture, for two weeks, the hemispheres were divided into transverse, vertical sections each 2 cm. in thickness. In the left hemisphere was a large tumor that commenced in the apex of the temporo-sphenoidal lobe and extended backward in the brain substance for the distance of 10 cm., the transverse diameter being 8, the vertical 6 cms. This mass was infiltrating and intracerebral, except in the fissure of Sylvius, where it reached the surface of the convolutions and caused pressure upon and distortion of the convolutions of the island of Reil. The left lateral ventricle was much deformed by the pressure of the tumor, the posterior horn being greatly enlarged. The

tumor contained many large and small cystic cavities filled with a viscid fluid. The probable microscopic diagnosis is glioma.

In May, 1896, Dr. Van Hook operated upon this man under the diagnosis of tumor of the left hemisphere, but exploration failed to discover any growth. The diagnosis had been based upon failing vision, headache, difficulty in speaking and right sided paresis. He entered the service of Dr. Edwards in the Cook County Hospital, Oct. 2, 1896. At that time there was total blindness, slow and thick speech, choked disk and a diffuse tenderness over the top of the head. Shortly before death he was transferred to the surgical service of Dr. Davis, where he died on Dec. 27, 1896.

4. *Sarcoma of the Left Temporo-sphenoidal and Frontal Lobes Springing from the Dura.*—The patient, a man, age 50, came under the care of Dr. Butler in Cook County Hospital Dec. 29, 1896 and died Jan. 4, 1897. The exact onset of the present trouble could not be found out. The left eye was protruding, the left eyelid drooping. The right eye had normal vision, and reacted to light and accommodation. There was tenderness when the head was tapped on the left side. His gait was slow, the legs being spread wide apart. On January 3, shortly before death, the patient had a convulsion during which the head deviated to the right, and the muscles of right side being then most involved in the clonic contractions.

The postmortem shows the body poorly nourished, the left eye prominent, the dura tense. Along the under surface of the left frontal and temporo-sphenoidal lobes, the brain is firmly adherent to the floor of the skull so that removal is impossible without considerable laceration of the brain substance. The brain weighs 1710 grams. There is a large mass extending into the left frontal and temporo-sphenoidal lobes from below, the tumor springing from the dura mater, more particularly the part lining the apex of the left middle fossa. The tumor is about the size of a hen's egg. It is but very loosely connected with the brain substance and threatens to fall away from the brain. On the cut surface it is reddish gray in color and firm in consistence. Microscopic examination shows the tumor to be a small round and spindle-celled sarcoma with much fibrillar stroma and many large thin-walled blood vessels.

## Regular Monthly Meeting, February 8, 1897.

The President, Dr. James B. Herrick in the Chair.

Dr. Robert B. Preble, read a paper on

# RELATIVE INSUFFICIENCY OF THE PULMONARY VALVES.

I shall make no apologies for presenting to the Society the report of a case and a brief paper upon so rare a condition as insufficiency of the pulmonary valves and the rarer condition of relative insufficiency. If we would make accurate anatomical diagnoses of the commoner valvular affections, we must have some familiarity with the signs of the rare ones. I am confident that you will all agree that we should not content ourselves with the diagnosis, "heart disease," but should endeavor in all cases to make as detailed a diagnosis as possible.

Relative insufficiencies, that is, those due to enlargement of the orifices rather than to contraction of the cardiac valves, are now admitted by almost all clinicians. Those upon the two auriculo-ventricular orifices and the aortic orifices are well known and the recorded cases are very numerous.

The relative insufficiency of the pulmonary valves has received very little attention as yet, and the reported cases can be counted almost on the fingers of one hand. I believe, however, that when once the attention is directed to the subject, the cases will rap-

idly multiply, for many of the conditions which may in time cause a relative pulmonary insufficiency are common.

The literature of this subject may be dismissed very briefly. Cases have been reported by Stokes,[1] Kolisko,[2] Bristowe,[3] Coupland,[4] Litten,[5] Chauffard,[6] Gouget,[7] each one and supported by autopsy. Pawinski[8] in 1894 reported four cases, but only one went to autopsy some months after the diagnosis of relative insufficiency had been made, and no insufficiency of the pulmonary valves was found. Grawitz[9] reports one case unsupported by autopsy, so that his case is not above question. Chauffard's case seemed well established clinically, but at the autopsy the pulmonary valves were competent to the water test. Barie[10] in 1891 collected 58 cases of pulmonary insufficiency with 43 autopsies, and included in his list the cases of Stokes, Kolisko, Bristowe and Coupland. He evidently did not regard them as relative, for he questions the possibility of relative pulmonary insufficiency, although in a later article, 1895, he admits the possibility. The literature thus contains but six cases supported by autopsy.

Because of this very brief list we must infer much of the etiology and symptomatology by comparison with aortic and organic pulmonary insufficiency.

Because of the anatomic and functional similarity between the aortic and pulmonary valves, we are justified in the inference that conditions similar to those causing relative aortic insufficiency might cause relative pulmonary insufficiency if brought to bear upon the lesser circulation. The possible causes of relative aortic insufficiency are numerous, but they may be

conveniently classified in three groups: 1, those affecting the aorta, altering its structure so that it is dilated more easily, as in acute aortitis, arterio-sclerosis; 2, those increasing the peripheral resistance, as in nephritis; 3, those dilating the left ventricle, as myocarditis.

By transferring this grouping to the pulmonary valve, we have:

1. Arterio-sclerosis of the pulmonary artery is uncommon and rarely reaches a high degree. There is no reason why it might not cause relative insufficiency of the valves.

2. This group of causes, namely, those increasing the resistance to the circulation of the blood through the pulmonary artery, is most important and includes many different diseases. Gourand[11] in 1865 drew attention to the possibility of relative pulmonary insufficiency resulting from emphysema, chronic bronchitis and indurative pulmonary processes. Coupland's case was secondary to emphysema, Bristowe's to emphysema and obliterative pleurisy. Stokes does not specify in his report as to the primary condition, but states in relation to the question that he has seen marked dilatation of the pulmonary artery in cases of emphysema.

Gouget's and Chauffard's cases were secondary to a combined mitral lesion. It is well known that these lesions cause an increase in the resistance to the pulmonary circulation, and there is no reason why the increase may not so dilate the pulmonary artery as to render the valves incompetent. The four cases reported by Pawinski, and the one by Grawitz, were cases of mitral stenosis. From the clinical report we can not

but agree with Pawinski's diagnosis, but the autopsies are wanting.

Litten's case was very different. The pulmonary artery was plugged by an embolus, an echinococcus cyst. The vessel was dilated to such a degree that the valves became incompetent.

Other diseases which might belong in this group are obliterative pleurisy, obliterative pericarditis, kyphoscoliosis, mediastinitis, aortic aneurysms and other mediastinal tumors, and all conditions which sometimes give rise to pulmonary embolism.

To these we must add the cause found in the case to be reported. When for any reason the left ventricle fails to do its work, the blood may dam back into the lungs and reach such a tension as to cause relative insufficiency of the pulmonary valves. This adds a large number of diseases, all those which can cause an increase in the resistance in the systemic vessels.

3. The third and last group, those affecting the myocardium, could as well cause relative pulmonary insufficiency as it does other relative insufficiencies.

The physical signs of relative pulmonary insufficiency do not differ essentially from those of an organic insufficiency. There is a varying degree of cyanosis, but often far less than one might expect. Sometimes there is a visible systolic pulsation in the second left intercostal space, and this may be so marked as to suggest a thoracic aneurysm. Over this same area there is often a palpable thrill, systolic or diastolic, or both. On deep palpation below the ensiform we can sometimes make out a diastolic thrill in the right ventricle.

Percussion shows that the cardiac dulness is in-

creased to a varying degree to the right. The left borders of the heart are normal or nearly so, unless changed by some complicating condition. The dilated pulmonary artery often gives a retrosternal dulness extending to the left second intercostal space.

Auscultation shows a diastolic murmur loudest in the second left intercostal space, propagated down the sternum and outward toward the left clavicle and usually not audible over the auscultation point of the aorta. According to Bernhardt, the murmur is loudest during expiration. The murmur is quite similar to that heard in cases of aortic insufficiency, but is not propagated into the vessels of the neck. Its point of maximum intensity is not peculiar to it, for the murmur of aortic insufficiency is frequently loudest in the second left interspace. It is often accompanied by a systolic murmur, just as the diastolic murmur of aortic insufficiency is.

Friedreich in 1867 stated that there could be no doubt but that the same vascular phenomena occurred in the pulmonary circulation with insufficiency of the pulmonary semilunars, that occur in the systemic vessels in aortic insufficiency. These vessels, although removed from direct observation, still give rise to certain signs described by Gerhardt.[12] Gerhardt[13] found that a manometer connected with the nose gave a tracing of the pulsation of the pulmonary artery. The tracing taken from a case of pulmonary insufficiency differed very greatly from those taken in the normal individual and in cases of aortic insufficiency, being higher and steeper and resembling the pulse tracing of aortic insufficiency.

Although we can not apply the stethoscope directly

to the pulmonary artery, we still find traces of auscultatory phenomena similar to those of the peripheral vessels in aortic insufficiency. Gerhardt found in five cases of pulmonary insufficiency two dull tones audible over the entire chest and similar to those heard over the brachial artery in cases of aortic insufficiency. Similar tones are heard over the normal chest close to the heart, but not at a point so remote as the outer border of the right scapula. Wide diffusion of these tones is not, however, peculiar to pulmonary insufficiency, for they are found also in well-marked cases of mitral insufficiency, where they arise in the pulmonary vein, and in cases of aortic insufficiency, where they arise on the aorta.

Pulsation of the pulmonary capillaries occurs just as it does in the peripheral capillaries in aortic insufficiency. Systolic intensification of the vesicular murmur during slow and deep inspiration in the portion of the chest near the heart has been known for a long time, but this phenomenon, called by Gerhardt an "audible capillary pulse" over remote portions of the chest, occurs only with the pulmonary insufficiency, when the capillary pulse is derived from the pulmonary artery; with cases of mitral insufficiency, when the capillary pulse is due to a retrograde wave of blood through the pulmonary vein, and in cases of aortic insufficiency when it is exactly comparable to the capillary pulse in the systemic vessels.

The second pulmonary tone may be present or absent.

These, briefly, are the physical signs in cases of relative pulmonary insufficiency. We will find in addition the signs of the primary condition.

The following is a brief clinical and postmortem report of a case, seen in Dr. Herrick's ward of the County Hospital:

German laborer, 42 years old, single and with negative family and personal history, except for an attack of gonorrhea seven years ago. Never had rheumatism or any other illness. About two years ago ran four miles without special inconvenience, but the next day spat blood, and had palpitation of the heart for several days. About one year ago had an attack of weakness and shortness of breath. Present illness began some days ago with dyspnea, headache, vomiting, cough, precordial pain and edema of feet and legs.

Examination showed a well-nourished man, face flushed and slightly cyanotic, moderate dyspnea, edema; veins of the neck prominent, showing a negative pulsation, and at no time did they show the positive pulse characteristic of tricuspid insufficiency. Temperature normal. Pulse slow until just before death. Small amount of fluid in chest, later increasing to such an amount that the chest was aspirated, drawing off a pint and a half of serous fluid of specific gravity of 1009, and containing few red blood corpuscles. Chest and lungs otherwise negative.

Heart: Apex beat in sixth interspace in the anterior axillary line. Deep cardiac dulness to second rib above, and one and one-half inches to right of sternum and to the apex beat. Palpation showed over the apex a systolic and presystolic thrill. The pulse had the characteristics of the pulse of aortic insufficiency well marked; capillary pulse distinct. Auscultation at the apex showed systolic, diastolic and presystolic murmurs. At the base two diastolic murmurs resembling the murmur of aortic insufficiency, that is, soft, long drawn and blowing. One of these murmurs was transmitted downward from the aortic area toward the apex; the other downward along the sternum. The second pulmonary tone was wanting, as was also the second aortic.

The liver was enlarged from passive congestion.

The urine scanty, of high specific gravity, albumin with granular and hyaline casts.

The interpretation of the cardiac findings was not

entirely simple. The shape and size of the cardiac dulness indicated an enlargement of both ventricles. The character of the pulse and the diastolic murmur at the base satisfactorily demonstrated an aortic insufficiency, which accounted for the enlarged left ventricle.

The enlarged right ventricle was referred to a mitral lesion, either double or single. Relying mainly upon the presystolic thrill at the apex, the lesion was thought to be a combined mitral insufficiency and stenosis. Had there been only the presystolic murmur at the apex, it would have been interpreted as the presystolic murmur described by Flint in cases of aortic insufficiency. I have since learned that Schwalbe has found a presystolic thrill at the apex in a number of cases of aortic insufficiency without any accompanying mitral stenosis.

We had yet to account for the second diastolic murmur at the base, transmitted down the sternum, and for the absence of the second pulmonary tone, which, if there was a mitral lesion, should have been accentuated. Both of these could be easily explained by the supposition of a pulmonary insufficiency. This supposition was strengthened and confirmed when, after a few days' treatment, this murmur disappeared and the second pulmonary tone reappeared. The improvement was but temporary and the pulmonary tone was again replaced by a murmur.

The clinical diagnosis was aortic insufficiency, mitral stenosis and insufficiency, relative pulmonary insufficiency, parenchymatous nephritis, hydrothorax and passive congestion of liver.

After being in the ward a few weeks the patient

died, and an autopsy was held four days after death.

The heart unopened weighed 1040 grams. Walls of both ventricles thickened, left ventricle 2 centimeters, right ventricle 1 centimeter. Aortic semilunars thickened, not more than two-thirds the normal size and incompetent to the water test. Pulmonary valves unchanged in structure, but are incompetent to the water test. Mitral valves thickened at the base, many vegetations. Orifice admits six fingers. Myocardium soft and friable, with scar in the interventricular septum. Tricuspid negative. Aorta shows atheromatous plaques. Liver of passive congestion. Kidney of parenchymatous nephritis.

Postmortem diagnosis: Hypertrophy and dilatation of the heart; aortic, pulmonary and mitral insufficiency, fatty and congested liver, parenchymatous nephritis.

The autopsy showed first that there was no mitral stenosis, so that our inference of mitral stenosis from the presence of the presystolic thrill at the apex was not warranted.

It is much to be regretted that the pulmonary orifice was not measured. The normal, according to Rauhing, being 67 millimeters in the male, measured in fifteen cases, and 63 millimeters in the female, measured in sixteen cases. Peacock's figures vary from these, being 90 mm. in the male, measured in sixteen cases, and 88 mm. in the female, measured in thirteen cases.

The water test as applied to the pulmonary valves is much more reliable than when applied to the aortic valves, for there are no coronary arteries through which the water may escape, and the difference

between the blood pressure under which the valves close during life and the pressure of the water test is not so great as with the aortic valves.

From this case and the others so far reported, we must conclude that relative insufficiency of the pulmonary semilunar valves is possible, and inasmuch as the primary diseases which may cause this lesion are common, we are justified in believing that this condition is not so rare as so far supposed.

BIBLIOGRAPHY.

[1] Stokes: Diseases of the Heart and Aorta, Case xx.
[2] Kolisko: Zeitschrift d. K. K. Gesell. d. Aerzte zu Wien, 1859, xv
[3] Bristowe: Trans. Path. Soc. London.
[4] Coupland: Trans. Path. Soc. London, 1875, 26.
[5] Litten: Charité Annalen, 1878, ii, 182.
[6] Chauffard: Rev. gen. d. clin. et d. Therap., 1895, 2, 321.
[7] Gouget: Rev. d. med., 1895, xv, 768.
[8] Pawinski: Arch. klin. Med., 1894, 52.
[9] Grawitz: Zeitschrift klin. Med, 1893, 23.
[10] Barié: Arch. gen. d. med., 1891, 27 and 28.
[11] Gourand: Paris Thesis, 1865.
[12] Gerhardt: Congr. Intern. Med., xi.
[13] Gerhardt: Charité Annalen, 1892, 17, 255.
[14] Schwalbe: Virchow's Arch., 1890, 119: Deut. Arch. klin. Med., Volumes xliv and xlv.

Drs. M. L. HARRIS AND MAXIMILIAN HERZOG presented a paper on

SOLID MESENTERIC TUMORS, WITH A REPORT OF A CASE.

The new case reported is that of a boy 5 years old, who came under the treatment of one of the reporters (Dr. Harris) in April, 1896. A large tumor, easily palpable, was found to fill the greater portion of the abdominal cavity; its surface was smooth, though somewhat irregular, the entire mass was as movable as the closely fitting abdominal walls would permit. From the relation of the tumor to the abdominal organs, especially to the colon, and from other data, a clinical diagnosis of solid tumor of the mesentery was made and an operation performed on April 13, 1896. The tumor was found as expected; it appeared to have started in the mesentery; a loop of intestine (jejunum) passing over it was attached to it and had to be removed with it (about 51 cm. long). The ends of the divided intestine were united end to end by the operator's (Harris') method. The patient's condition when removed from the table was quite critical, but he rallied and made an uninterrupted recovery. Ten months after the operation he was in excellent health and without any signs of recurrence.

The tumor, the pathology of which was studied by one of the reporters of the case (Herzog), is egg-shaped in its general outlines, the periphery of its longest axis measuring 57 cm. Histologically the growth proved to be a lympho-sarcoma with extensive colloid degeneration. A remarkable histologic feature was the presence of colloid material found in the lumen of blood vessels. Sections of the growth had been embedded in celloidin as well as in paraffin, and had been stained with hematoxylon and eosin, orcein, and according to Van Gieson's methods.

DISCUSSION.

Dr. EMIL RIES—I wish to ask Dr. Herzog one or two questions. Were these specimens imbedded in celloidin?

Dr. HERZOG—Some.

Dr. RIES—Have sections been made from the fresh material?

Dr. HERZOG—No.

Dr. RIES—When I looked at the specimens just now, it struck me as remarkable that colloid masses formed in the arteries. The reason why I asked the question, whether sections were made from fresh material, was because I could not distinguish

in the microscopic specimen the colloid mass from the celloidin.

With regard to the observation of vacuoles in colloid masses, I wish to state that vacuoles can be found in celloidin. When the ether evaporates from the solution of celloidin unequally under different degrees of heat, the formation of vacuoles occurs. I do not doubt the presence of colloid masses in the cells and in other parts, but just this one mass in an artery is remarkable. I would like to ask Dr. Herzog how he thinks the mass got into an otherwise normal artery?

With regard to the case itself, I wish to add a few words concerning an observation of my own which belongs to this class of cases, although it is not a primary tumor of the mesentery. I observed a case of large sarcoma of the uterus, for which abdominal hysterectomy was made. Some thirteen tumors of various sizes were found in the mesentery besides the uterine tumor. Microscopic examination showed that it was a fibrosarcoma. In a few of the tumors of the mesentery remnants of mesenteric glands could be found, so that the glands could be recognized as the seat of the metastatic tumors. The patient made a good recovery, but returned about eight months after the operation with a recurrence from which she died. I understand the patient of Dr. Harris is still alive, and I wish to congratulate him on the result.

Dr. Maximilian Herzog—You may see exhibited under the microscope some specimens containing vessels, the middle coat of which shows signs of a homogeneous degeneration; you can not see any nuclei, nor are the fibers themselves distinct in their outlines. Concerning the histology of the tumor under discussion, I reported to you what I found; among other things, I found in some of the vessels a homogeneous material, exactly like the material found elsewhere in the tumor. I have called this material colloid because it answers, as far as I can see, in every detail to the description of colloid material. How this material was formed in the vessels or how it got there, I am not prepared to explain in detail today. That the masses in the vessels are not thrombi is evident.

Dr. Hektoen—I think some further microchemic tests ought to be made before we are justified in speaking of this material as colloid, that is, if we use the term as we apply it, for instance, to the material found in the thyroid and other epithelial struc-

tures. If we use the term colloid as meaning any homogeneous material, then there is colloid material in these arteries and elsewhere. I have observed such substances in the vessels of tissues hardened in Müller's fluid, and I have thought that such colloid-like material might be a pure artefact.

Dr. HERZOG—There is a good deal of controversy today as to the limitation of the term, "colloid." Virchow discards the term entirely, and calls certain materials, which others call colloid, "gallertig." Recklinghausen classes what others call colloid with "hyaline degeneration." Ziegler and others describe as colloid, a degeneration which seemed to me to answer to the degeneration which I found in the tumor of the mesentery exhibited here tonight.

### FOCAL OR INSULAR NECROSES PRODUCED BY THE BACILLUS OF TUBERCULOSIS.

Dr. E. R. LECOUNT read a paper with above title, of which the following is an abstract.

Focal necroses have been observed in consequence of various causes and in various organs. The substances abrin and ricin the former from the jequirity bean, the latter from the castor bean, the toxins produced by the diphtheria bacillus, the micrococcus lanceolatus, the typhoid bacillus or its toxins and the bacillus malleus, all may cause necroses as their initial lesions. They have also been observed in consequence of the injection of the blood serum of dogs into rabbits and in puerperal eclampsia.

These necroses occur mainly in the spleen, lymph glands and liver, but also in the intestinal epithelium, the peritoneum and in other viscera. Most instances of focal necroses as produced by the substances mentioned, are caused by the action of some harmful material circulating in the body fluids; less frequently they are caused by bacteria acting *in loco*.

These lesions are as a rule minute and frequently only to be found in the course of a routine microscopic examination. They are characterized by a degeneration of the fixed cells of the organ or tissue in which they occur and then affect as a rule mainly the essential cells. In some instances simply loss of staining capacities (karyolysis), is found to form the only change in the nuclei of the cells, in other instances karyorhexis frag-

mentation of the nucleus results, and again these are frequently found associated in the same area of necrosis.

With these changes in the nuclei, fibrin is frequently formed as the result, in part at least, of exudation (coagulation necrosis). In certain instances the necrotic area is invaded by polymorphonuclear leucocytes as in the so-called lymphoid nodules seen in the liver in typhoid fever.

Nuclear fragmentation results in the accumulation of numerous ball-like granules of chromatin which stain intensely with nuclear dyes. Necroses of this variety have been observed by R. Kockel in experimental tuberculosis of guinea-pigs, but the areas observed by this author in the liver were ascribed by him to ischemia. Pilliet also described necroses in the liver in tuberculosis in animals, but did not believe them to be due in any respect to the direct action of the bacillus of tuberculosis. Leredde in an article upon acute and subacute human tuberculosis, has depicted visceral necroses which have apparently resulted from venous hyperemia, which resulted from interference with the pulmonic circulation.

*Case 1.*—A case of chronic ulcerative tuberculosis of the lungs, showed in the spleen and liver, areas visible only with the microscope which corresponded in all respects histologically, to other forms of focal necrosis observed in diphtheria, abrin poisoning, etc. They were on an average, the size of a normal glomerulus in the kidney of an adult, and were made up of necrotic cells, nuclear fragments and fibrin and in them the bacillus of tuberculosis was invariably present in small numbers. No leucocytic invasion had occurred into the area, no giant cells were present, no other bacteria could be demonstrated nor were any changes present in the adjacent small arterioles or capillaries, such as thrombosis. Consequently these areas differed histologically from tubercles.

*Case 2.*—A case of chronic peritoneal tuberculosis in which exactly similar areas were found in the spleen. In the liver, however, typical microscopic tubercles were present.

*Case 3.*—A case of tuberculosis of the retroperitoneal lymph glands which anatomically simulated the enlarged lymph glands seen in lymphatic leukemia. No caseation was visible to the naked eye, but microscopically irregular confluent areas of necrosis were found present, mainly affecting the peripheral

parts of the gland and these also contained the tubercle bacilli. From the resemblance of the areas of focal necrosis in these three cases to all other described instances of focal necrosis and the fact that they contained within them the bacillus of tuberculosis and no other bacteria, it was concluded that the action of the bacillus of tuberculosis upon the tissues is not such as to invariably produce that combination of proliferative and exudative changes which is called a tubercle. The absence of proliferative changes which are by most authorities accepted as phenomena of tissue resistance or reaction was in direct accord with the marasmus present in all three cases.

DISCUSSION.

PROFESSOR KLEBS—These necrotic processes in cases of tuberculosis are interesting, and I am quite familiar with them in guinea pigs. Necrotic areas occur in the liver and form cirrhosis of the liver. I have not seen these necrotic processes so frequently in man. I remember to have seen cases in which there were necrotic areas in the spinal cord, the brain and the kidneys. I have almost always found that necrotic processes in tuberculosis were not caused primarily by the toxins of tuberculosis, but by obstruction of the vessels. There is a great difference between the toxins of tubercle bacilli and those of other diseases. Large necrotic areas are observed in bacterial processes. These necrotic processes develop in the kidney sometimes in a comparatively short time, and we have an enormous quantity of the toxins thrown out by the diphtheria bacilli, the cholera vibrio, etc. The most extensive toxic necrosis I have described in the kidneys of Asiatic cholera. As to the distribution of the toxins in bacteria, there are very great differences. In typhoid bacilli there are considerable quantities of toxic substance contained in the bodies of the microbes, but not so in tuberculosis.

I have done considerable work toward finding out the composition of the tubercle bacilli and I have tried to prepare toxins from their bodies but I have not had any results. All the toxins are in storage in the fluid culture; there they are to be considered as secretion products. The quantity of the toxins in the bodies of the tubercle bacilli is not quite a fourth of that in the whole culture formed by four to five grains of dry tubercle bacilli in five

or six weeks. So the quantity of toxin formed in a few tubercle bacilli must be very small. From this cause I do not think they are formed in such quantity that the necrosis is produced directly by them in the same way as it is in diphtheria or cholera. I have always held the opinion that necrosis in tuberculosis was formed by obstruction of vessels. Wherever tubercle bacilli are deposited, there we first observe obstruction of vessels, also in dissemination of the tubercle bacilli in the blood, particularly in cases of miliary tuberculosis. It is shown by Roux and Yersin and myself that by injecting living tubercle bacilli in the blood, the greatest part of them is killed in the blood. Otherwise obstruction of vessels is an important factor in the formation of necrotic masses. I would remark also that this necrosis, if I understood Dr. Le Count rightly, is found mostly in the spleen, and, secondly, in the liver. Those are the organs in which obstruction of vessels is of frequent occurrence. In the spleen we have very extensive capillary circulation, the blood current is slow, and obstruction likely to occur. In tuberculosis of the spleen wedge-shaped, yellow infiltrations occur as well as in the liver of guinea pigs. I have frequently found in tuberculosis of the kidneys, occurring in older persons, very small atrophic spots on the surface of the organ, which were perhaps the consequence of necrotic processes. I have seen similar atrophies in the brain and spinal cord.

I think the fibrinous matter that is found in the necrotic parts points toward obstruction of the vessel. It is not necessary that this obstruction should be caused by thrombi. It may be due to stasis in the vessels as it is found in the diphtheritic mucous membranes. We can have obstruction of the vessels by other substances than thrombi; as if the vessels are enormously dilated and filled up with red blood corpuscles compressed against one another, or there are formed thrombi of blood plates—after the injection of Koch's tuberculin. The presence of the fibrinous matter in the necrotic parts would favor the opinion of obstruction in the vessels.

Dr. Le Count—The idea that these areas of necrosis might be due to obstruction to the circulation was not neglected; a careful search was made for thrombotic processes in the vessels and at the same time the relation the areas bore to the vessels was thoroughly examined by means of serial sections. Any

reasons for ascribing the necrosis to interference with the circulation could not be found; nor were thrombosed capillaries found. The additional facts that tubercle bacilli were invariably present in the areas of necrosis, that these lesions were present in cases of well marked cachexia and that in the spleen they were diffusely scattered throughout, not located near the capsule as areas of ischemic necrosis are liable to do, seem to support the position taken.

We likewise can not overlook the researches of Abtl, who injected tubercle bacilli into the trachea of rabbits and found twenty-fours later small whitish isolated areas in the bronchi and lung alveoli which proved microscopically to be areas of necrosis, in which proliferative changes occurred two days later. Concerning the action of toxins which Professor Klebs refers to, there is a marked difference between the lesions at present described in the literature as "focal necrosis" and the changes produced in the kidney either by diptheria or cholera toxins, in that the latter do not occur in foci, indeed the necroses produced in diphtheria and described under the term focal do not include those which are found in the kidney.

In conclusion I wish to state that it is my firm belief that the bacillus of tuberculosis in exceptional instances can produce necrosis as a primary effect upon the tissues, as seems to be demonstrated in these specimens, but that in the majority of instances the effect as Baumgarten has stated is to cause primarily proliferative and exudative phenomena.

SPECIMENS.

Dr. E. R. LeCount—I have here two specimens which were removed today from the same body. They are not without interest and also show well on account of their fresh condition. The first is a *calculus* imbedded in the substance of the kidney. As you can see, it is L shaped, half as large as the little finger, and lies apparently in a dilated calyx.

The second is a *mesentery* for the gall bladder, forming a pendulous gall bladder. The "mesentery" measures one inch in breadth at its widest portion and gradually narrows as the cystic duct is approached. One and one-half inches of the cystic duct are also suspended in the "mesentery." There is entire absence of the furrow for the gall bladder, so that the lobus quadratus is directly continuous on the right side

with the right lobe of the liver. There is also absence of the notch which occasionally forms the termination of the groove for the gall bladder. Both of these specimens came from the body of an old man who died of empyema and purulent bronchitis.

Dr. JAMES B. HERRICK—I present a specimen of *aneurysm* of the right auricular appendix. I am indebted to Dr. Hektoen for the privilege of exhibiting it. There is nothing known of the clinical history, the heart having been obtained by the coroner's physician.

The pericardium shows no change. The heart is rather large in size and shows left and right ventricular hypertrophy. The coronaries are sclerotic. The valves of the heart show slight thickening, but nothing can be proven to have resulted in a clinical valvular lesion. The aorta shows some calcareous plaques. The point of interest is that at the tip of the right auricular appendix there is a sac-like projection, the long diameter of which is about 2 cm. and the walls of which are perfectly translucent, and which is wholly made up of endocardium and epicardium. We have, therefore, an aneurysm of the right auricle. A similar one, though smaller, is found in the left auricle. There is no evidence of inflammation of the pericardium, endocardium or auricular myocardium. We can scarcely look upon this as an aneurysm the result of myocarditis, which is the common cause of aneurysm. It would rather seem to be due to a separation of the muscular fibers in the auricle, either through congenital or acquired weakness, and a hernial protrusion of the endocardium. It can readily be seen that this point of weakness is also a point of danger, and that a rupture of such a hernia of the endocardium would be followed by the most serious consequence in the shape of hemorrhage. The auricle itself is comparatively rarely the seat of an aneurysm; the commonest place being the left ventricle, particularly near the apex; the septum, particularly near the membranous portion; the right ventricle, and lastly the auricle.

Dr. KARL F. M. SANDBERG—This specimen of *extra-uterine pregnancy* was removed this morning from a woman who has had three children and one abortion. She menstruated the last time on November 12. On December 29 she had a spas-

modic pain in the lower part of the pelvis, and during January of this year she had a repetition of the same pain three or four times. There was an irregular loss of blood through the vagina at different times. She consulted her family phpsician, Dr. A. B. Oyen, who promptly made the diagnosis and referred the case to me. The specimen shows a pregnancy in the distal two thirds of the right tube with the ovary located posteriorly, the fimbriated extremity of the tube attached to the same. The specimen was removed entire without having been ruptured or opened. It was located in the cul-de-sac of Douglas and universally adherent with the exception of about one square inch of the top part. The lowset portion is apparently the softest part, the easiest to rupture, and in this case a rupture would not have occurred into the broad ligament, but into the peritoneal cavity, remaining separated from the general peritoneal cavity by the adhesions. The pregnancy after rupture would very likely have gone on, the adhesions gradually moving up higher and higher, and the fetus developing in the cul-de-sac of Douglas, gradually pressing higher up, and in this way the woman might have had a good chance of going to full term. I will pass the specimen around without opening it.

## Regular Monthly Meeting, March 8, 1897.

The President, Dr. James B. Herrick in the Chair.

Prof. Edwin Klebs read a paper on "Some Remarks on Malignant Growths" (*vide* p. 220).

### ICTERIC NECROSIS AND NATURAL INJECTION OF THE INTRA-CELLULAR PASSAGES IN THE LIVER.

Dr. Gustav Fütterer—The case from which these specimens were obtained was one of primary carcinoma of the gall bladder. The illustrations which I pass around show carcinoma of the wall of the gall bladder growing into the liver substance and along the hepatic duct, and causing obstruction of the hepatic duct. It was a glandular carcinoma, and the first photograph shows this very nicely. The next illustration shows how carcinoma begins and grows into the liver substance. The obstruction of the bile duct caused a dilatation of all the bile ducts inside of the liver. When I came upon the bile ducts and opened them, they were filled with absolutely clear mucus. Their walls were thickened. A microscopic examination revealed necrosis around some of the gall ducts, which was due to pressure by the dilated duct. This pressure necrosis was only found in comparatively small spots. Inside of the acini icteric coloring was observed in every one of them, occupying a central zone around the central vein, increasing more and more the nearer it got to the central vein. All through the liver, the central vein was surrounded by an inner row of preserved liver cells, which leads me to conclude that the lymphatics have carried off the main part of the lymph. A more minute examination of the cells inside of the icteric necrotic portions showed the following: Surrounding the necrotic portions a great number of small, contorted, greenish masses were found inside of the cells, masses which were formed like corkscrews when they were rather small, but which

became more and more straightened out as they grew larger. They were mostly found around the nuclei as concentric rings. It was seen that bile had been retained inside of the liver cells, and normal bile channels inside of the liver cells could thus be seen. How did this come about? The current of bile must have been reversed. For some reason or other, the bile has not entered the interlobular gall ducts. Whether the pressure of the mucus that filled the gall ducts prevented the bile from running in that direction, or whether it was caused by obstructions between capillaries and ducts, I am unable to say; the fact remains that the current has been reversed to the center, for there we find the icteric necrosis. The peripheral portions and the cells of the intermediate zone got rid of their bile almost as fast as it was produced, while the central portion was continually overloaded. Thus the cells in the central portion were not able to get rid of their bile, and in our microscopic specimens, which were well preserved in formalin, thickening of the bile had taken place, inside of intracellular channels. I exhibit a photograph showing a high degree of destruction of the liver cells which progresses to complete dissolution. I show a drawing which points out the connection between the extracellular and intracellular bile channels. If you will look closely at the drawing, you will see that one of the intracellular branches dives down under a nucleus and comes out again on the other side. I show you photographs of small channels that are contorted. Some of the photographs show how the cells become actually destroyed and the network dissolved. In one photograph we have a perfect network. Of course, we can not expect a clear, perfect picture, as the loops occupy different planes, and you would have to photograph a number of sections to get a proper view of the whole network of a certain cell. But if you will look at the photographs with a magnifying glass you will be able to see these channels very plainly. You probably know that experiments have been made by numerous investigators, who have succeeded in driving the fluids which are used for injection of the bile ducts into the cells, but it has always been a question whether these were artefacts or not. Here we have a natural injection of the intracellular channels with bile, which tends to prove that those who made artificial injections of the bile

duct system have succeeded in driving the liquids used into the intracellular roots of the whole system.

My conclusions would be: A stenosis of the hepatic duct has caused stagnation of bile inside of the gall ducts, this causing a dilatation of the ducts, a thickening of their walls, and patches of necrosis of liver cells. The bile contained in the ducts was gradually replaced by mucus produced by the glands of the ducts. About two-thirds of the volume of the liver substance was apparently unchanged and the liver produced large quantities of bile, which, however, were not excreted by way of the gall ducts, probably because the thickening of the walls of the gall ducts caused obstruction of the entering capillaries. The reason why I would prefer to accept this explanation is because I find no dilatation of bile capillaries in the peripheral zones of the acini. Not only has the bile been prevented from running in the normal direction, but its current has been reversed and it has entered mainly the perivascular lymphatics which surround the central vein, but also to some extent the latter. Further, the constant overloading of the central zone of the acini with bile, prevented the cells of these portions from expelling the bile produced by themselves, thus enabling me to study the intracellular bile channels and even have them photographed with oil immersion. The study of those channels shows that they are very small, contorted, that they surround the nuclei as rings or approach them in radial directions, that they form networks in the protoplasm of the cells, also around the nuclei, and that they communicate with intercellular ducts. These channels lose their contorted appearance as they become dilated more and more, and as they grow larger, the substance of the cell and the nucleus degenerate, until at last nothing but detritus tells of their former existence.

DISCUSSION.

Prof. Edwin Klebs—I have been very much interested in Dr. Fütterer's demonstration. The question is, What is it that fills up these canals? Can it be only bile? I think not. As bile is fluid and stains the liver cells diffusely in icterus, can it not be that hyaline masses, formed in the liver cell, are the cause of obstruction of these intracellular canals? Impregnated with bile, this suggestion seems to explain much more clearly the dilatation of the canals, than by fluid masses. A

very similar process may be seen in phosphorus intoxication. There the intercellular canals are filled up with such hyaline masses (O. Wyss and Alter). New researches will show possibly also intracellular canals.

Dr. LUDVIG HEKTOEN—In addition to the artificial and natural injection of intracellular passages, there is another way of demonstrating them, namely, by means of Golgi's stain. I show you here the plates illustrating Erik Mueller's beautiful work on "Intracellular and Intercellular Passages." This plate represents the intracellular passages as revealed by Golgi's method in the liver.

THE FATE OF GIANT CELLS IN HEALING TUBERCULOUS TISSUE.

Dr. LUDVIG HEKTOEN presented a number of microscopic specimens from a case of healing tuberculous leptomeningitis and made the following remarks concerning the changes in the giant cells: The investigations into the nature and the importance of the giant cells of tuberculous tissue have not led to uniform results. Baumgarten, Weigert and others look upon them as necrobiotic from the inception. Metchnikoff and his school regard them as active, living, defensive cells. The mode of formation, the sources, the relation to bacilli, the degenerative changes of giant cells have all been studied, but the further definitive changes that occur when the bacilli are removed or their action neutralized before the giant cells become necrotic have received but very scant attention. Are the giant cells left capable of progressive changes, do they continue to exist as giant cells, or are they removed by way of disintegration? Manifestly a definite answer to some of these questions would throw some light upon the nature of the giant cells. D. J. Hamilton remarks that sometimes giant cells live on and organize, *i. e.*, secrete or form fibrous tissue. The numerous investigations into the healing of tuberculous peritonitis make no reference to the part played by the giant cells. The most extended statement occurs in the work of Professor Klebs on "Die Causale Behandlung der Tuberculose"; he states that giant cells in healing tuberculous tissue in guinea pigs subdivide into uninuclear cells and become part and parcel of the living tissue, more particularly of the endothelial lining of vascular channels and spaces.

In an unusually long case of tuberculous leptomeningitis in

a 35-year-old man, the symptoms, consisting of headache, optic neuritis, occasional vomiting, extended over four months, death resulting from a pneumococcus pneumonia—the post-mortem showed a chronic tuberculous basal leptomeningitis, tuberculosis of the peribronchial lymph glands, chronic nephritis and lobar pneumonia. At the base of the brain there was much turbid fluid and a thick layer of firm translucent material containing pin-head sized and large nodules. In the exudate, tubercle bacilli were demonstrated by means of culture. Microscopic examination of the leptomeninx showed a chronic fibrous endarteritis, and the production of much loosely fibrillated young connective tissue with larger and smaller fibroblasts, young blood vessels and very many multinucleated giant cells. The giant cells—as seen in the specimens exhibited—present various changes in various degrees. There are giant cells that seem to be dividing, but this division is accompanied with much nuclear disintegration, vacuolation of the protoplasm, and phagocytosis; there are also some karyokinetic figures in single nuclei in the giant cells from the disintegrating cells. There are also giant cells that seem to be dividing into smaller cells without nuclear disintegration, but the fate of the smaller cells could not be made out; they did not appear to form new blood-vessels. The following reasons allow this case to be regarded as a chronic, healing tuberculous meningitis: 1, the process has reached the same stage throughout the whole area involved; 2, there is but very little caseation; 3, there is present a chronic endarteritis; 4, acute inflammatory changes are absent; 5, the presence of a fibrillated, vascular, embryonal tissue; 6, the changes in the giant cells. The fact that tubercle bacilli grew from the fluid inoculated on glycerin agar show that the cells in the pia were, so to speak, immune to their action; while the mechanism of this immunity need not be discussed, it is plain that the cells survived the action of the bacilli and retained vitality enough to form new tissue. There is a large number of giant cells, many of which are splitting up and show progressive changes side by side with retrogressive; the nuclei in the giant cells present my independent foci of activity; they are independent centers. Whatever the mode of origin of the giant cells may have been—whether by fusion, mitosis or amitotic division of the nucleus

without division of the protoplasm, the mode can not have been incompatible with viable descendants.

*Conclusions.*—In healing, non-degenerated tuberculous tissue the multinucleated giant cells may in part disintegrate and become absorbed, in part form small cells; both these changes usually affect the same cells, but in one class—presumably the older and weaker—the retrogressive changes predominate, while in a second—presumably the stronger and younger—the progressive changes are the more marked. The fact that giant cells in tuberculous tissue under some conditions undergo progressive changes and separate into small, living cells proves that they are not, as claimed by Baumgarten and others, necrobiotic elements that are predestined to destruction; it lends more strength to the teleologic view of Metchnikoff that they are living cells, defensive, formed for a distinct purpose.

DISCUSSION.

Prof. EDWIN KLEBS—In a case of tuberculosis of the testicle I was very much surprised to find a great number of giant cells lying very close to each other. In places there were fresh tubercles, round cells, with a few tubercle bacilli, so that we can say that the process in this case showed the same feature of healing as in the case just described by Dr. Hektoen. In tuberculosis of the testes the giant cells as a rule contain no tubercle bacilli, but it was very curious that the greatest number of them, in my case, were found in connection with striated muscular fibers. Some of the cells surrounded the muscular fibers. Others could be seen in long rows along the muscular fibers. In some of the cells which were near the muscular tissue I observed small crest-like masses included in the giant cells. That the clear centers of the tuberculous giant cells are not necrotic, seems to be evident in those cells that originate from vascular tissue.

I am not inclined to accept the theory of Metchnikoff, that the giant cells are organs of destruction of microbes or of red blood corpuscles (Langhans) or of bone (the osteoclasts of Kölliker). This suggestion would seem acceptible if the giant cells had the force of contraction. But the many projections of their substance are absolutely immovable, as I have often observed in living giant cells of different origin. The same has been proven by the persistence of the rigid projections in the

dead cells, whereas, the ameboid projections of leucocytes are retracted in death. Giant cells are not necrotic for they are continually developing fresh nuclei. I have seen such giant cells in cases of carcinoma in which we observe the production of new nuclei in successive generations. The same feature must characterize the formation of giant cells in healing tuberculous tissue. They are formed under every circumstance from the endothelial cells of the tissues under the influence of regenerative processes. That they contain in tuberculosis sometimes tubercle bacilli has no other signification than the inclusion of foreign bodies or tissue constituents.

The positive demonstration by Dr. Hektoen that they finally return to the normal tissue cells, or split up in their first constituents, is in conformity with my own observations ("Causal Treatment of Tuberculosis," 1894), and seems to me to be of the highest importance and shows clearly that they are in a living condition. If one might express a theory as to their formation, one could say that the hardened character of the protoplasm of giant cells constitutes a favorable condition for the new cell development in the struggle against destructive microbes or foreign bodies, or dead material of the body itself.

DIFFUSE SCLERODERMA ASSOCIATED WITH CHRONIC FIBROUS CHANGES IN THE THYROID AND GREAT DIMINUTION IN THE AMOUNT OF THYROIDIN; INCREASE IN THE CHROMOPHILE CELLS AND OF THE COLLOID IN THE HYPOPHYSIS.

Dr. LUDVIG HEKTOEN—Through the courtesy of Dr. Noel an opportunity was given to study the organs of a case of diffuse scleroderma in a woman 51 years old. The clinical history, for which I am indebted to Dr. H. E. Brennecke, shows that the disease had lasted about one year and that it had pursued a typical course and rapidly become almost universal in its distribution. The patient died after having been unconscious for three days.

The anatomic diagnosis reads as follows, the postmortem having been made immediately after death: Diffuse scleroderma, atrophy of the thyroid, arterio-sclerosis, fatty and atrophic liver, chronic nephritis, interstitial myocarditis and hypertrophy of the heart, gummas (?) of the liver, chronic caseous tuberculosis of the retroperitoneal glands, edema of

the lower extremities, adhesive pleuritis and pelvic peritonitis. The skin over the face, neck, chest, abdomen and parts of the extremities as well as of the back is hard and tight, smooth and without any wrinkles; it seems thin, but cuts with resistance. The thyroid is small and fibrous, weighing 14 grams, the isthmus is absent. The condition of the other organs is sufficiently well set forth in the anatomic diagnosis. The microscopic examination showed the brain and spinal cord to be quite normal. The areas in the liver that were thought to be gummatous are found to be aberrant or obstructed bile ducts. The thyroid is the seat of extensive fibrous changes with atrophy and destruction of the glandular portion, resulting in the formation of larger and smaller cysts, in which is inspissated colloid material. Normal follicles with normal lining and normal colloid contents are very rare. The arteries in the thyroid are the seat of a general and greatly advanced obliterative thickening. The hypophysis weighs .7 gram; it is consequently very large; the number of chromophile cells and the colloid material are increased, as can be seen in the sections under the microscope. The changes in the skin may be summarized as follows: There is a great hyperplasia of the collagenous intercellular substance in the corium with flattening of the papillary body, together with a breaking up and spreading asunder of the elastic fibers, obliterative thickening of the blood vessels, atrophy of the interpapillary epithelium as well as of the epidermis, the hair follicles and the coil glands. These changes are diffuse, practically universal, although not always of the same degree. The appearances were studied in sections prepared according to Benecke's, Unna's and other methods for demonstrating collagen and elastin.

The chemic examination of the thyroid was made by Mr. H. G. Wells and the following is his report:

"The thyroid gland in this case when fresh weighed 14 grams. This is very much below the normal weight, for sixty glands from persons between 25 and 65 averaged in weight 22 grams, over one-half more than did this gland. When dried, allowing for the portion removed for microscopic purposes, it weighed 3.23 grams, the average dry weight of twenty normal glands from the same series being 5.37 grams. This dried gland was

analyzed to determine the amount of iodin it contained, using the colorimetric method advocated by Baumann in his original work on the iodin contents of the thyroid gland. The analysis was made in duplicate, both determinations agreeing closely, and it was found that in each gram of the gland was contained 0.91 mgr. of iodin, giving a total amount of 2.94 mgr. as the contents of the entire gland. Analysis of a series of twenty normal glands from residents of Chicago has given as the average amount of iodin in each gram of the dry gland 2.01 mgr. The average total contents of iodin in these cases was 10.79 mgr. Therefore in this gland the proportion of iodin was less than half the normal and the total quantity of iodin between one-fourth and one-third that usually contained in a normal gland. It is also far below that of any normal glands in the series quoted, for the smallest amount found there was 7.46 mgr. and in that case the amount of iodin in each gram was 1.98 mgr. From this it is evident that not only was the gland quantitatively atrophic but probably also functionally, for as a general rule, the smaller a normal gland the larger the proportion of iodin it contains, so bringing the total iodin contents up to a certain standard, which in this vicinity appears to be about 10 mgr, whereas in this case despite the small size of the gland, the proportion of iodin was much below that one would expect to find in a gland of much greater size. The hypophysis would seem to be correspondingly enlarged, for in a series of twenty-one glands the fresh weight was found to be but 0.4 gram, while in this case the weight was 0.7 gram. In the series mentioned but one gland was found of so high a weight and this was probably not a normal gland, for it contained an unusual number of cyanophile cells which greatly outnumbered the chief cells. It is probable that the iodin in the hypophysis is contained in the colloid material, just as Hutchinson has shown it to be in the thyroid. Analysis of fourteen normal hypophyses gave as the average amount of iodin in each gland 0.0036 mgr., which represents for each gram of dried hypophysis 0.04 mgr. This is but about one-fiftieth as large a proportion of iodin as is found in the thyroid gland, and corresponds to the relatively trifling amounts of colloid that the hypophysis contains. Unfortunately, the hypophysis from this case could not be examined chemically, as it was used for microscopic

purposes, but it is probable that because of the increased amount of colloid it contained that a comparatively large amount of iodin would have been found."

We have in this case the cutaneous changes characteristic of scleroderma associated with fibrous changes, atrophy and diminution of iodin in the thyroid and increase in the chromophile cells and colloid in the hypophysis. These changes in the hypophysis were found quite frequently by Schönemann in connection with goiter, and their exact nature, whether degenerate or compensatory and hypertrophic, can not be stated, because the writers are not in entire accord as to the significance of the chromophile cells, *i.e.*, cells with an eosinophile or cyanophile cystoplasm.

The causes of diffuse and other forms of scleroderma are not known. The neuropathic theory of Schurminer remains to this day without any anatomic substratum. The chief objection to Dinkler's view, that the obliterative arteritis is the primary lesion in the process, is that it is difficult to understand how the arteritis can lead to such a degree of collagenous hyperplasia. Singer found the thyroid the seat of chronic fibrous changes in a case of scleroderma, and urges strongly the view that this disease as well as myxedema and exophthalmic goiter are due to dysthyreosis; but this present case is the first one in which an actual diminution of the active constituent of the gland has been demonstrated. Pisko, Marsh, Steglitz and Grünfeld obtained good results with thyroid treatment in various forms of scleroderma, and Marsh and Grünfeld saw in the sudden improvement something more than a mere coincidence. On the other hand, Franke, Unna and others have had negative results. In connection with this the relation of the thyroid to myxedema becomes significant. The changes in the skin in myxedema vary, but it seems established that the elastic tissue is increased and the collagenous tissue diminished. Now, if arthyreosis can produce such changes there can be no inherent reason why disthyreosis, due to various causes, may not lead to scleroderma. In this case it lies temptingly near to assume that the endarteritis of the thyroidal vessels may have been the essential cause of the changes in the thyroid, and in accordance with the suggestions already made, indirectly of the scleroderma. Arterio-sclerosis might,

it would seem, lead to parenchymatous atrophy and fibrous growth in the thyroid as well as in other organs. Viewed from this point the arterio-sclerosis would seem to play an indirect but essential part in the genesis of the diffuse scleroderma of the old rather than the direct rôle advocated by Dinkler and others. The causes that may disturb the functions of the thyroid and the results thereof are various, and it seems warranted to suggest that the relations of arterio-sclerosis, dysthyreosis and scleroderma merit further study.

ACTINOMYCES-LIKE BODIES IN THE TONSILS.

Dr. J. W. Ellis—While studying a series of tonsils in the pathologic laboratory of Rush College my attention was called to an article which appeared in the *Zeitschrift für klinische Medicin*, Vol. 30, parts 5 and 6, which in substance is as follows: "In the histologic examination of twenty-five tonsils from patients suffering from various diseases, as tuberculosis, syphilis, sepsis, chlorosis, broncho-pneumonia, acute tonsillitis, etc., he found in four cases from Gerhardt's clinic bodies which resembled actinomyces."

The diseases from which these patients suffered bore no relation to the tonsils. The ages of the patients varied from 7 to 22 years.

These bodies to the naked eye were small yellowish specks. The microscope revealed the fact that there were only a few in a section—never more than six—and that they were invariably found in the crypts of the tonsil. They stain with the ordinary hemotoxylon stain, and are round or oval and from .5 to 1 mm. in diameter. The center had the appearance of a tangled mass, while the periphery had a more or less clubbed appearance. By Gram's method the body was seen to be made up for the most part of longer or shorter threads, and distributed throughout the mass were seen cocci-like particles, which also retained the stain. The tangled mass of threads in the center under the highest power was seen to be composed of more or less curved staves, which were seen to be continuous, but did not stain at the point between the staves. Toward the periphery the threads radiated, branched and stained more evenly, while the outer threads were stained throughout.

On counter-staining with a body stain the whole mass appeared to be bedded in a homogeneous mass with brighter spots.

The bodies did not stain by Günther's modification of Gram's method. In the vicinity of the bodies there was more or less round cell infiltration, but he did not think it was due to the presence of the bodies, as the tonsil from the opposite side showed the same round-cell infiltration, but he did not find the bodies. He concludes from their frequency—four cases in twenty-five and their not producing any change in the adjacent tissue—that they do not have any pathologic significance. He classified them among the ray fungi, and according to Tarni they are a form of actinomyces and are to be differentiated or distinguished from the actinomyces Horninis by not staining with Günther's modification of Gram's method. I have placed some sections of an apparently healthy tonsil which contains some bodies that answer the above description under the microscope for your inspection.

## Regular Monthly Meeting, April 12, 1897.

The President, Dr. James B. Herrick in the Chair.

Dr. M. L. Harris, read a paper on

# A CASE OF BENIGN CICATRICIAL STRICTURE OF THE ILEUM.

### OPERATION, LATERAL ANASTOMOSIS, EXHIBITION OF SPECIMEN REMOVED FIVE YEARS AFTER.

The patient from whom this specimen was obtained presented the following history: Mr. C., age 57, American, married. Family history good. His health previous to the present trouble had been good. I could obtain no history of a former intestinal trouble such as dysentery, severe diarrhea, typhoid fever or any illness likely to have been attended by the formation of an ulcer or ulcers in the intestinal tract. He could date his present trouble back about three years. It began very gradually with symptoms of indigestion or dyspepsia, and for a long time was supposed to be due to his drinking habit, as he was a man who indulged rather freely in intoxicants. The symptoms, however, continued to increase in severity, unrelieved by medication. The bowels became constipated, with periodic attacks of diarrhea. His appetite failed and he wasted greatly in strength and flesh.

When seen by me Dec. 10, 1891, he was in an extremely miserable condition. He had wasted to a mere skeleton, weighing but 85 pounds. He was

unable to retain nourishment, as he vomited everything put into the stomach. The ejecta were very offensive and semi-fecal in odor. Nothing had passed the bowels for several days.

An examination of the abdomen showed it to be somewhat distended. Large coils of small intestine were distinctly outlined through the abdominal wall and the peristaltic contraction was plainly visible. During these peristaltic waves, which were intermittent, the patient would experience severe griping pains. I have never seen coils of intestine so distinctly outlined and the peristaltic wave so plainly visible as in this case. Upon palpation an indistinct sense of resistance could be felt deep in the lower part of the abdomen, a little to the right of the mid-line. With the finger in the rectum this was more distinct, yet a tumor could nowhere be defined. The urine was normal except for the presence of a large amount of indican.

A diagnosis of chronic intestinal obstruction was easily made. Its location in the lower portion of the small intestine seemed likewise quite clear. Whether malignant or benign, however, was not so easily determined. His age and great emaciation spoke for malignancy. The length of time, fully three years, during which distinct symptoms had been present, the rarity of carcinoma in the small intestine and the absence of a tumor in an emaciated abdomen easily palpable, spoke more in favor of a benign stricture.

With this in view I determined to operate at once and form an anastomosis around the obstruction. The operation was performed Dec. 11, 1891. Upon opening the abdomen, the seat of obstruction was fortu-

nately quickly reached and the loop drawn out. A linear mass of cicatricial tissue about 1.5 cm. in width, apparently involving most of the thickness of the gut wall, encircled the intestine, and by its contraction had almost completely obliterated the lumen of the canal. It did not extend at all on to the mesentery, which was perfectly free. It was evidently a simple, benign cicatricial stricture, and was located in the lower part of the ileum. The intestine below the stricture was very small, flat and empty, while above it was remarkably dilated, looking like a distended colon, its wall, from hypertrophy, being as thick as that of the stomach. A lateral anastomosis was made between the loop above and the one below the stricture, about 30 cm. being excluded from the intestinal current. Senn's large size decalcified bone plates were used in the operation. The recovery from the operation was rapid and without incident. He regained his health at once and made the most remarkable gain in weight, from 85 to 190 pounds in eleven months.

He continued in good health for about four years, when the effects of chronic renal and cardiac disease, aggravated or perhaps superinduced by his habits, began to show themselves, and from this time on the usual course of these diseases was passed through—general anasarca, ascites with repeated tappings, etc., and finally death in December, 1896, exactly five years after the operation. At no time was there any trouble with his intestinal tract after the operation. The specimen still shows the thick cicatricial mass forming the stricture and allowing but a small probe to pass.

The loop of intestine which was excluded has shrunken or atrophied to but a few cm. in length. The anastomotic opening is of good size, having contracted but little, and permits a free unobstructed passage of the intestinal contents. The great dilatation of the bowel above the stricture has all disappeared, the gut being now of uniform size. This is, so far as I am aware, the oldest specimen—five years—of a lateral anastomosis on record.

The cause of the stricture was in all probability cicatricial contraction following an intestinal ulcer, but the history of the patient gave no clue to the primary trouble, and no examination of the body or intestines was permitted after death.

DR. H. A. BRENNECKE read a paper on

## THE STREPTOCOCCUS PYOGENES THE CAUSE OF DIPHTHERITIC CONJUNCTIVITIS IN A CASE OF MEASLES.

The following case is thought to merit a somewhat complete report because it was diagnosed clinically as true diphtheria of the conjunctiva, by Dr. Cassius Wescott on the strength of the macroscopic appearance of the eye, whereas the microscopic examination demonstrated the absence of the diphtheria bacilli and the presence of the streptococcus pyogenes in short chains, not only in the eye but in the blood and various organs.

The case occurred in a boy three years old. The patient had been living at "The Home of the Friendless" from which a number of patients with measles had been brought to the Cook Country Hospital into

the service of Dr. W. L. Baum. The patient had been sick three days before admission, complaining of sore throat, headache, slight coryza and had vomited once.

On examination the body was found well nourished, eyes with slight conjunctival injection, the expression was dull and there was photophobia, lachrymation and serous discharge from the nose. The pharynx was injected, tongue coated, tonsils enlarged, as also the cervical glands. The heart's action was accelerated. The lungs revealed numerous dry râles. The abdomen showed nothing of interest. Skin: On the face there were numerous crescentic, round and irregular "blotches" of a red papulo-macular variety, which became diffused over the entire body on the second day.

During the course of the diesase the following observations were made: On the day of admission the pulse was 124, temperature 102.4, respiration 36; after this they varied as follows: pulse 130–160, temperature 101–105, respiration 40–48 up to the last day, when the pulse was 172, temperature 102.3, respiration 56–64.

On the fifth day an examination of the urine showed the presence of albumin and hyalin and epithelial casts. The conjunctiva of the right eye was markedly injected, particularly that of the palpebræ. The following day the injection was more intense, the lower lid much swollen and on eversion showed a heavy white exudate. On the eighth day both lids were edematous and their conjunctivæ covered with a heavy white membrane. The bulbar conjunctiva was injected and the cornea smooth and shiny. The discharge from the eye was abundant and milky. The left eye was unchanged.

At about the same time that the changes in the eye were noted, superficial ulceration about the alæ of the nose appeared, which gradually extended and caused an occlusion of one of the nares.

As the condition in the eye had been diagnosed a true diphtheria of the conjunctiva, repeated cultures were made on blood serum from the nose, eye and throat, but only micrococci, staining with Gram's method, were found, which grew in fine white translucent and yellow circular colonies. Direct cover-slip preparations made from the eye showed only micrococci.

On the tenth day the following note was made: Patient restless, often refuses nourishment, pulse rapid but of fair quality, respiration rapid, skin rough and dry and the back and shoulders as well as other parts of the body show diffuse irregular patches of red which do not disappear entirely on pressure. The nose is but little changed. The mucous membrane of the mouth shows irregular white patches. The eye is the same with the exception of a hazy cornea. Examination of the lungs reveals numerous subcrepitant and mucous râles diffusely spread, most marked over the lower lobes. A large area of dulness with increased voice sounds is found over the right lower lobe.

Death took place eleven days after admission. The postmortem examination was made twelve hours after death. Only the essentials are given here. The body was well nourished. The heart showed no changes except paleness. The trachea was ecchymotic. Both lungs contained numerous areas of consolidation of grayish red color and which reached a considerable

size in the right lower lobe. The lung tissue around the smaller bronchi was infiltrated with blood. By pressure a muco-purulent fluid was forced from the bronchi. The spleen was firm, enlarged and mottled on section. The kidneys showed fetal lobulation, the capsules peeled readily leaving a smooth surface, on section they were pale and the cortical markings were distinct. The mesenteric, cervical and peri-bronchial lymph glands were enlarged. The tissues about those of the neck were edematous. The right eye showed the lids swollon, their conjunctivæ covered with a dirty gray membrane and the cornea hazy. Cover-slip preparations made from the blood and stained by Gram's method showed streptococci.

The bacteriologic examinations was made with the aid of Dr. Geo. H. Weaver. Innoculations were made on blood serum from the following organs: the blood of the heart, the lungs, the cellular tissue and glands of the neck, the spleen, the kidneys, the right eyeball and the liver. The blood, spleen, kidneys and liver showed a pure culture of fine, white, circular, translucent flat-topped colonies. Cover-slip preparations made from each stained with Gram's and showed streptococci. The organism appeared in similar growths on 5 per cent. glycerin agar. Stab cultures in gelatin produced a fine globular growth along the puncture which became confluent and did not liquify the gelatin. Litmus milk was changed to a slight reddish color and was not coagulated. Bouillon showed a fine gray sediment leaving the medium above clear. Potato showed no visible growth in four days. The cultures grew more rapidly at the temperature of the thermostat; 5 c.c. of a bouillon culture two days

old injected into a vein of the ear of a full-grown rabbit did not cause death. From the above peculiarities it was concluded to be the streptococcus pyogenes.

From the eye, lungs, glands and cellular tissues of the neck a second micrococcus with following characteristics was obtained. On blood serum, 5 per cent. glycerin agar and potato the colonies were heavy, circular and light yellow in color. Gelatin was liquified, made turbid and of foul odor. Bouillon was likewise rendered turbish and foul. It grew best at room temperature; 2 c.c. of a bouillon culture injected into the peritoneum of a rabbit produced no marked symptoms. It was concluded to be a saprophytic micrococcus.

Histologic examination of the various organs showed the following: In the right eye the cornea shows the epithelium destroyed, round cell infiltration into its tissues and there is also infiltration into the anterior chamber, sclera, ciliary body and optic nerve. On the outer surface of the sclera and cornea there is a layer of granular homogeneous material which in part takes the hematoxylon stain and shows extensive nuclear fragmentation and fibrin, evidently a superficial necrosis. The lung shows the changes of broncho-pneumonia. The spleen and the glands of the neck show an increase of cellular tissue. The heart, liver and pancreas show no changes.

Sections of the various tissues stained by Gram's method show streptococci in the vessels.

*Summary.*—The bacteriologic examination showed the presence of the streptococcus pyogenes in the right eye as well as the body generally. On account of the simultaneous ulcerative condition in and about

the nose it can not be positively stated that the eye formed the atrium for general infection. On the other hand it is quite probable that the eye became involved by the streptococcus being brought there by the circulating blood. The primary atrium for infection may have been in the throat.

Dr. Emil Ries read a paper on

## PRIMARY PAPILLOMA AND PRIMARY CARCINOMA OF THE FALLOPIAN TUBE.

The two cases which I present here were operated on by Dr. T. J. Watkins, who kindly offered them to me for pathologic examination. They are of great clinical as well as pathologic interest, one case indeed being unique in its kind. Only six cases of primary papilloma of the tube are contained in the literature, the present being the seventh case. Of primary carcinoma of the tube the tables of Doran[1] and of Saenger[2] contain nineteen cases, the present being the twentieth.

I. Primary papilloma of the tube. Secondary papilloma of both ovaries. Repeated vaginal drainage for purulent salpingitis, at last salpingo-oöphorectomy by laparotomy. Recovery. Good health fifteen months after the operation.

*Clinical history.*—Patient, 34 years old, gives a history of inflammatory disease of the pelvic organs after a miscarriage in her twenty-ninth year, from which she recovered perfectly. In her thirtieth year she suffered some violent injury to her left inguinal region. This was followed by "inflammation of the ovary," which remained painful until operation.

The diagnosis was pyosalpinx and in June, 1894, the swelling in the pelvis was opened through the vagina. The tumor evacuated a quantity of pus. In November, 1894, the tumor had to be opened again and patient wore a drainage tube for eight months. In August, 1895, third operation. Patient wore the drainage tube for two months after she left the hospital. At last in January, 1896, laparotomy was performed and the appendages were removed. The patient recovered uneventfully. She was seen a few days ago by Dr. Watkins and was found to be in perfect health. She does not menstruate and has no leucorrhea. The uterus is atrophied and freely movable.

*Macroscopic description of specimens.*—Left side: Ovary not enlarged (35 x 26 x 20 mm.). Its surface is covered in several places by wart-like excrescences, which in some places sit on the ovary with a broad base, while in others they are distinctly pedunculated. The tube is normal externally with the exception of a slight thickening of its isthmic part. The fimbriated end is open. Cross sections through the tube show nothing abnormal. The ovary contains on sections small cysts, most of which have smooth walls, while some contain small papillary growths. (Fig. 1.)

Right side: Ovary not enlarged (40 x 25 x 30 mm.). The portion of the tube removed is 6 cm. long; the fimbriæ are not visible; the abdominal end is dilated, while the uterine end is of normal size. A part of the surface of the ovary is covered with wart-like excrescences, a few of which are also found on the surface of the tube. An opening in the ovary, which was probably made in the course of the treatment,

leads into a small cavity the size of a hazel-nut, which is invested with an abscess-membrane and contains some pus. This cavity also contains numerous papillomatous growths. The dilated tube, which contains a small quantity of hemorrhagic fluid, communicates with the cavity in the ovary through a narrow opening, toward which the folds of the tube converge and which represents the abdominal orifice of the tube. The cavity of the tube is studded with papillomatous growths, which extend throughout the external half of the tube. (Fig. 2.)

Both ovaries and tubes are covered with many adhesion-membranes, but there are no papillomas in or on these membranes.

*Microscopic structure.*—The microscopic structure of the papillomas is alike in ovaries and tube. One layer of long slender columnar epithelium covers the connective-tissue framework of the papillæ, which arise from the mucous membrane and branch out into more and more delicate ramifications. The papillæ of both ovaries and tubes contain numerous small gritty bodies with concentric striation, calcareous concretions, which are almost normal in all sorts of papillomatous growths.

The wall of the tube with papillomas is thin and shows a few small areas of round-cell infiltration. Toward the mucous membrane there are a few cyst-like epithelial formations, which are even found outside the circular muscular layer. These cysts, however, do not contain papillomatous masses nor solid epithelial growths. They are lined by one single layer of low columnar epithelium. The cysts are round or roundish, sometimes with slight constric-

tions. I have not been able to discover an endothelial lining around them, but will not lay much stress on this fact, as the state of preservation of the specimen was very bad when I examined it.

The uterine end of each tube contains adenomyomatous structures. These are more pronounced and extensive on the side of the papillomatous tube than in the healthy tube. The papilloma has not affected the adenomyoma, the epithelium of which is more or less columnar with well-pronounced ciliæ, while the epithelium of the papilloma presents no ciliæ. There is no communication to be found between the adenomyomatous tubules and the tubal cavity.

The little cysts of the left ovary which do not contain papillomas are lined with a simple low cuboidal epithelium and look like simple hydropic follicles. No corpus luteum cysts are found. The little cysts which contain papilloma prove to be of a different structure. They are invested with a columnar epithelium, which is in direct continuity with the epithelium of the papillomas filling the cysts. In several places the communication of the cysts with the surface can be observed consisting in a narrow cleft lined with the same epithelium as the papilloma itself. It appears unlikely that the growth started in the substance of the ovary. I believe rather that it penetrated from the surface as the development of the neoplasm on the surface is much more extensive and much more pronounced.

*Review.*—We are now confronted with the question whether the tumor originated in the tube or in the ovary. The same question arose in one of the six cases of papilloma of the tube contained in the liter-

ature. This case was observed by Doran,[1 3] who designates it as a case of papilloma of the tube. Where ovary and tube present papilloma the primary seat of the tumor must be assumed to be in the tube if the ovary has as in our case remained small in size, as our experience leads us to believe that ovarian papillomas belong among the most rapidly growing tumors of the ovary. This reason makes it at least likely that the papilloma in our case originated in the tube and spread on to the ovaries. This event was facilitated by the therapeutic efforts which gave the papilloma of the tubal cavity the opportunity of reaching the surface of the pelvic organs. The absence of ascites in this case also tends to exclude the ovaries as primary seat of the tumor, as ovarian papilloma is almost invariably accompanied by ascites.

The history of inflammatory symptoms is usual in cases of papilloma, so that Doran,[1] and Saenger and Barth[2] attribute direct etiologic importance to the inflammation. The papilloma of the tube was one-sided in five out of the six cases published and was so in our case. Four of the reported cases survived the removal of the tumor and are reported well three, four, four and sixteen years after the operations. To this I can add the present case, which Dr. Watkins saw a few days ago in perfect health, that is to say, fifteen months after the operation.

II. Primary carcinoma of both Fallopian tubes. Adenomyoma of both Fallopian tubes. Myofibroma of the body of the uterus. Numerous metastases of the carcinoma. Abdominal salpingo-oöphorohysterectomy. Speedy recurrence and death.

*Clinical history.*—Patient, 45 years old, has always

enjoyed good health; had one child twenty-three years ago; no miscarriages. She came to the hospital on account of difficult urination and pain in the pelvis. These symptoms had begun about ten days before patient entered the hospital. The operation was performed on Sept. 1, 1896. Uterus, tubes and ovaries were removed; the operation was made difficult by numerous and strong adhesions. Patient recovered and was discharged on October 6. She returned to the hospital on Dec. 13, 1896, with a large tumor extending from Douglas' pouch to the umbilicus. An effort to remove this proved the tumor to consist of a soft mass resembling granulation tissue, which could not be entirely removed. Discharged from the hospital Jan. 3, 1897, died a few weeks later.

*Microscopic description.*—(See Fig. 3.) Uterus 88 mm. long in all, the removed part of the cervix 12 mm. long. Wall of the fundus 10 mm. thick. Middle of anterior wall 26 mm. thick. Posterior wall contains a fibroid with well marked capsule. Posterior wall 88 mm. thick, 16 mm. being the thickness of the uterine muscular tissue, the rest fibroid.

The fibroid (F. Fig. 3) is submucous covered by a very thin layer of mucous membrane. The latter is thin throughout the cavity with the exception of one flat elevation (E. Fig. 3) on the left anterior side of the cavity. The fibroid presents the usual arrangement of bundles and resembles in shape a ball compressed in the longitudinal diameter of the uterus. The uterine cavity (C C Fig. 3) is narrow, cleft-like; measured over the fibroid it is 84 mm. long. Right and left broad ligaments are easily recognizable. Each uterine horn is formed by a nodule (N. Fig. 3),

which has 15 mm. antero-posterior diameter on the left and 17 mm. diameter on the right side. An incision into the right nodule shows three small cavities filled with colloid masses. Nothing similar on left side. On the left half of the fundus are two subserous nodules the size of lentils, slightly lobated; a larger one (17 x 10 x 5 mm.) is found on the posterior surface which presents numerous and firm masses of adhesions. A nodule of the same size as the last mentioned is situated on the fundus close behind the nodule of the left uterine horn.

The length of the right tube measured along its upper border is 260 mm., its largest circumference 180 mm. Just outside the nodule on the uterine horn the tube becomes narrower, then it swells considerably and presents four large convolutions. The anterior side of the tube is with the exception of some adhesion-membranes smooth; the posterior side presents on the lateral four-fifths of its length more or less bulky papillomatous growths. The abdominal end of the tube, which has the large circumference mentioned above, is sharply bent to below and behind so that it touches the isthmic part. The ovary (40 x 30 x 15 mm.) is located between the abdominal and uterine portion of the tube. There is almost no trace of an ovarian ligament, the ovary being almost contiguous with the uterus. The ovary presents a few adhesion-membranes, but no papillomatous masses. On a cross section several corpora lutea and follicles are seen. The cavity of the tube (RT. Fig. 3) contains flat and prominent papillomatous masses, which fill the narrow isthmic part completely while they cause only a thickening of the wall of the abdominal

end. The tube is so tortuous that on cross sections of the isthmic part the cavity appears double. The wall of the adominal end is one to three mm. thick, the wall of the isthmic part is double this size. Near the broad ligament the tubal wall of the isthmic portion forms a white mass 5 mm. thick and is covered outside by a stratum of papillomatous masses about 4 mm. thick. Several thick masses of adhesions connect the abdominal portion of the tube with a tumor mass (40 x 40 x 5 mm.) (RM. Fig. 3). On cross section this mass consists of a white substance which contains a central cavity. The cavity presents several wart-like excrescences.

The left tube, measured along its external border, is 315 mm. long, the largest circumference (165 mm.) being at the abdominal end. Distinct furrows divide the tube outwardly into four convolutions. Near the first furrow, counting from the uterus, the anterior surface of the tube presents a tortuous elevation (L M. Fig. 3) about 30 mm. long and one to two mm. thick, a cross section of which contains a white mass. The anterior and posterior surfaces of the tube are covered with pseudo-membranes. The ovary of this side (LO. Fig. 3) has an ovarian ligament 22 mm. long. The ovary (54x20x18 mm.) contains numerous corpora candicantia and follicles. Cross sections through the nodule on the isthmic part present a thick wall and a cleft-like cavity. Further on the wall of the tube is a pretty homogeneous white mass. It is stained brownish near the cavity. The cavity itself is filled with a blood clot which reaches from the isthmus to the abdominal end. If the blood clot is lifted away from the wall low papillomatous masses are seen

everywhere. The wall of the abdominal portion is two mm. thick, near the uterus the wall is five to seven mm. thick.

The abdominal ends of both tubes are closed. The right tube contained sero-purulent fluid which escaped during the operation, as the tube burst.

*Microscopic description; right tube.*—The wall of the tube does not show any remarkable changes, with the exception of some round-cell infiltration along capillary vessels. The mucous membrane presents a multitude of smaller and larger papillary elevations. The elevations consist in the largest part of epithelial masses, while the connective tissue skeleton of the papillæ is scarce, and frequently so crowded with round cells that very few connective tissue cells are visible. The epithelial masses form labyrinthian coils winding in and out, often so close together that no connective tissue whatever remains between them. The epithelium is arranged in single or multiple layers, mostly in the latter. The individual cells are columnar epithelial cells, some very long and thin, some shorter, almost cuboidal. The larger papillæ contain blood vessels. Small hemorrhagic areas occur in many of the papillæ. The surface is covered with many detached and degenerated cells and cell detritus.

The arrangement of the epithelial cells is not always distinctly papillary. In many places sections contain apparently glandular or cystic formations which, however, are only produced by the knife cutting away recesses between papillæ. The epithelium does not grow downward into the wall of this tube.

The peritoneal coat of this tube shows no patho-

logic changes in the macroscopically normal portion of the serosa.

*Left tube.*—The mucous membrane of the narrower part presents the same appearance as the right tube, the papillary growths and the inextricable coils of epithelial formations existing here in the same manner as on the right side. The cavity contains considerable detritus consisting of white blood corpuscles, detached and degenerated epithelial cells and more or less distinct red blood corpuscles. The epithelium does not penetrate the mucous membrane in this part of the tube. The muscular coat contains a few areas of round-cell infiltration of no large extent. In the place mentioned in the macroscopic description where the tortuous elevation resembling a dilated vessel is seen on the tube, the peritoneal surface presents a very striking appearance (see Fig. 4). Between the external muscular layer and the surface there is an accumulation of solid epithelial masses divided by smaller or larger strings of connective tissue which form a network, the meshes of which are filled by the tumor cells. The tumor cells are many-shaped, mostly roundish with large nuclei (some presenting unmistakable karyokinetic figures), others are very large cells with one large nucleus, while still others are real giant cells. The epithelial cells form rounded masses, or appear as rosary-shaped strings with more or less pronounced constrictions. The large epithelial masses are in some places arranged in strings along and around capillaries which have preserved their endothelium. The latter is seen as a single line of flattened cells dividing the blood corpuscles from the tumor cells. In other places the endothelial lining

has disappeared, so that the blood space, as it is to be called then, is limited by the tumor cells themselves. Smaller epithelial masses, sometimes containing one or several vacuoles, do not contain blood vessels. They are separated from the surrounding connective tissue by a line of flat endothelial cells; in other places this endothelium is rather cuboidal or even gives rise to small epithelioid buds. Taking all this together, I conclude that these tumor masses are located in lymph spaces, especially those sheathing blood vessels. The importance of this observation with regard to the dissemination of carcinoma by the lymph and blood currents is evident.

A section of this left tube, comprising the insertion of the isthmic part on the broad ligament, shows the papillo-carcinomatous condition of the tube very much like the right tube; hemorrhages, however, being more numerous and covering larger areas than in the other tube. The explanation of these hemorrhages may be found in an obstruction of the venous current, indicated in the sections by the many vessels choked with red blood corpuscles. The peritoneal surface shows some solid carcinomatous nodules resembling those described above, but on a smaller scale. The parovarian tubules in the broad ligament are very distinct. They are without any pathologic change. The wall of this part of the tube contains carcinomatous nests in several places. These nests show the path which the carcinoma has followed from the mucosa to the serous coat. The nests are either solid or they have still preserved the papillomatous or coiled arrangement peculiar to the primary growth of the mucosa. Some of these nests are distinctly located in lymph

vessels, as is demonstrated by the layer of endothelial cells which is still visible in some places, while in other places there is no such lining of the carcinomatous nests, which are imbedded in the tissue itself.

*The nodular enlargements* of the isthmic part of the right and left tubes present an extremely interesting combination of neoplasms (see Fig. 5), which is described here for the first time, and has not been mentioned in any other case of carcinoma of the tube. The enlargement of the tube here is not caused by a dilatation of the tubal cavity but by a thickening of the tubal wall. This thickened portion contains a normal tubal cavity, a slit of stellated or more or less straight shape with the cuboidal or low columnar epithelium normally found in this part of the tube. Around the mucous membrane there is the normal circular muscular layer. Between the latter and the serous surface the cause of the thickening is found. The wall of the tube contains: First, the elements of an adenomyoma, and secondly, papillo-carcinomatous masses. The adenomyoma presents the usual appearance as first described by von Recklinghausen.[4] There are epithelial tubes, straight or curved or ramified, surrounded by more or less cytogenic tissue and a well-pronounced muscular coat. I need not further dwell on this adenomyoma as I have disscussed it fully in a paper on "Nodular Forms of Tubal Disease."[5] I must add that in each of these nodules a process of the mucous membrane of the tube was seen penetrating the circular muscular coat of the tube so that here as well as in the cases described in my paper mentioned above, it was hard to decide whether the epithelium of the adenomyoma had originated in

Mueller's or in Wolff's duct. Beside this adenomyoma the thickened wall contained beautiful papillo-carcinomatous growths, which in some places were simply papillomatous while in others they were more or less solid nests. In several instances the little cavities which contained the neoplasm were partly lined with a single layer of low columnar epithelium while the rest was lined with multiple epithelial layers or was the seat of papillary growths. This leads me to the conclusion that some at least of the carcinomatous nests developed in cavities primarily belonging to the adenomyoma, supplanting or as it has been called, "infecting," the original epithelium. Under the serous coat there are numerous solid carcinomatous nests filling lymphatics. Some of these nests are so large that they form carcinomatous nodules visible with the naked eye. The small cavities mentioned in the macroscopic description are partly simple cysts of adenomyoma partly filled with papillomatous masses.

*Uterus.*—On the left side I followed up the extension of the neoplasm into the body of the uterus and found that solid and papillomatous masses were spread a short distance into the muscular coat of the uterus, but did not penetrate deeply into it. Along the serous coat, however, the neoplasm had spread extensively, so that small subserous fibroids of the posterior wall and fundus of the uterus as well as the adhesion membranes on the uterus everywhere contained carcinomatous masses. The fact that the progress of the malignant neoplasm largely took place along the subserous lymphatics is also proven by the observations made on the body of the uterus, the round liga-

ment, the myoma contained in the uterus and on the endometrium. The endometrium presented nothing but a very slight glandular hyperplasia. The muscular coat of the uterus (with the exception of the external layers mentioned above) and the myoma contained absolutely no epithelial formations. The myoma or rather myofibroma had a well-pronounced capsule and had none of the characteristics of an adenomyoma. The round ligament showed small carcinomatous nodules in and under its serous coat, but its substance was free from epithelial elements.

The carcinomatous infection of the adhesion-membranes around the uterus and its ligaments has produced quite bulky tumors, especially on the right side of the broad ligament where the tumor which is mentioned in the macroscopic description (RM. Fig. 3) and which has almost attained the size of an ovary, is a pure carcinomatous growth. The formation of adhesions with the *ovaries* has also given rise to the growth of metastatic carcinoma on the ovaries (Fig. 6). The substance of the ovaries is without a trace of carcinoma, but the surface of the ovaries is studded with carcinomatous nodules. Their metastatic nature is proven by the fact that in many instances the carcinomatous nodule and the ovarian substance are separated by a well-preserved line of germinative epithelium which is interrupted at the places where the adhesion membrane has grown to the ovary. The carcinoma is arranged in the same way as in the subserous nodules on the surface of the tubes and uterus, that is to say, in solid strings of cells following the lymphatics. Where we see a tumor originating in the germinative epithelium of the ovary the structure

of the tumor is entirely different, the epithelial neoplasm developing on the surface primarily and essentially in marked contrast to the condition prevailing in this case.

To recapitulate briefly, we have a primary papillo-carcinomatous tumor of both tubes with metastatic growths in the uterus and in the serous coats of the surrounding organs.

*Conclusions.*—It seems to me that there can be no doubt as to the tumor's origin in the tubes. The only other organ which produces such tumors and would have to be considered is the ovary, the origin in the uterus being excluded by the observation of the neither considerable nor malignant changes in the endometrium. The tumors can not have originated in the ovaries, as according to the histologic description given above the substance of the ovaries is unchanged and the nodules on the surface of the ovaries are of a purely metastatic character.

The origin of the tumors in the tubes is therefore indisputable. The description given above tallies perfectly with the descriptions of the nineteen cases contained in the literature. One observation, however, which marks this as a unique case is worthy of some further discussion, namely, the observation of two neoplasms in each tube: adenomyoma and papillo-carcinoma. Is it possible that the carcinoma originated in the epithelium of the adenomyoma and grew secondarily on the tubal mucous membrane? Or was the adenomyoma the secondary seat of the neoplasm which had originated in the tubal mucous membrane? It is interesting that thickening of the isthmic part of the tubes is mentioned in several cases of

tubal carcinoma which perhaps on closer examination might reveal the presence of adenomyomas. It is furthermore noteworthy that von Recklinghausen[4] describes cases where uterine adenomyoma coexisted with malignant adenoma of the uterus. Von Recklinghausen arrived at the conclusion that the presence of adenomyoma in the cancerous uterus was accidental and that the adenomyoma was attacked secondarily by the malignant neoplasm. I believe that we must arrive at the same conclusion with regard to the coexistence of the adenomyoma and the papillo-carcinoma of the tube. The adenomyomas of the tubes are decidedly frequent tumors even though they escaped discovery until very recently. I have in the course of the last year met with six cases of adenomyoma of the tube and the more tubes I examine carefully the more frequently I find those neoplasms. If the present case is the only case of adenomyoma in a carcinomatous tube the proportion would be one in twenty, a proportion which according my experience is much smaller than the proportion of adenomyomas in tubes generally. This latter proportion appears to be nearer the rate of one in five or ten.

There is another reason which causes me to regard the seat of the malignant tumor in the adenomyoma as secondary. The papilloma has left many of the adenomatous tubules intact and it is not likely that a malignant neoplasm which has spread over both tubes and a large peritoneal surface should have shunned reverently the rest of a small nodule from part of which it had originated. This is the more unlikely as communications of these adenomatous tubules exist which would have offered a ready path to the progress

of the neoplasm before it ever spread into the cavity of the tube. On the other hand the small slit-like communication between the cavity of the tube and the adenomatous tubules gave the carcinomatous infection, if I may use this term, ready access to the tubules. The progress of the bearer of the carcinomatous infection must have been facilitated by the fact that the occlusion of the abdominal end of the tube and the narrowness of the uterine end of the tubal cavity produced considerable pressure of the contents of the tube.

We arrive therefore at the ultimate conclusion that the carcinoma originated in the epithelium of the tubal mucosa. If now we compare the papillomatous formations in the tubes with those described above in the case of simple papilloma of the tube we can not fail to recognize the very great similarity between the two. It has been generally assumed that a benignant papilloma of the tube can undergo malignant degeneration and on the other hand that papillo-carcinoma of the tube frequently springs from a non-malignant papilloma. This appears to be quite likely, in fact the tumors are so much alike that a differential diagnosis has been found a matter of great difficulty. We encounter the same doubts here as in the cases of papilloma of the ovary, where clinical experience has led some authors to consider every papilloma malignant, at least to suspect it of malignancy. In our case of papillo-carcinoma the pathologic examination revealing the numerous solid metastases and the clinical history recording recurrence of the disease and death of the patient agree very well. But in our case of "benignant papilloma" I am by no means sure

that I may not have overlooked some true carcinomatous nest or that the operator has not failed to remove the neoplasm completely so that in spite of our present diagnosis and the patient's apparent good health there is just the shadow of the possibility of a recurrence.

There is, however, a clinical aspect of this question which is well worth consideration. If there is papilloma of the tube it is impossible without microscopic examination to differentiate between a benignant and a malignant neoplasm. If we have a malignant neoplasm of the tubes the probability of metastatic growths in the organs connected with the tubes is very great. Therefore these organs must be removed with the tubes. To recognize this it is absolutely necessary to cut the tubes open while the operation is proceeding and not to throw them aside for an examination to be made after the abdomen is closed or, as occurs too frequently, never to be made. The advice to open every tube removed was first given by Saenger [2] and I think it is very good advice.

I wish to add a little advice of my own which is suggested by a careful investigation of the postmortem reports of cases of papillo-carcinoma of the tubes which had succumbed to recurrence of the disease. Metastases were found in these cases not only in the uterus but in the retroperitoneal glands. It is perfectly feasible to remove these glands as I first proposed [6] and recently demonstrated in an operation for cancer of the cervix uteri which I performed at the Post-Graduate Hospital in the presence of my class and which the patient has stood very well. (She was discharged cured two weeks after the operation.)

These glands as well as the uterus should be removed in every case of papilloma of the tubes. The danger of recurrence can thereby be avoided in a higher degree than by the mere removal of the tubes. Let us look for instance at our case of carcinoma of the tubes. If the uterus had not contained a fibroid it would have appeared unnecessary to many operators to remove it. The consequence of leaving it would have been that all carcinomatous masses contained in the uterus as described above would have remained in the patient. It is true that the recurrence was not avoided by the removal of the uterus. But we do not always meet with such far-gone cases as this and in the cases of limited extent of the neoplasm we have to remember the old rule concerning operations for carcinoma, to remove the tissues to as large an extent around the apparent limits of the neoplasm as possible.

It remains to consider the relations of our case of papillo-carcinoma of the tubes to the other cases recorded of which Doran [1] enumerates nineteen, our case bringing the number up to twenty.

The age of the patients varies between 36 and 60, most of the patients (among them the case presented here) were about 45 years old. The patients were either sterile or had given birth to one child many years (twenty-three years in our case) before the tubal disease was noticed. According to Sænger[2] and Doran[1] the disease was on one side only in twelve cases, on both in the rest of the cases among which ours is to be rubricated. In twelve cases the tubes alone were the seat of the disease. Chronic inflammatory conditions with pus accumulation are very frequently observed.

The prognosis of the operation according to the most recent reports as given by Doran [1] is expressed in the following numbers: Death occurred shortly after operation in three cases, death from recurrence in five cases (10 months, 10 months, 18 months, 5 months, 1 year after operation). Alive with recurrence were three cases, without recurrence, five cases (7 years, 7 months, 19 months, 1 year, 3 months after operation).

The diagnosis has never been made correctly before the operation, but after once the attention of the profession has been directed to this possibility it will probably not take long before the clinical side is so well worked out that we are enabled to make a clinical diagnosis. I refrain from further discussion of the clinical side of this question as I have only made a pathologic examination of the cases reported here.

LITERATURE.

[1] A. Doran in Allbutt and Playfair's "System of Gynecology," 1896.

[2] Saenger and Barth in Martin's "Krankheiten der Eileiter," 1896.

[3] A. Doran: Trans. Lond. Path. Soc., Vol. 39, 1888, p. 208, and Vol. 40, 1889, p. 221.

[4] von Recklinghausen: Adenomyome der Uterus- und Tubenwandung, 1893.

[5] Ries: Amer. Jour. of Exper. Med. (to appear in next issue).

[6] Ries: Zeitschr. f. Geburtshülfe, Vol. 32, 1895. Chicago Medical Recorder, Nov. 1895. North American Practitioner, January, 1896.

DR. JOSEPHINE E. YOUNG read a paper on

## A CASE OF DEFECT IN THE VENTRICULAR SEPTUM AND STENOSIS OF THE PULMONARY CONUS IN A MAN THIRTY-TWO YEARS OLD, WITH DEMONSTRATION OF THE HEART.

October 2, 1896, a patient, 32 years of age, entered Cook County hospital, Chicago, with evidences of

an acute, febrile disease. He gave the following history: When 2 years old a consultation of physicians was held—the child always having been so delicate that it was necessary to carry him about on a pillow, at that time being very poorly nourished and developed, unable to walk, and having at frequent intervals attacks of marked cyanosis. The consultants told his mother that he could not live to maturity. At the age of 17, Prof. Lyman of Rush Medical College demonstrated the case in his clinic as one of cardiac disease. During his entire life, upon marked exertion or excitement, the patient had attacks of pronounced cyanosis.

Upon entrance to the hospital, physical examination revealed the following: General development and nourishment good, clubbed finger ends, color ruddy, no evidence of cyanosis at this time. The pulse was full and regular, later becoming irregular and distinctly subingual. *Heart:* percussion, relative dulness *right border* to the right of the right sternal line, *base* third rib, *left border* left mammillary line. There was increased dulness when the patient leaned forward. One month later the dulness extended two cm. to the left of the left mammillary line. Palpation: upon entrance there was distinct fremitus over the entire precordia. The apex beat was strong and regular. One month later there was marked arrhythmia. Auscultation: a very loud systolic murmur could be heard over the entire thorax, anteriorly and posteriorly, the maximum intensity being at the junction of the third rib with the left border of the sternum. The murmur was heard very distinctly along the entire left sternal border. There was no accentuation of the sec-

ond pulmonic tone. Notwithstanding the fact that for eighteen days the temperature remained at or near 103; there was never any cyanosis. The urine was negative, both as to albumin and morphologic elements. Other findings bear no especial relation to the cardiac lesions, the diagnosis of the acute disease halting between acute endocarditis and typhoid fever. Dr. James B. Herrick at this time made a diagnosis of congenital heart disease.

The patient was discharged Nov. 24, 1896, after recovery from the acute attack. Dec. 12, 1896, he reëntered the hospital with facial erysipelas.

The heart and lung findings were as before. In a few days, with a temperature of 104 degrees, cyanosis became a marked feature. The heart was very arrhythmic, the pulse correspondingly irregular and compressible. The spleen extended five cm. below the left costal arch, the liver one and one-half cm. below the right costal arch and in the mammillary line. Examination of the urine showed albumin in rather large amount and granular casts. The extremities were not edematous. Two days before death the dyspnea was extreme and respirations increased to fifty-two. The patient's critical condition and constant right decubitus prevented a thorough examination of the right lung, which later showed evidences of pneumonia. He was rational throughout.

Death occurred Jan. 12, 1897, after one month's illness, during which time the temperature was frequently 104 and 105 degrees.

The clinical diagnosis was facial erysipelas, acute splenitis, nephritis, pneumonia (?), general septic infection, and congenital heart disease. The autopsy

was made by Dr. Ludvig Hektoen, Jan. 18, 1897.

Anatomic diagnosis: healed facial erysipelas, lobar pneumonia, embolic abscess in the left lung, acute splenic tumor, chronic and acute nephritis, chronic gastritis, pigmented Peyer's patches, hypertrophy of the heart, chronic and acute endocarditis of the tricuspid and pulmonary valves and the wall of the right ventricle, stenosis of the pulmonary conus and congenital defect of the ventricular septum.

The bacteriologic examination of the organs showed staphylococci pyogenes albus and citreus to be present everywhere.

The cardiac findings more particularly are the following: The hypertrophy is rather marked; the heart weighs 400 grams; the apex is composed equally of the right and left ventricles; the wall of the right auricle measures 4 mm. in the thickest part, that of the left auricle 3 mm.; the wall of the right ventricle averages 1 cm. in thickness, that of the left ventricle 1½ cm.; the circumference of the aorta at the valvus is 5.7 cm., that of the pulmonary artery is 5.4 c.m.; the ductus Botalli is closed; the arrangement of the pulmonary artery is normal, that of the aorta, which communicates only with the left ventricle, is normal also. Four cm. below the upper margin of the pulmonic semi-lunar valves there is a stenosis of the pulmonary conus, due to fibrous tissue. The lumen of the conus measures 1 cm. in its largest diameter; the foramen ovale is patent, admitting a lead pencil through its orifice; a sickle-shaped valve covers it. Directly below the semi-lunar valves of the aorta there is a defect in the ventricular septum which measures 2.6 cm. in the horizontal diameter, 2 cm.

in the vertical diameter. This defect corresponds to the septum membranacum, or undefended space, the last part of the ventricular septum to close, composed normally of a thin layer of fibrous tissue covered with endothelium. The pulmonary valves are thickened; the free margins of the posterior segment are covered by large polypoid vegetations. These spring also from the ventricular surfaces of the valves and from the wall of the pulmonary artery. The free margins of the tricuspid valves are thickened. Here then are distinct polypoid vegetations. The orifice admits four finger-tips easily; the right auricular appendix shows some irregular masses; the aorta valves are free from thickening; the aorta shows no atheroma; the mitral valve is normal, admitting four finger-tips snugly; the myocardium, except at the stenosis of the conus, is normal. Microscopically, the striæ and nuclei of the fibers are normal, but there is a general segmentation.

The clinical diagnosis of congenital heart disease was based upon the history, the cyanosis, hypertrophy of the right heart, position of the systolic murmur and thrill at the junction of the left third rib with the sternum, the intensity and widespread transmission of the thrill and the weak second pulmonic tone.

As to the formation of the lesions, Fraentzel, Bamberger and Oppolzer support the Hunter-Morgagni theory, a myo- or endo- carditis occurring before the eighth week of fetal life is the cause of the stenosis of the pulmonary artery or its conus. This greatly increases blood pressure by preventing the proper escape of the blood from the right ventricle, the blood necessarily forcing its way into the left ventricle through the undeveloped septum. If the opening in

the septum is sufficiently large blood pressure in the right heart is compensated for—there may be no opening (in the septum) of the foramen ovale. If not large enough there will be hypertrophy and dilatation of the right ventricle, stasis in the right auricle, with passage of blood through the foramen ovale, which remains patent.

The case is of interest not so much from its rarity as from the following points: The patient had reached the age of 32, was a strong, well-developed man doing the ordinarily heavy work of a laborer, had passed through an acute febrile attack of eighteen days' duration without any evidence of cyanosis, had resisted for a month profound erysipelatous and septic infection and had entirely escaped pulmonary tuberculosis, a condition frequent in these cases, owing to the diminished supply of blood sent to the lungs.

# INDEX OF SUBJECTS.


PAGE

Actinomyces-like bodies in tonsils . . . . . 290
Adenocarcinoma of colon . . . . . 56
Amnionitis, extensive . . . . . 21
Anencephalus et Acrania . . . . . 188
Appendix, vermiform, cyst of . . . . . 99
    vermiform, with fecan stone . . . . . 72
Artefacts in examination of the nervous system . . . . . 176
Ascites, chylous . . . . . 105
Bile-duct, common, causes of obstruction of . . . . . 191
Brain, mixed celled sarcoma of pons, and crus . . . . . 258
    glioma of cerebrum . . . . . 259
    sarcoma of cerebrum springing from Dura . . . . . 260
    syphilis of cerebrum . . . . . 111
    myxosarcoma of cerebellum . . . . . 144
Carcinoma of labia majora, metastasis from . . . . . 28
    of stomach . . . . . 201
    of cervix uteri . . . . . 218
    primary, of ureter . . . . . 132
    colloid, of stomach . . . . . 58
Cholesteatoma of ear, three cases of . . . . . 96
Colon, adenocarcinoma of . . . . . 56
Conjunctivitis, diphtheritic, caused by the streptococcus pyogenes . 295
Craniorbachischisis . . . . . 21
Ectopic pregnancy . . . . . 55, 147, 278
    pregnancy complicating typhoid fever . . . . . 71
Enterolith, causing intestinal obstruction . . . . . 30
Fallopian tube, primary papilloma and primary carcinoma of . . . . 300
Fibroma of uterus . . . . . 72
    of scrotum . . . . . 97
    of vaginal wall . . . . . 18
    of uterus, complicating pregnancy . . . . . 20
Fibromyoma of stomach . . . . . 56
    of uterus, complicating pregnancy . . . . . 9
Formalin and Müller's fluid as hardening agents . . . . . 54
Gall-bladder, mesentery for . . . . . 277
Giant-cells, histogenesis of . . . . . 29
    fate of, in healing tuberculosis . . . . . 283
Glioma of left temporo-sphenoidal and occipital lobes . . . . . 259
Glycerine as a bactericide . . . . . 165
Goitre, exophthalmic . . . . . 66
Gumma of hypophysis cerebri . . . . . 129
    of myocardium . . . . . 249
    of heart in congenital syphilis . . . . . 250

Heart, aneurysm of right auricular appendix . . . . . 278
relative insufficiency of pulmonary valves . . . . . 261
mitral and tricuspid stenosis . . . . . 202
tricuspid stenosis . . . . . 181
tricuspid regurgitation . . . . . 189
gumma of . . . . . 249
gummata of, in congenital syphilis . . . . . 250
pulmonary stenosis . . . . . 59
defect in ventricular septum . . . . . 319
tuberculous pericarditis . . . . . 55
Hip-joint, spontaneous dislocation . . . . . 67
Hypophysis, gumma of . . . . . 129
Ileum, benign cicatricial stricture of . . . . . 292
Intestine, obstruction from enterolith . . . . . 30
Iniencephalus . . . . . 204
Ischiopagus, monomphalic . . . . . 148
Kidney, calculus imbedded in the substance of . . . . . 277
Liver, cirrhosis of, with pre-ascitic edema of lower extremities. . . . 101
sarcoma, spindle-celled . . . . . 137
sarcoma, diffuse, infiltrating, melanotic . . . . . 138
sarcoma, large round-celled . . . . . 141
icteric necrosis, etc . . . . . 280
Lipoma in tendon of semitendinosus muscle . . . . . 163
Malaria, two cases of pernicious . . . . . 73
Malignant growths, remarks on . . . . . 220
Mitral and tricuspid stenosis . . . . . 202
Mesentery, solid tumor of . . . . . 271
Monster, anencephalic . . . . . 21
hypoplastic . . . . . 26
kynocephalous . . . . . 24
Myxosarcoma of cerebellum . . . . . 144
Necrosis, focal, produced by the bacillus of tuberculosis . . . . . 273
Pancreas, primary sarcoma of tail . . . . . 157
Pancreatitis, suppurative . . . . . 216
with disseminated fat necrosis . . . . . 57
Pulmonary stenosis . . . . . 59
valves, relative insufficiency . . . . . 261
Pyosalpinx . . . . . 70
Sarcoma of liver, spindle-celled . . . . . 137
of liver, primary, large round-celled . . . . . 141
of liver, diffuse, melanotic . . . . . 138
primary, of tail of pancreas . . . . . 157
of brain, springing from dura . . . . . 260
of pons and crus . . . . . 258
Scleroderma, diffuse . . . . . 286
Scrotum, fibroma of . . . . . 97
Stomach, colloid carcinoma of . . . . . 58
fibromyoma of . . . . . 56
carcinoma with extensive growth in veins about . . . . . 201
Struma gelatinosa and colloides . . . . . 62

Syphilis, cerebral . . . . . 111
congenital, with mixed infection by pus microbes . . . . . 240
gumma of hypophysis cerebri. . . . . 129
gumma of myocardium . . . . . 249
gummata of heart in congenital . . . . . 250
Tumors; adenocarcinoma of colon . . . . . 56
carcinoma of stomach, colloid . . . . . 58
carcinoma of stomach, colloid, with extensive growth into veins . . . . . 201
carcinoma of cervix uteri . . . . . 218
carcinoma of ureter, primary . . . . . 132
carcinoma of Fallopian tube, primary . . . . . 300
carcinoma of labia majora . . . . . 28
fibroma, of stomach . . . . . 56
fibroma, of scrotum . . . . . 97
fibroma, of uterus . . . . . 72
fibroma, of uterus, complicating pregnancy . . . . . 9, 20
glioma of brain . . . . . 259
lipoma developed in tendon of semitendinosus muscle . . . . . 168
malignant, remarks on . . . . . 220
myxosarcoma of cerebellum . . . . . 144
papilloma, of Fallopian tube, primary . . . . . 300
of mesentery, solid . . . . . 271
of brain hardened in Müller's fluid and formalin . . . . . 257
sarcoma, of liver, spindle-celled . . . . . 137
sarcoma, diffuse, melanotic . . . . . 138
sarcoma, primary, large round-celled . . . . . 141
sarcoma of pons and crus . . . . . 258
sarcoma, of brain, springing from dura. . . . . 260
sarcoma, primary, from tail of pancreas. . . . . 157
Tonsils, actinomycoses-like bodies in. . . . . 290
Tricuspid stenosis . . . . . 181
and mitral stenosis. . . . . 202
regurgitation. . . . . 189
Tuberculosis, bovine. . . . . 89
focal, necrosis in . . . . . 273
of pericardum. . . . . 55
healing; fate of giant cells in . . . . . 283
Typhoid bacilli, action of human serum on . . . . . 196
Uterus, with fibroma of . . . . . 72
carcinoma of cervix . . . . . 218
membrane discharged from . . . . . 33
Ureter, primary carcinoma of. . . . . 132
Urethra, stricture of, with extravasation of urine . . . . . 217
Urachus, cyst of. . . . . 215
Uterus, fibromyoma complicating pregnancy. . . . . 9
fibroma complicating pregnancy . . . . . 20
Vagina, fibroma of. . . . . 18
Vaccine, bacteriologic contamination, and preservation of . . . . . 165